THE UNIVERSITY of TENNESSEE
HEALTH SCIENCE CENTER

Neurosonology Role for Patients with Acute Ischemic Stroke

Andrei V. Alexandrov, MD
Semmes-Murphey Professor and Chairman
Department of Neurology
The University of Tennessee Health Science Center
Memphis, TN

Disclosures

Funding: Cerevast Therapeutics, Inc.
Speaker's Bureau: Genentech, Inc
Editorial Board
    Cerebrovasc Dis, Intl J Stroke
Director, Neurosonology Examination 1998-2018
    American Society of Neuroimaging
Former Board Member
    ICAVL, ASN
Inventor, US Patent # 6733450
President-Elect, ASN

1998

TJC Requirements and Brain Attack Coalition Guidelines for Comprehensive Centers:

- Key Personnel –
  - Neurologists
  - Neurosurgeons
  - Vascular Surgeons
  - Intensivists (Neuro-Critical Care Specialists)
  - Advanced Practice Nurses (Masters or Doctoral degree)
  - Endovascular Specialists
  - Ultrasound Technicians
  - Physical Medicine/Rehabilitation Physicians & Therapists
- Endovascular Treatment –
  - Angioplasty/Stents
  - Coil embolization
  - Intra-arterial lytic and mechanical clot retrieval/disruption
- Expanded Neuroradiology Capabilities –
  - MRI/MRA/DWI
  - CT Angiography
  - Digital Angiography
  - Echocardiography (TTE/TEE)
  - Carotid and Transcranial Doppler
- Stroke Unit & ICU
- Rehabilitation Program
- Formal Patient and Staff Education
- Stroke Registry with Outcomes/Process Tracking

Evaluation of a Stroke Patient

H&P | Head CT | ECG, blood work-up

↓

TCD, CDUS, CTA, MRA

↓

Invasive Angiography

CLOTBUST: Find Thrombus Fast

NIHSS is sensitive to clot presence (≥10 points)

- Portable TCD and duplex
- Fast track protocol
- Use full power
- High PRF, gate ≥ 10 mm
- Occlusion(s) location
- The worst residual flow
- Monitoring set

Carotid US + TCD: Lesions Amenable to Intervention

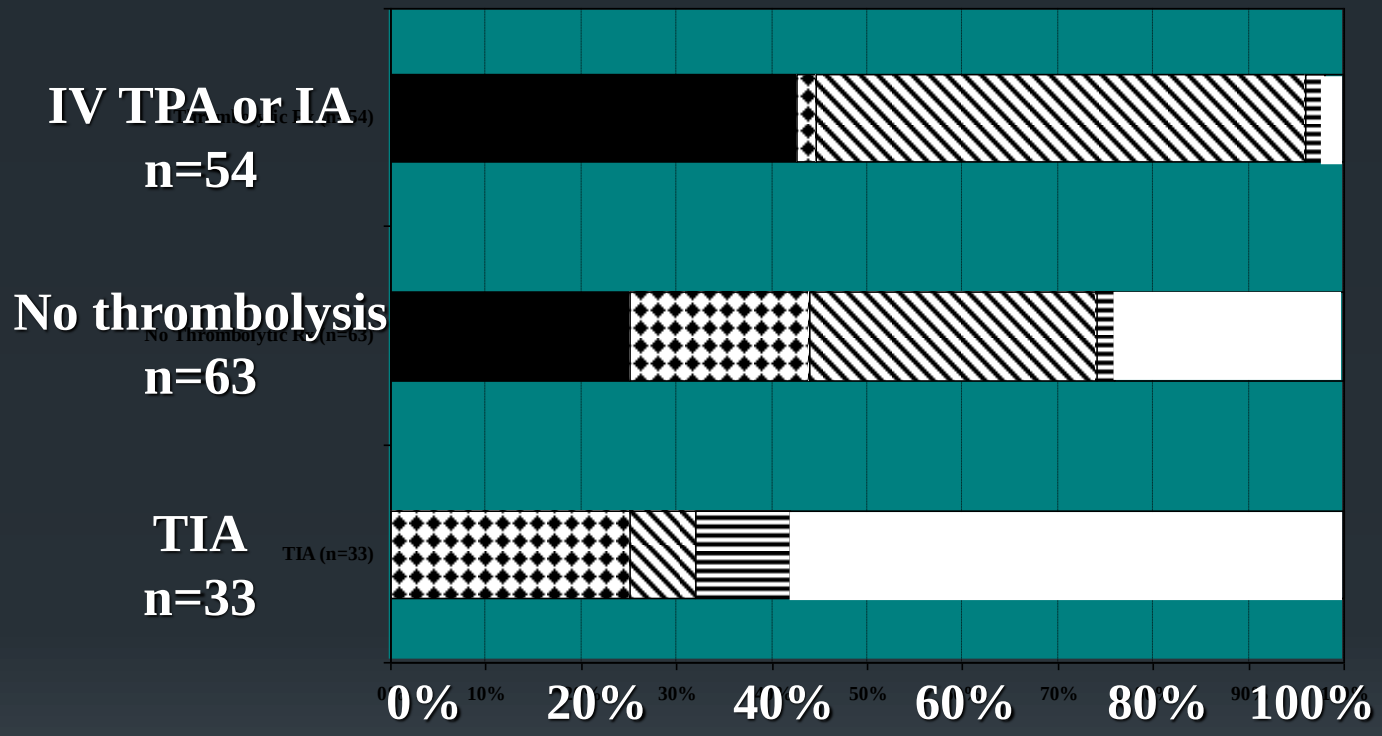

- TANDEM (ICA+MCA) obstructions
- ICA obstruction
- MCA obstruction
- BA or VA obstruction
- Normal study

Neurovascular US exam yields excellent agreement with urgent DSA

Chernyshev et al. Stroke 2005:36:32-37.

Acute vs Chronic

Carotid Occlusion: Acute or Chronic

- Acute: normal vessel diameter, preserved intima-media complex, some distensibility
- Chronic: fibrosis, vessel collapse, lack of vessel wall pulsations

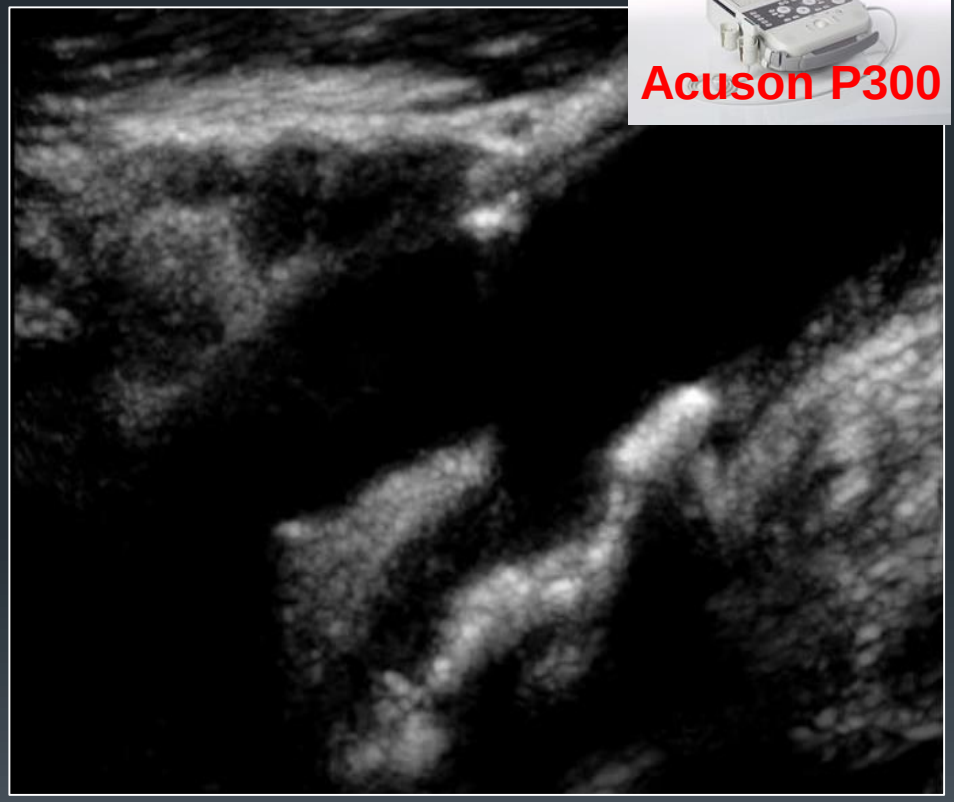

Cerbrovascular Ultrasound in Stroke Prevention and Treatment (2nd Ed)
Oxford: Wiley-Blackwell Publishers. 2011. ISBN 9781405195768

Normal MCA and MCA/ACA Waveforms

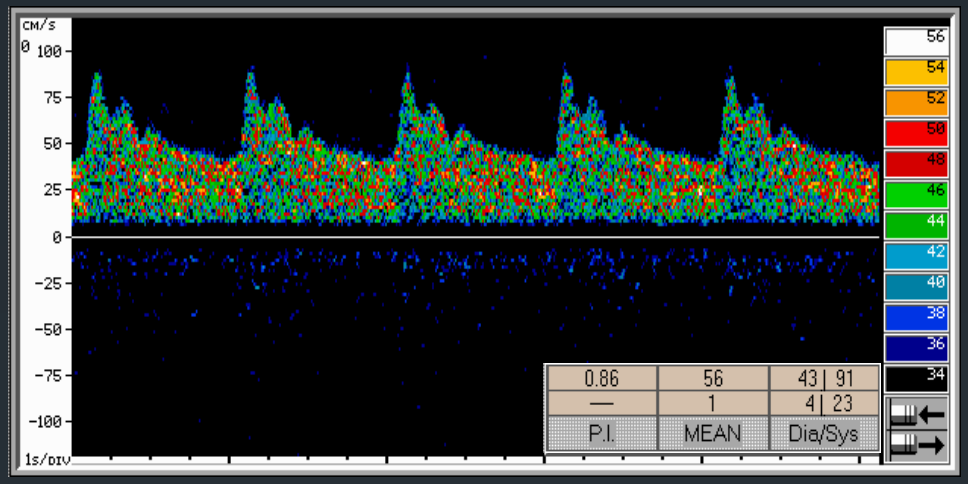

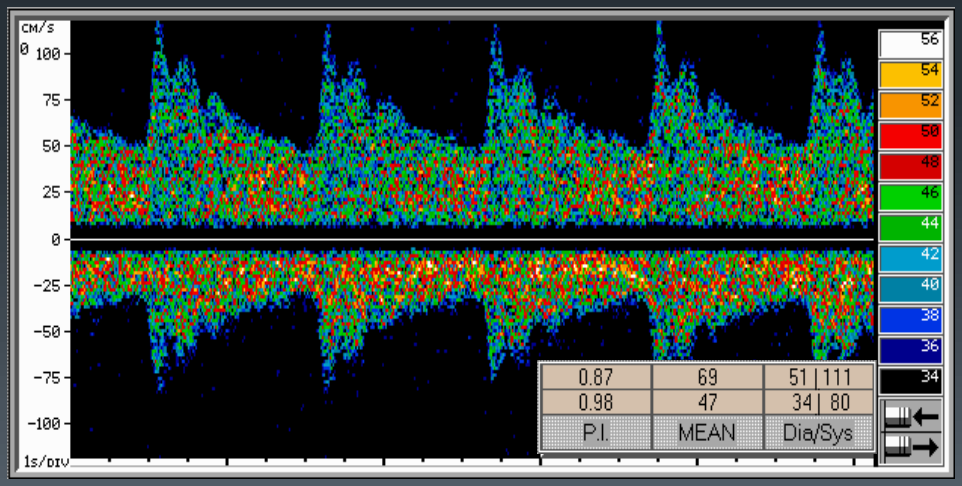

Normal MCA and ACA Waveforms with Severe ICA Stenosis

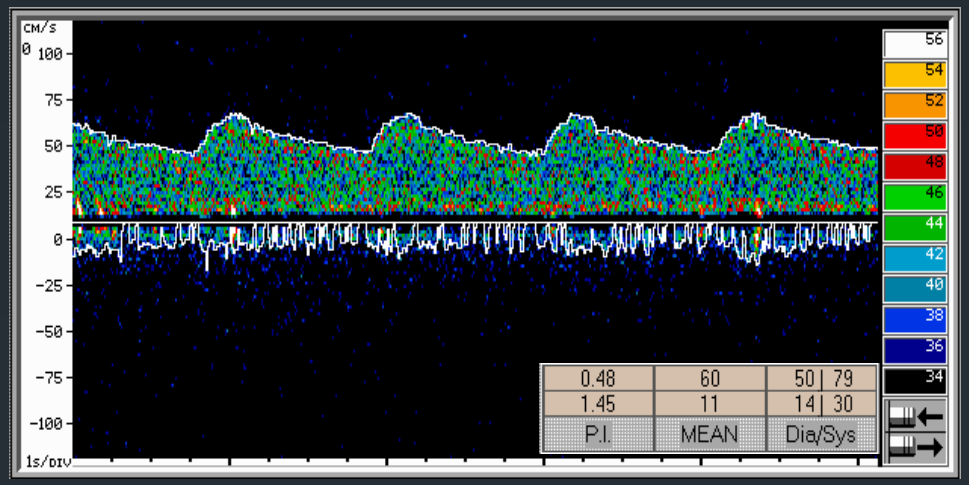

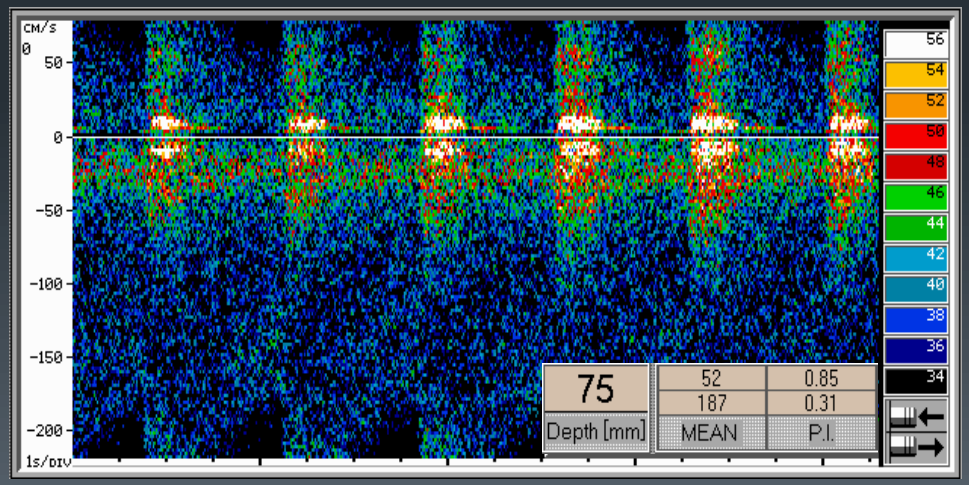

TCD and CTA in Acute Ischemia

Validation of Transcranial Doppler With Computed Tomography Angiography in Acute Cerebral Ischemia

Georgios Tsivgoulis, MD, RVT; Vijay K. Sharma, MD, RVT; Annabelle Y. Lao, MD; Marc D. Malkoff, MD; Andrei V. Alexandrov, MD, RVT

Background and Purpose—Both transcranial Doppler (TCD) and spiral computed tomography angiography (CTA) are used for noninvasive vascular assessment tools in acute stroke. We aimed to evaluate the diagnostic accuracy of TCD against CTA in patients with acute cerebral ischemia.

Methods—Consecutive patients presenting to the Emergency Department with symptoms of acute (<24 hours) cerebral ischemia underwent emergent high-resolution brain CTA with a multidetector helical scanner. TCD was performed at bedside with a standardized, fast-track insonation protocol before or shortly (<2 hours) after completion of the CTA. Previously published diagnostic criteria were prospectively applied for TCD interpretation independent of angiographic findings.

Results—A total of 132 patients (74 men, mean±SD age 63±15 years) underwent emergent neurovascular assessment with brain CTA and TCD. Compared with CTA, TCD showed 34 true-positive, 9 false-negative, 5 false-positive, and 84 true-negative studies (sensitivity 79.1%, specificity 94.3%, positive predictive value 87.2%, negative predictive value 90.3%, and accuracy 89.4%). In 9 cases (7%), TCD showed findings complementary to the CTA (real-time embolization, collateralization of flow with extracranial internal carotid artery disease, alternating flow signals indicative of steal phenomenon).

Conclusions—Bedside TCD examination yields satisfactory agreement with urgent brain CTA in the evaluation of patients with acute cerebral ischemia. TCD can provide real-time flow findings that are complementary to information provided by CTA. (***Stroke*. 2007;38:1245-1249.**)

PMD-TCD – CTA Depth Ranges

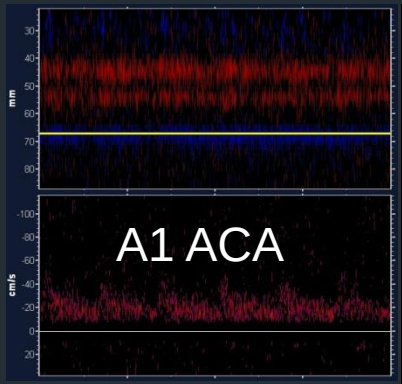

64 – 70mm

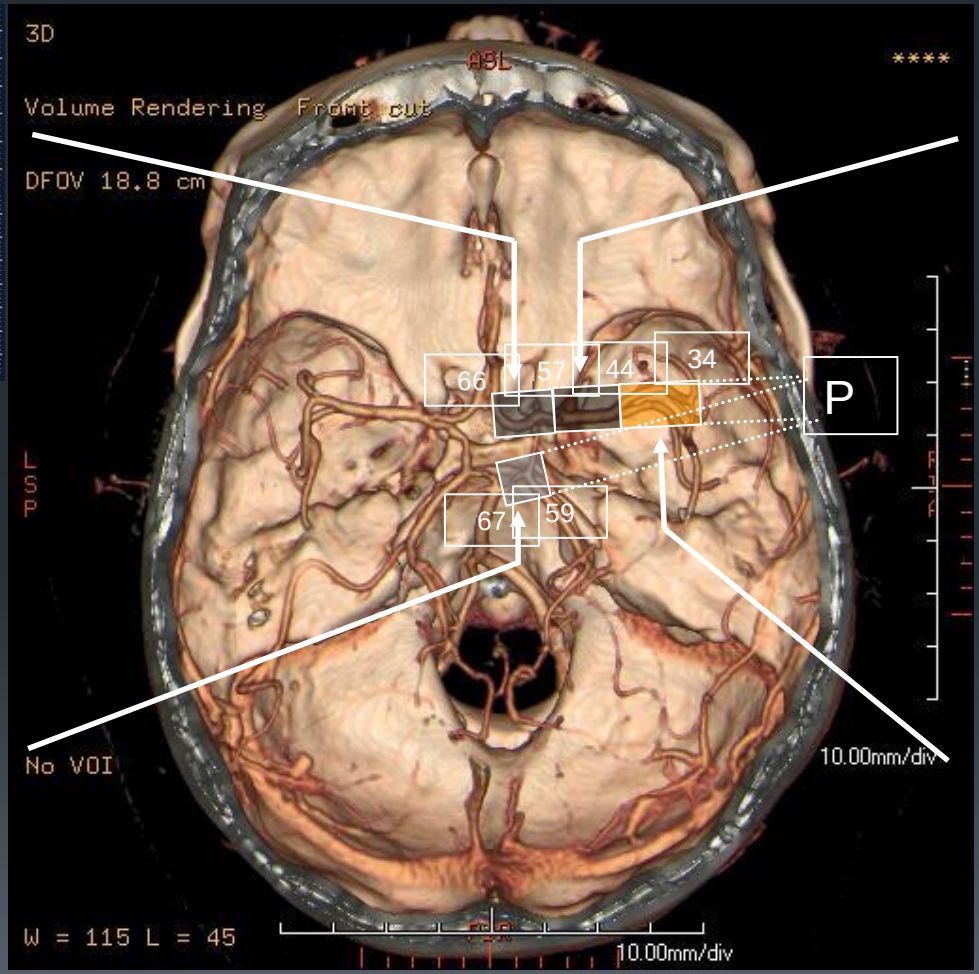

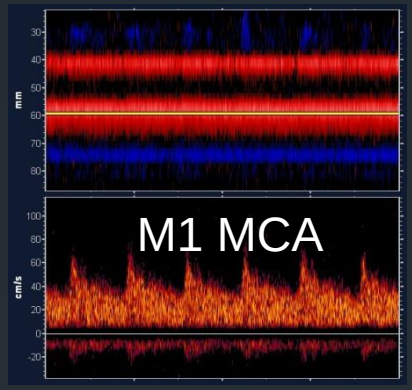

40 – 56mm

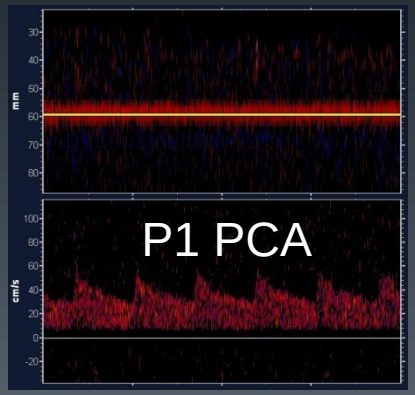

54 – 64mm

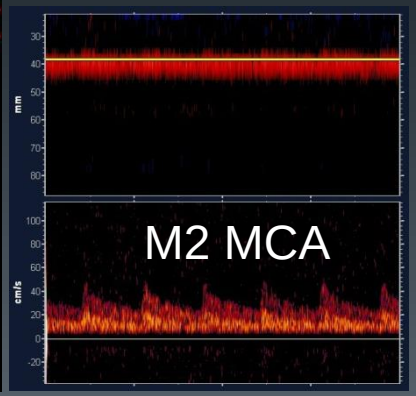

36-46mm

PMD-TCD – CTA Depth Ranges

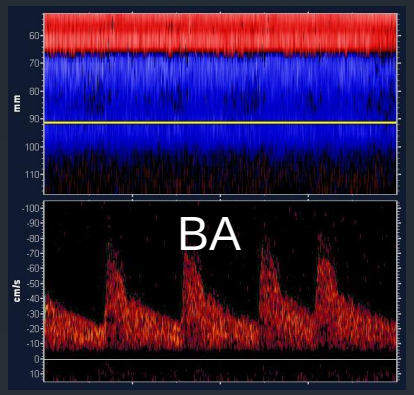

78 - 102mm

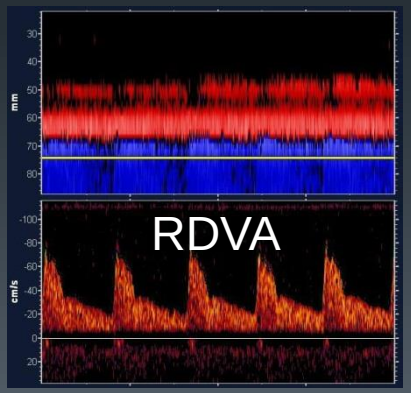

78mm

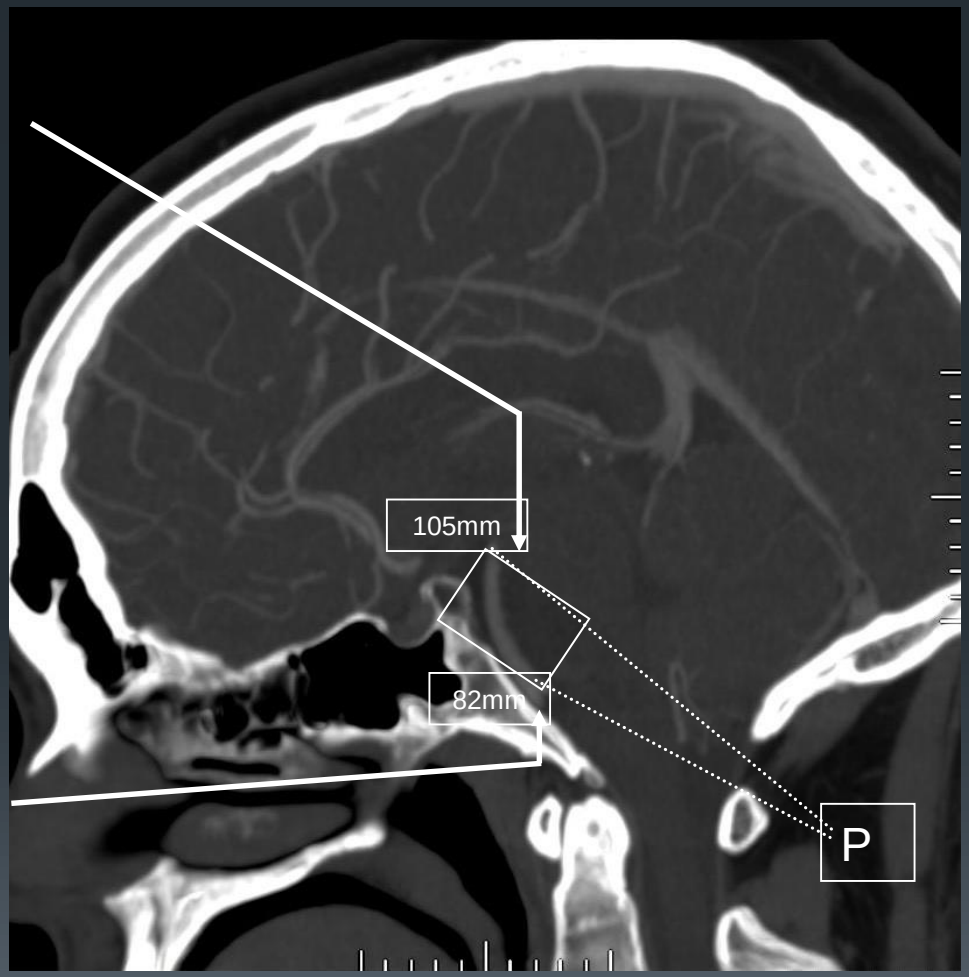

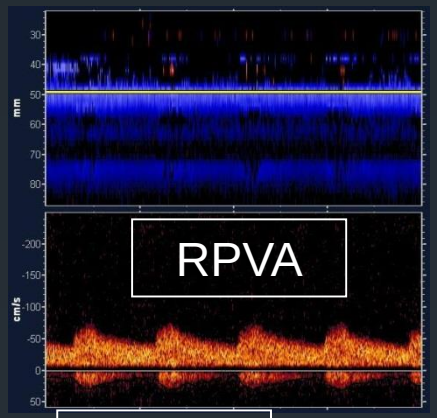

46mm

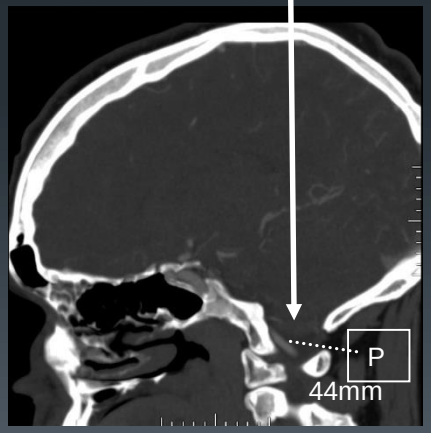

TCD and CTA in Acute Ischemia

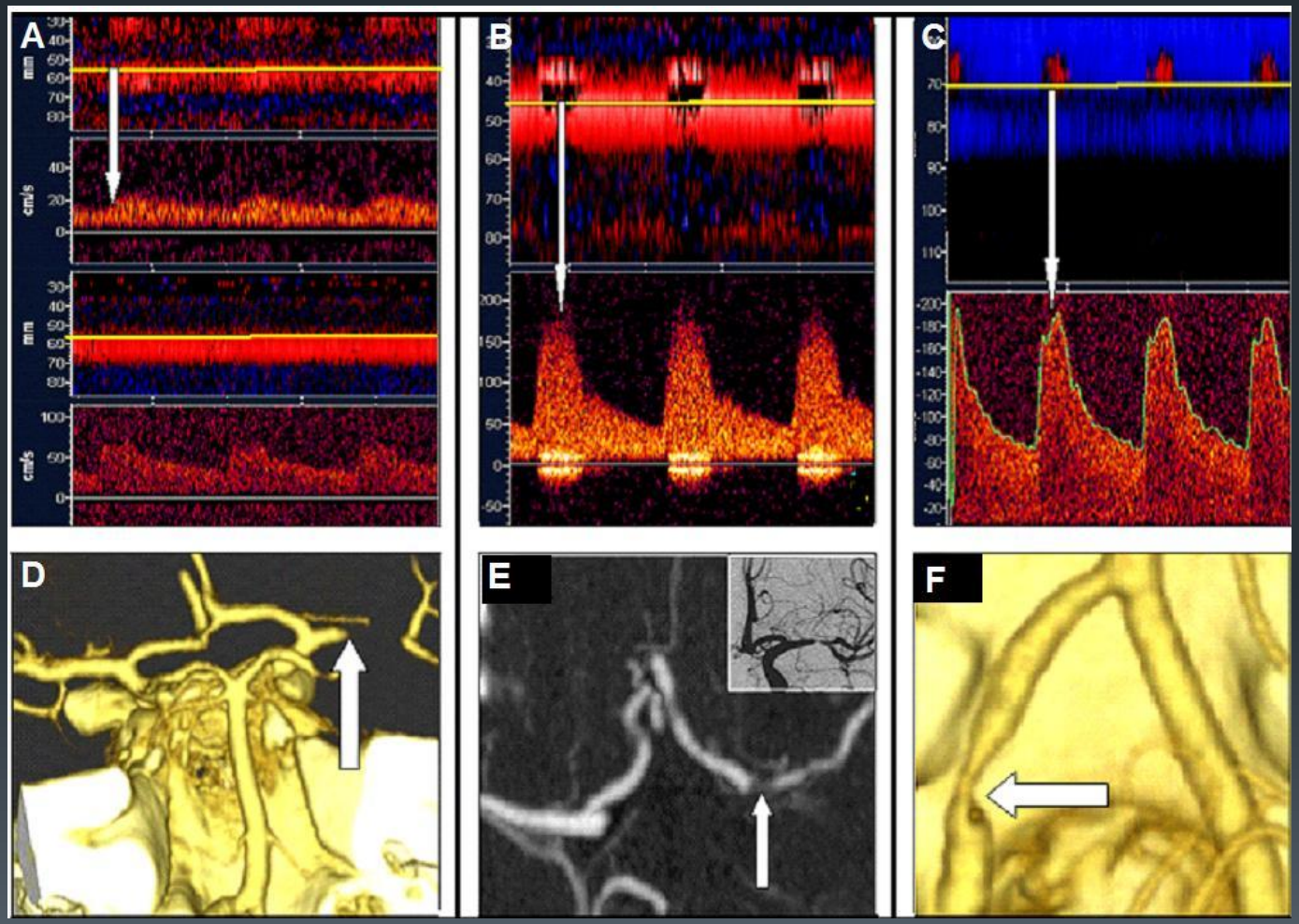

Tsivgoulis G. et al. Stroke 2007:38:1245-1249.

PMD in Acute Posterior Ischemia

Applications and Advantages of Power Motion-Mode Doppler in Acute Posterior Circulation Cerebral Ischemia

Georgios Tsivgoulis, MD, RVT; Vijay K. Sharma, MD, RVT; Steven L. Hoover, MD;
Annabelle Y. Lao, MD; Agnieszka A. Ardelt, MD, PhD;
Marc D. Malkoff, MD; Andrei V. Alexandrov, MD, RVT

Background and Purpose—Evaluation of posterior circulation with single-gate transcranial Doppler (TCD) is technically challenging and yields lower accuracy parameters in comparison to anterior circulation vessels. Transcranial power motion-mode Doppler (PMD-TCD), in addition to spectral information, simultaneously displays in real-time flow signal intensity and direction over 6 cm of intracranial space. We aimed to evaluate the diagnostic accuracy of PMD-TCD against angiography in detection of acute posterior circulation stenoocclusive disease.

Methods—Consecutive patients presenting to the emergency room with symptoms of acute (<24 hours) cerebral ischemia underwent emergent neurovascular evaluation with PMD-TCD and angiography (computed tomographic angiography, magnetic resonance angiography, or digital subtraction angiography). Previously published diagnostic criteria were prospectively applied for PMD-TCD interpretation independent of angiographic findings.

Results—A total of 213 patients (119 men; mean age 65±16 years; ischemic stroke 71%, transient ischemic attack 29%) underwent emergent neurovascular assessment. Compared with angiography, PMD-TCD showed 17 true-positive, 8 false-negative, 6 false-positive, and 182 true-negative studies in posterior circulation vessels (sensitivity 73% [55% to 91%], specificity 96% [93% to 99%], positive predictive value 68% [50% to 86%], negative predictive value 95% [92% to 98%], accuracy 93% [90% to 96%]). In 14 patients (82% of true-positive cases), PMD display showed diagnostic flow signatures complementary to the information provided by the spectral display: reverberating or alternating flow, distal basilar artery flow reversal, high-resistance flow, emboli tracks and, bruit flow signatures.

Conclusions—PMD-TCD yields a satisfactory agreement with urgent brain angiography in the evaluation of patients with acute posterior circulation cerebral ischemia. PMD display can depict flow signatures that are complimentary to and can increase confidence in standard single-gate TCD spectral findings. (***Stroke*. 2008;39:1197-1204.**)

PMD in Acute Posterior Ischemia

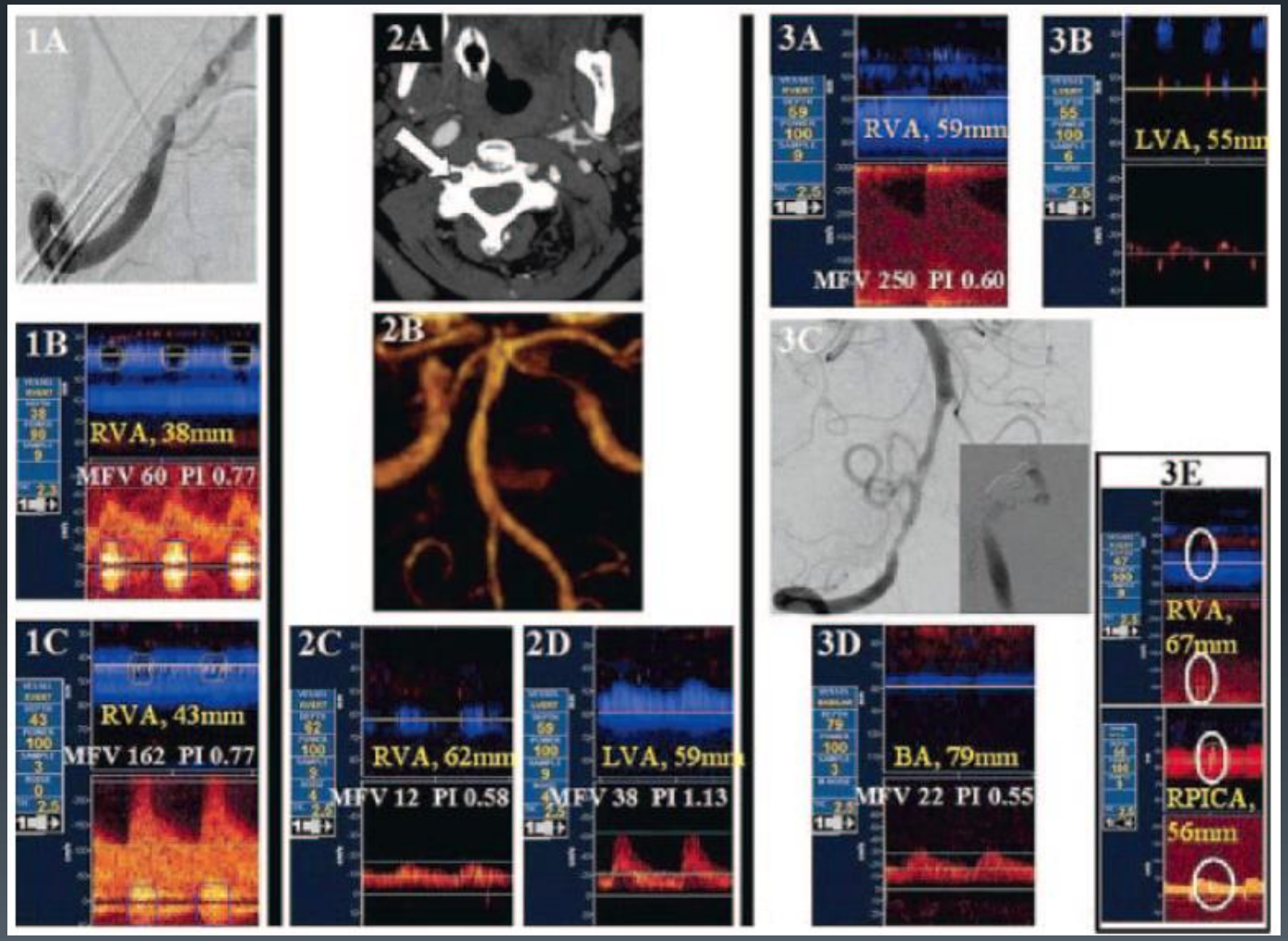

Tsivgoulis G. et al. Stroke 2008:39:1197-1204.

TCD&CDUS via Telemedicine

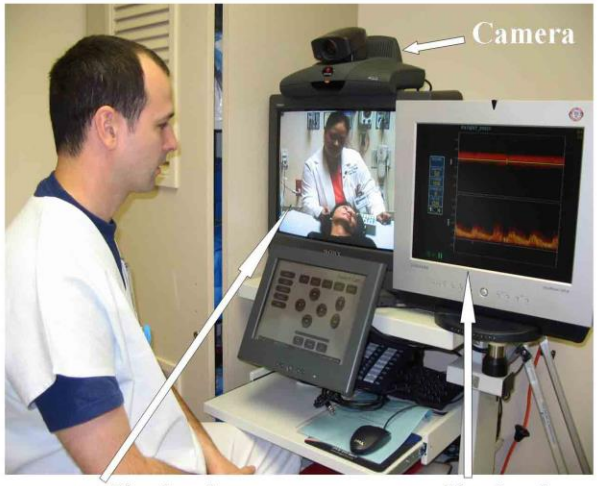

screen displaying patient examination

screen displaying ultrasound output

A Phonoscope Health Network® connection between two Polycom® Viewstation FX units

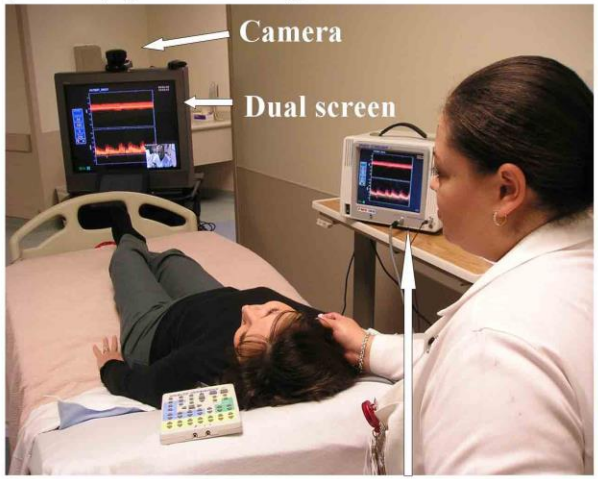

ultrasound machine (TCD)

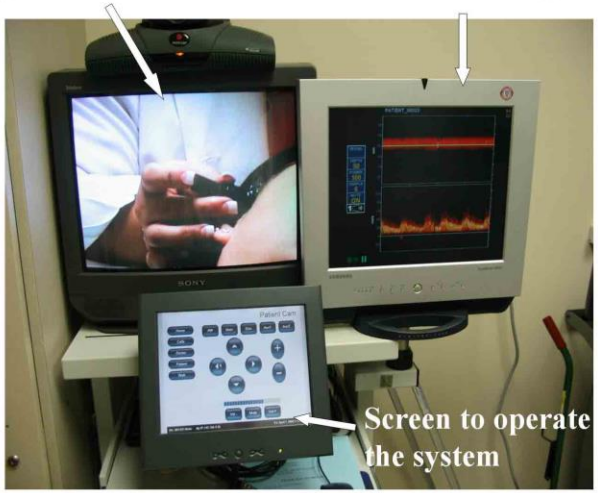

Two video screens, 800 x 600 pixel resolution for two-way, two-image communication

Mikulik R, et al. Stroke 2006;37:229-230.

Evaluation of a Stroke Patient

H&P | Head CT | ECG, blood work-up

↓

CTA

↓

Invasive Angiography

Good or Bad Collaterals?

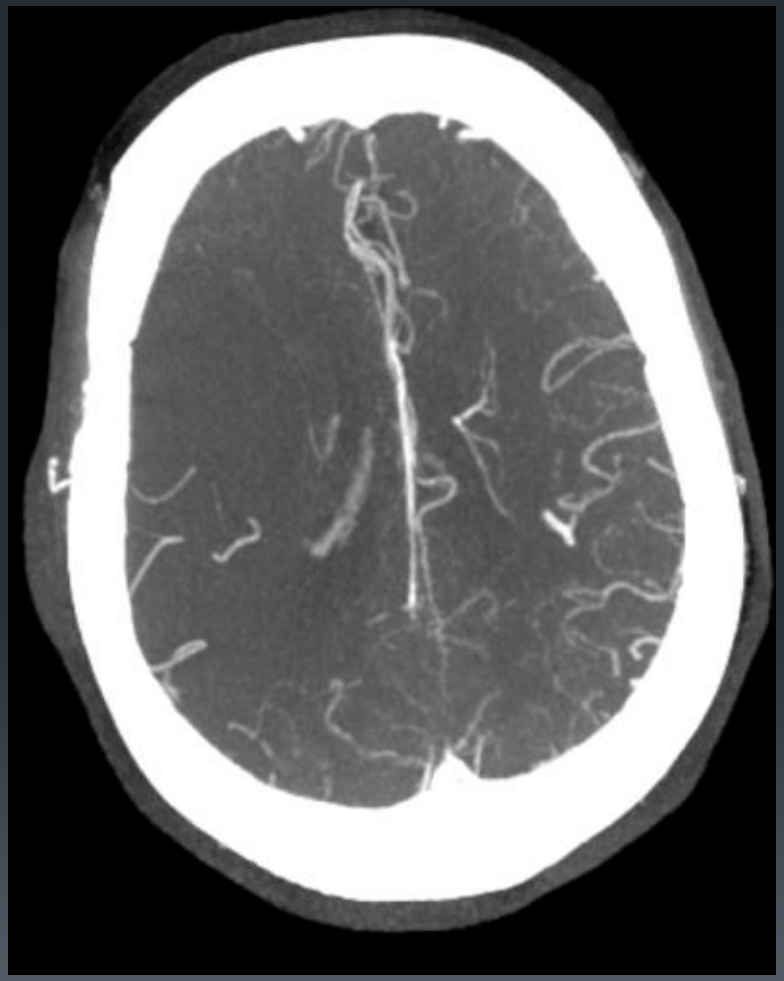

Multiphase CTA

- Refine CTA
- 3 phases
- One injection
- Relatively easy to standardize and train
- Minimal post processing time

mgoyal@ucalgary.ca

Multiphase CTA

Collateral Scoring on mCTA

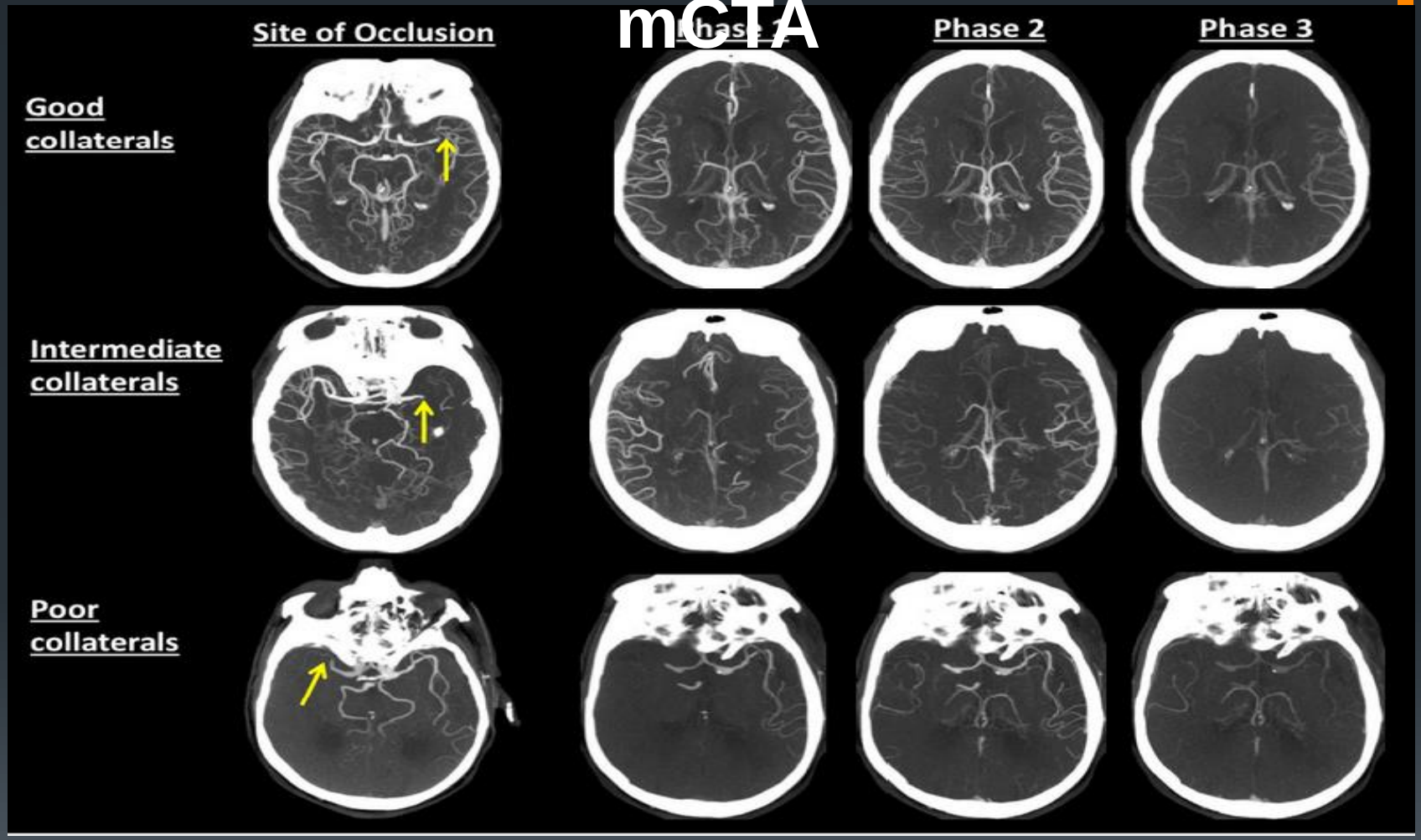

Figure. Upper panel shows a patient with a left M1 MCA occlusion (arrow) and good collaterals (backfilling arteries) on multi-phase CTA. Middle Panel shows a patient with a left M1 MCA occlusion (arrow) and intermediate collaterals. Lower panel shows a patient with a right M1 MCA occlsion (arrow) and poor collaterals (minimal backfilling arteries) on multi-phase CTA.

Collaterals in Stroke Research

18 Meyer JS, Denny-Brown D: The cerebral collateral circulation. I. Factors influencing collateral blood flow. Neurology 1957;7:447–458.

Flow Diversion in Transcranial Doppler Ultrasound Is Associated with Better Improvement in Patients with Acute Middle Cerebral Artery Occlusion

Yo Sik Kim[a] John Stirling Meyer[b] Zsolt Garami[c] Carlos A. Molina[e] Aleksandra M. Pavlovic[f, g] Andrei V. Alexandrov[d]

Cerebrovascular Dis 2006;21:74-78.

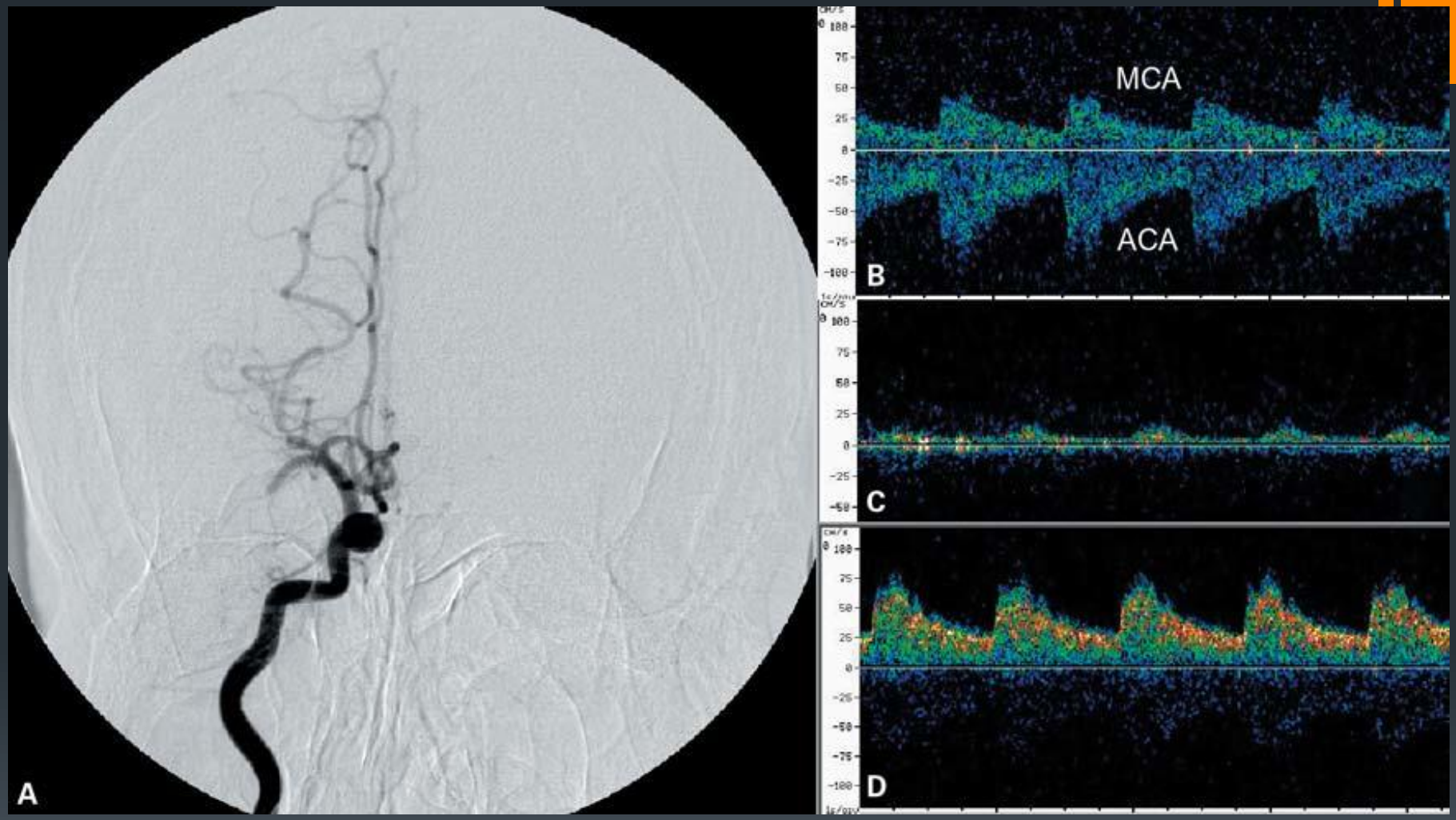

Cerebrovascular Dis 2006;21:74-78.

TCD Monitors the Residual Flow Signals

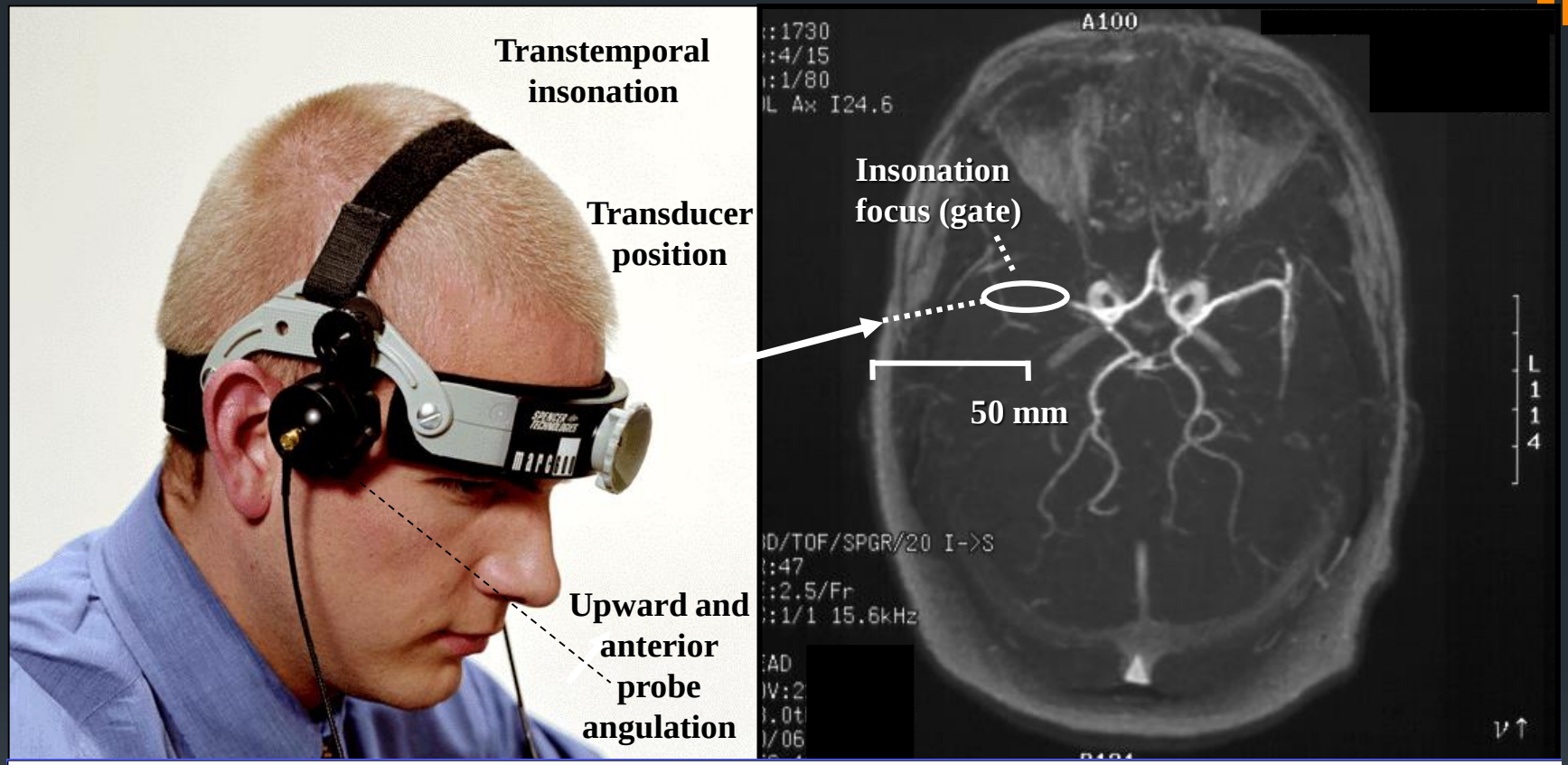

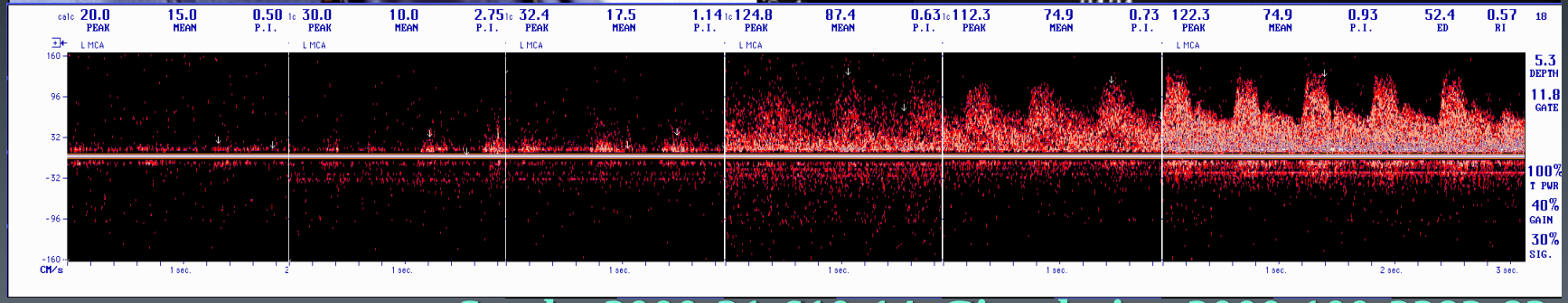

Stroke 2000;31:610-14. Circulation 2000;100:2282-83.

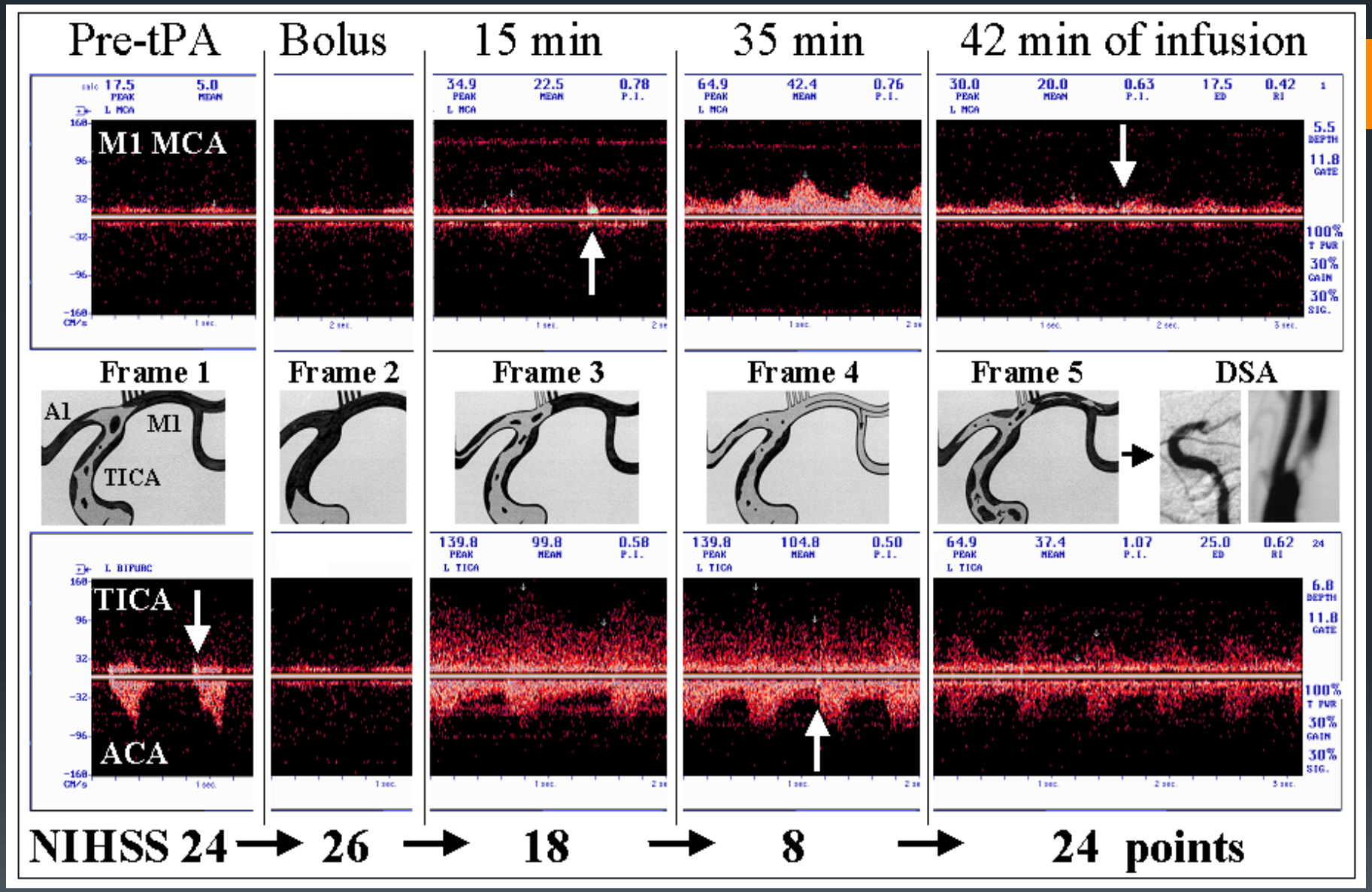

Neurology 2001;56:568-570.

CME **Arterial reocclusion in stroke patients treated with intravenous tissue plasminogen activator**

Andrei V. Alexandrov, MD; and James C. Grotta, MD

-Reocclusion occurs in up to 27% of TPA treated patients with MCA occlusions

-Reocclusion accounts for 2/3 of early clinical deterioration following improvement

NEUROLOGY 2002;59:862–867

Case illustration

- 60 y.o. AA man
- NIHSS 17
- ASPECTS 9
- iv tPA at 3 hrs
- CTA persisting

LMCAO after transfer

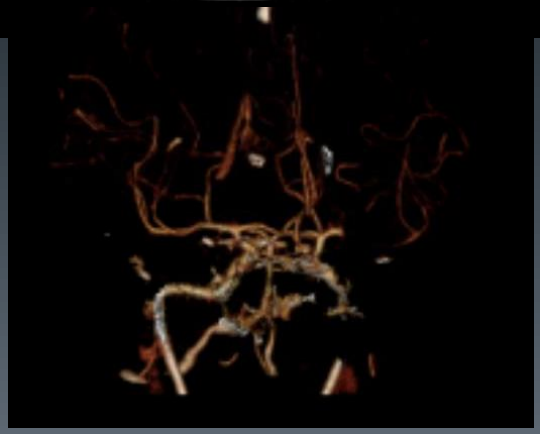

Images courtesy of Dr Nitin Goyal

Case illustration

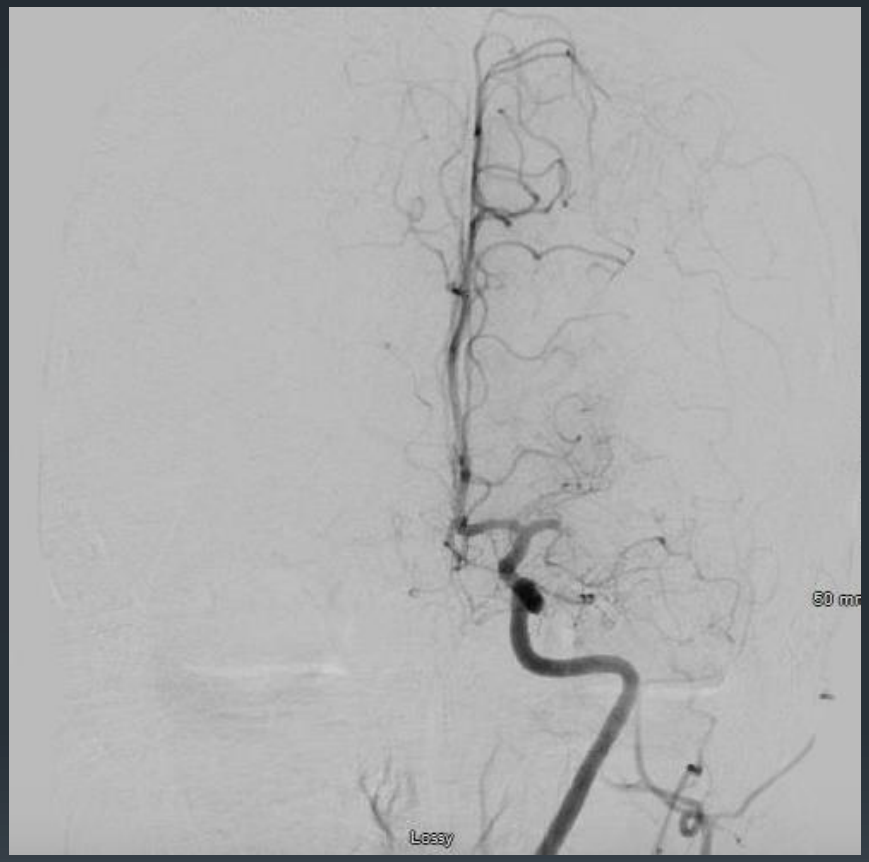

- Symptom onset to TICI 3 246 min

Images courtesy of Dr Nitin Goyal

Case illustration

- 3 month mRS 4

- Post MT SBP 170s-180s up to 8 hrs; decreasing LOC

Images courtesy of Dr Nitin Goyal

Knowns from bp mgmt for iv tPa

- BP goals before bolus below<185/110 mm Hg and <180/105 for 24 hrs post treatment were set by NINDS-rt-PA Stroke Study. Violations increase sICH risk OR 2.59; 95% CI, 1.07 to 6.25; P=0.034
- Pre-bolus SBP inversely associated with recanalization: OR per 10-mm Hg increase 0.85; 95% CI: 0.74 to 0.98, P=0.022

vgoulis G, et al. Stroke 2009;40:3631-3634. TUCSON Trial. Ann Neurol 2009;66:28-38.
Tsivgoulis G, et al. Stroke 2007;38:961-966.

Original Contribution

Baseline Blood Pressure Effect on the Benefit and Safety of Intra-Arterial Treatment in MR CLEAN (Multicenter Randomized Clinical Trial of Endovascular Treatment of Acute Ischemic Stroke in the Netherlands)

Maxim J.H.L. M F. Lingsma, PhD;
Olvert A. Berkher ebbie Beumer, MD;
Lucie A. van den Berg, M Bart J. Emmer, MD, PhD;
H. Bart va , MD, PhD;
Yvo B.W.E.M igge, MD, PhD;
Wim H. va e, MD, PhD;
Aad van der Lugt, MD, P he Multicenter Randomized
Clinical Trial of Endovascul he Netherlands (MR CLEAN)

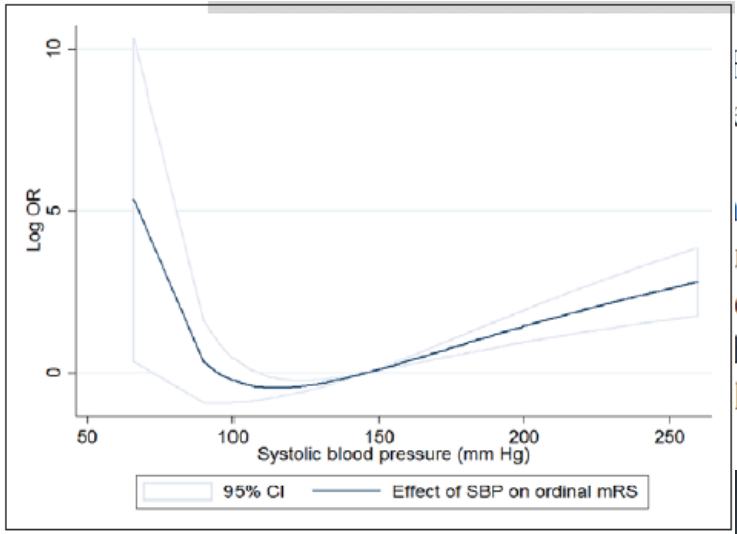

Results—Systolic BP (SBP) had the best correlation with functional outcome. This correlation was U-shaped; both low and high baseline SBP were associated with poor functional outcome. Higher SBP was associated with symptomatic intracranial hemorrhage (adjusted odds ratio, 1.25 for every 10 mm Hg higher SBP [95% confidence interval, 1.09–1.44]). Between SBP and IAT, there was no interaction for functional outcome, symptomatic intracranial hemorrhage, or other

Mulder M, et al. Stroke 2017;48:1869-1876.

Where should bp goals post mt be?

- Permissive HTN <220/120 without IVT or <180/90 after IVT
- Moderate BP control <160/90
- Intensive BP control <140/90

EDITORIAL

Determining the optimal target blood pressure after thrombectomy

High or low?

Wartenberg KE, Mayer SA. Neurology 2017;89:528-529.

Blood pressure levels post mechanical thrombectomy and outcomes in large vessel occlusion strokes

Nitin Goyal, MD
Georgios Tsivgoulis, MD
Abhi Pandhi, MD
Jason J. Chang, MD
Kira Dillard, MD
Muhammad Fawad Ishfaq, MD
Katherine Nearing, MD
Asim F. Choudhri, MD
Daniel Hoit, MD, MPH
Anne W. Alexandrov, PhD
Adam S. Arthur, MD, MPH
Lucas Elijovich, MD
Andrei V. Alexandrov, MD

Correspondence to Dr. Goyal: ngoyal@uthsc.edu

ABSTRACT

Objective: There are limited data evaluating the effect of post mechanical thrombectomy (MT) blood pressure (BP) levels on early outcomes of patients with large vessel occlusions (LVO). We sought to investigate the association of BP course following MT with early outcomes in LVO.

Methods: Consecutive patients with LVO treated with MT during a 3-year period were evaluated. Hourly systolic BP (SBP) and diastolic BP (DBP) values were recorded for 24 hours following MT and maximum SBP and DBP levels were identified. LVO patients with complete reperfusion following MT were stratified in 3 groups based on post-MT achieved BP goals: <140/90 mm Hg (intensive), <160/90 mm Hg (moderate), and <220/110 mm Hg or <180/105 mm Hg when pretreated with IV thrombolysis (permissive hypertension). Three-month functional independence was defined as modified Rankin Scale score of 0–2.

Results: A total of 217 acute ischemic stroke patients with LVO were prospectively evaluated. A 10 mm Hg increment in maximum SBP documented during the first 24 hours post MT was independently ($p = 0.001$) associated with a lower likelihood of 3-month functional independence (odds ratio [OR] 0.70; 95% confidence interval [CI] 0.56–0.87) and a higher odds of 3-month mortality (OR 1.49; 95% CI 1.18–1.88) after adjusting for potential confounders. In addition, achieving a BP goal of <160/90 mm Hg during the first 24 hours following MT was independently associated with a lower likelihood of 3-month mortality (OR 0.08; 95% CI 0.01–0.54; $p = 0.010$) in comparison to permissive hypertension.

Conclusions: High maximum SBP levels following MT are independently associated with increased likelihood of 3-month mortality and functional dependence in LVO patients. Moderate BP control is also related to lower odds of 3-month mortality in comparison to permissive hypertension. ***Neurology*® 2017;89:1–8**

Can one size fit all?

- TICI 3 + Dramatic neurological recovery
- TICI 3 and no Neurological improvement
- TICI 2 ± Neurological improvement
- No recanalization

Lessons learned with monitoring

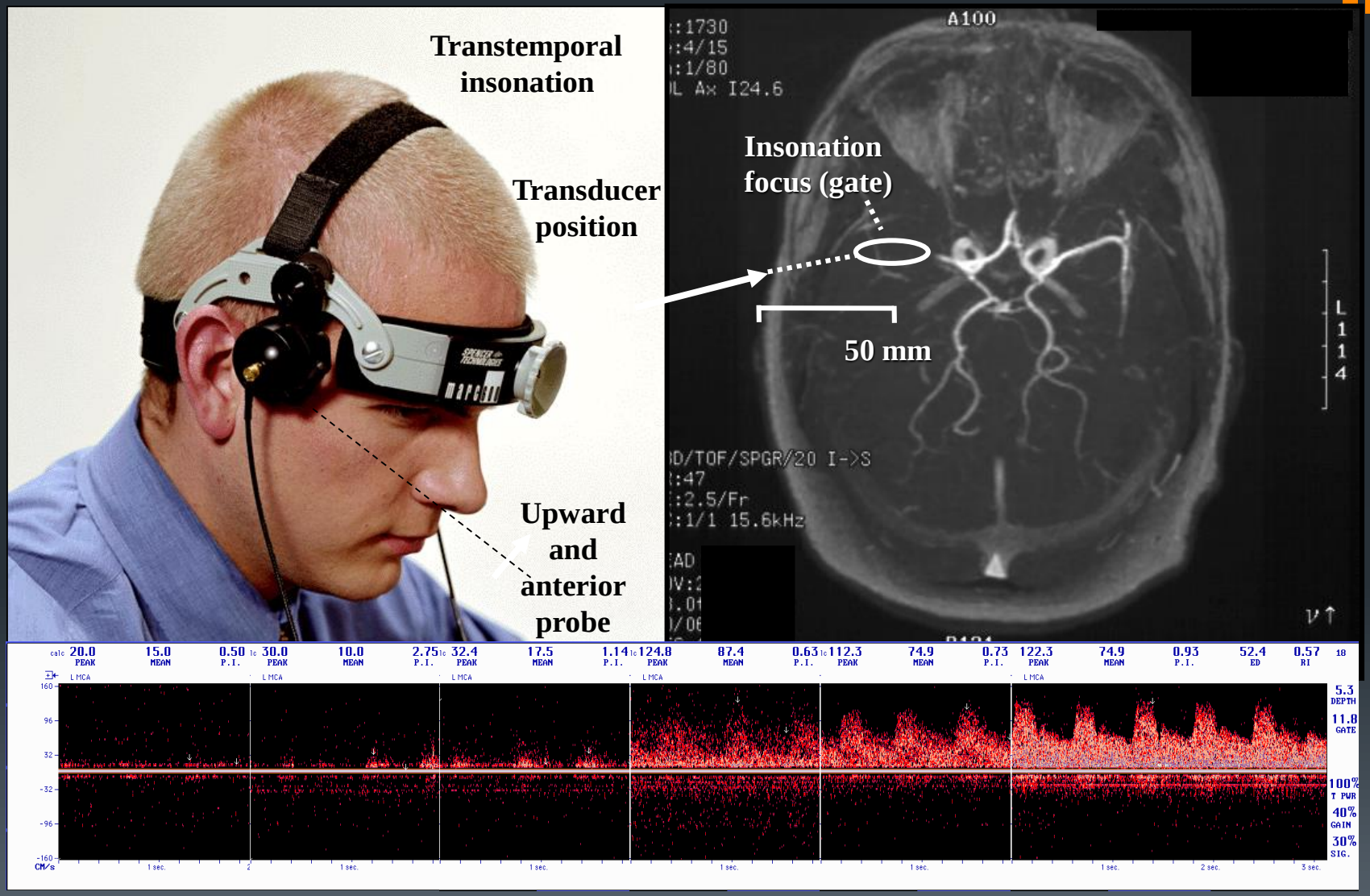

Demchuk AM, et al. Circulation 2000;100:2282-83.

Lessons learned with monitoring

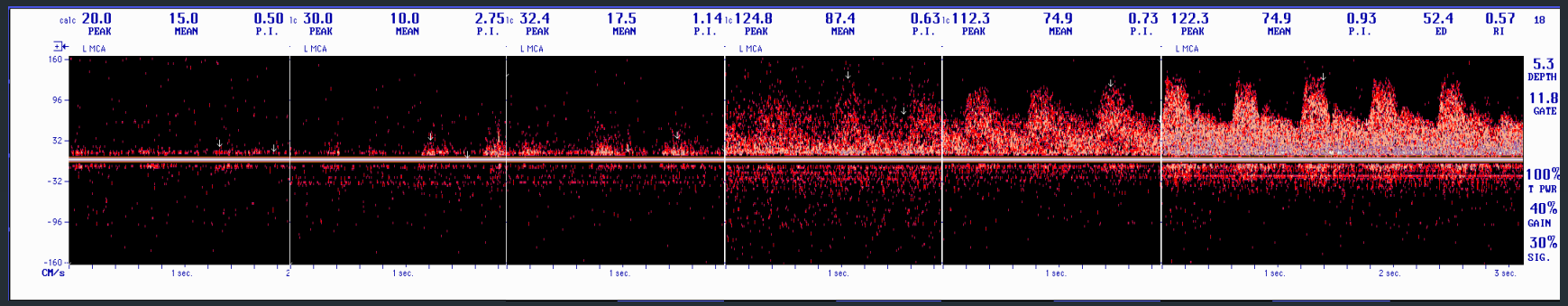

13:02

TPA bolus

NIHSS 15

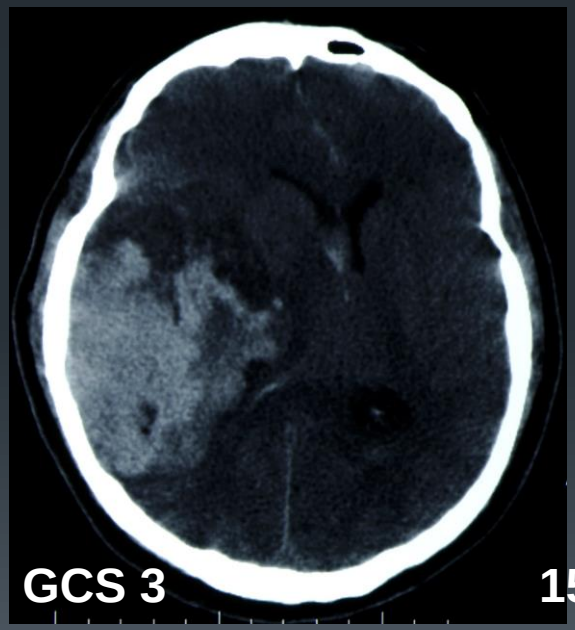

13:38

15:25 NIHSS 15

Demchuk AM, et al. Circulation 2000;100:2282-83.

Hyperemic reperfusion after mt

- Analogous to cerebral hyperperfusion syndrome after carotid endarterectomy leading to headache, seizures and SAH/blood extravasation
- Contributes to hemorrhagic transformations, sICH, edema, neurological decline and seizures after stroke
- Directly detectable by TCD during or after MT: normal or elevated MFVs with abnormally low resistance flow pattern (PI decrease >30% vs unaffected side) in the previously occluded vessel[1]

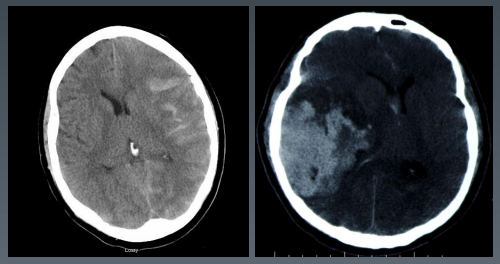

[1]Rubiera M, et al. Stroke 2010;41:695-699.

Until RCT(s) become available…

- TICI 3 + Dramatic neurological recovery < 140/80
- TICI 3, no Neurological improvement <160/90
- TICI 2 ± Neurological improvement <160/90
- No recanalization <160/90 or permissive hypertension <180/90
- Strict BP control to avoid variability in all groups

Personal opinion.

Stroke Patient Evaluation with US

- Extension of neurological examination
- Bedside testing
- Real time assessment of hemodynamics
- Ascertaining stroke pathogenesis
- Continuous monitoring
- Aid therapies

Any questions?