Carotid Ultrasound Clinical Applications

Charles H. Tegeler, MD
McKinney-Avant Professor
Vice-Chair, Faculty Development
Founding Director, Telestroke Program
Director, Ward A. Riley Ultrasound Center
Wake Forest School of Medicine

Carotid Ultrasound Clinical Applications

- Why do it?
- Highlighting examples/concepts of:
- Doppler velocities
- B-mode imaging
- Duplex and color flow imaging

CEA Specimen: ICA Plaque

Carotid Ultrasound

Clinical Imperatives

- Carotid/Vertebral disease is the most commonly identified stroke mechanism
- Carotid/Vertebral atherosclerosis/stenosis is marker of increased stroke risk
- Established surgical benefit for tight symptomatic carotid stenosis (NASCET) and tight asymptomatic stenosis (ACAS, ACST)
- Efficacy and growth of stenting

Carotid/Vertebral Ultrasound
Clinical Decision-Making

- Carotid ultrasound part of initial vascular evaluation for patients with Stroke or TIA, or at risk for the same.
- Safe, accurate, portable, relatively less expensive, and readily available.
- If CUS negative, usually don’t pursue
- Ideal for serial follow up for progression

Carotid Ultrasound
Common Indications

- Stroke, TIA, Cerebral ischemia
- Bruit evaluation (Sx or Asx)
- Serial follow up of CVD
- Pre-op study, or perioperative in CEA
- Pulsatile neck masses/abnormal structures
- High risk groups to screen for tight stenosis

Carotid/Vertebral Ultrasound

Clinical Questions to Answer

- Is any carotid stenosis present?
- If so, where, what is the distribution, how bad is it, and is it accessible?
- Most Rx decisions still made based on hemodynamic effect (% stenosis)
- Plaque features can influence decision

Vascular Doppler

- Blood cells/components act as moving scatterers (reflectors)
- Imparts frequency shift to scattered Doppler beam (higher or lower)
- Instrument can determine magnitude of Doppler shift in cycles/sec (Hz)
- With AOI can get velocity (cm/s); provides common language across labs/instruments

Doppler Spectral Analysis

FFT Spectral Display

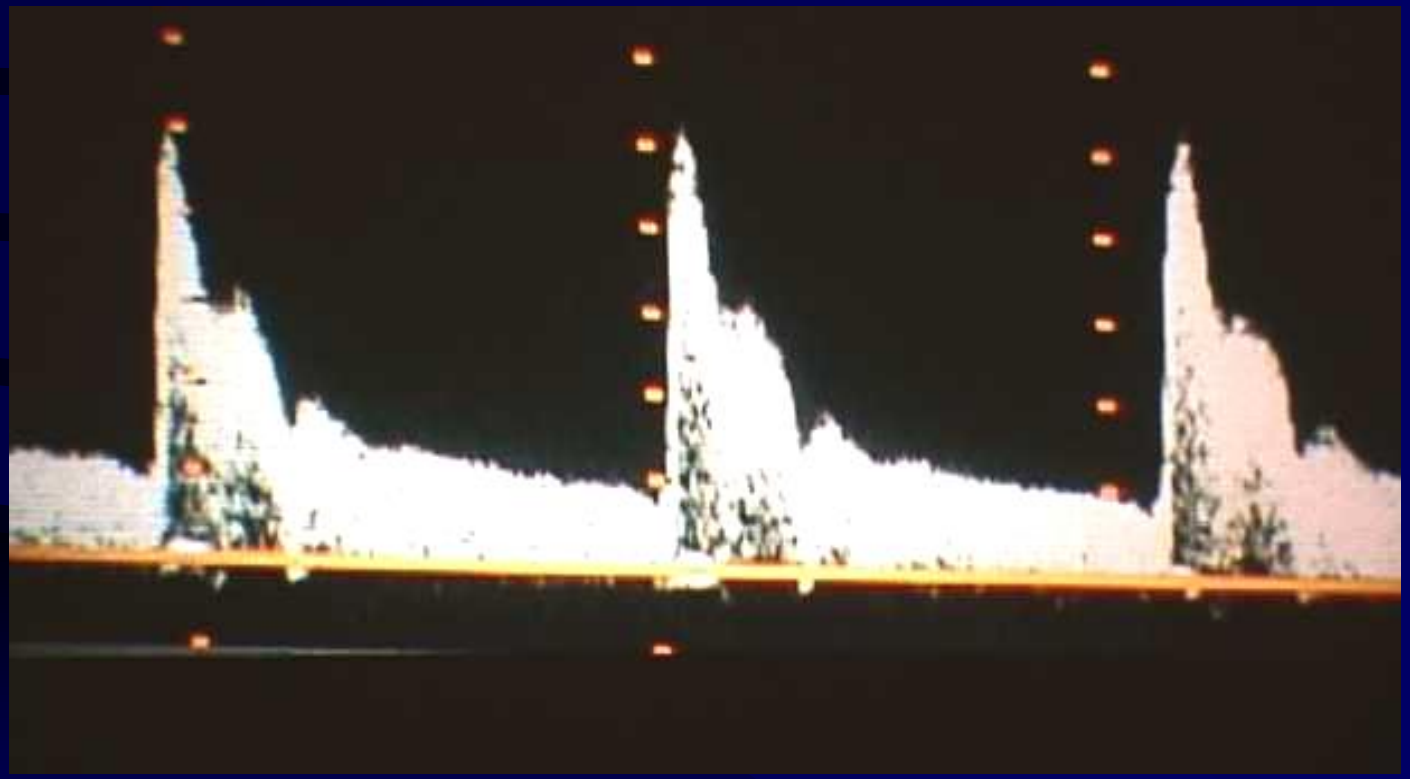

Vascular Doppler

Spectral Analysis Parameters

- Flow direction
- Peak systolic velocity
- End-diastolic velocity
- Spectral pattern (vessel fingerprint)
- Spectral broadening

Doppler Spectral Analysis

Parameters

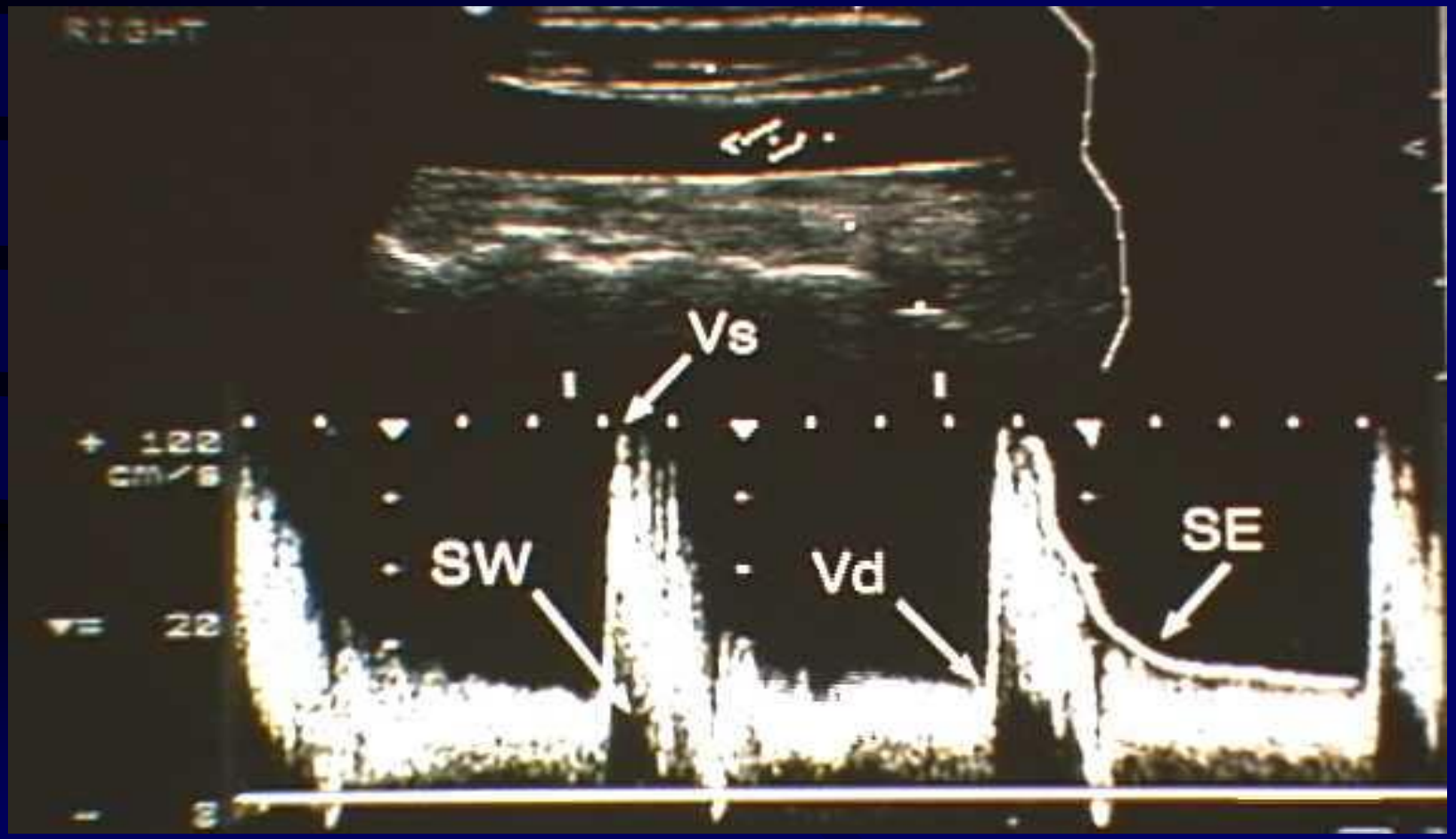

Doppler Spectral Analysis

Spectral Fingerprints

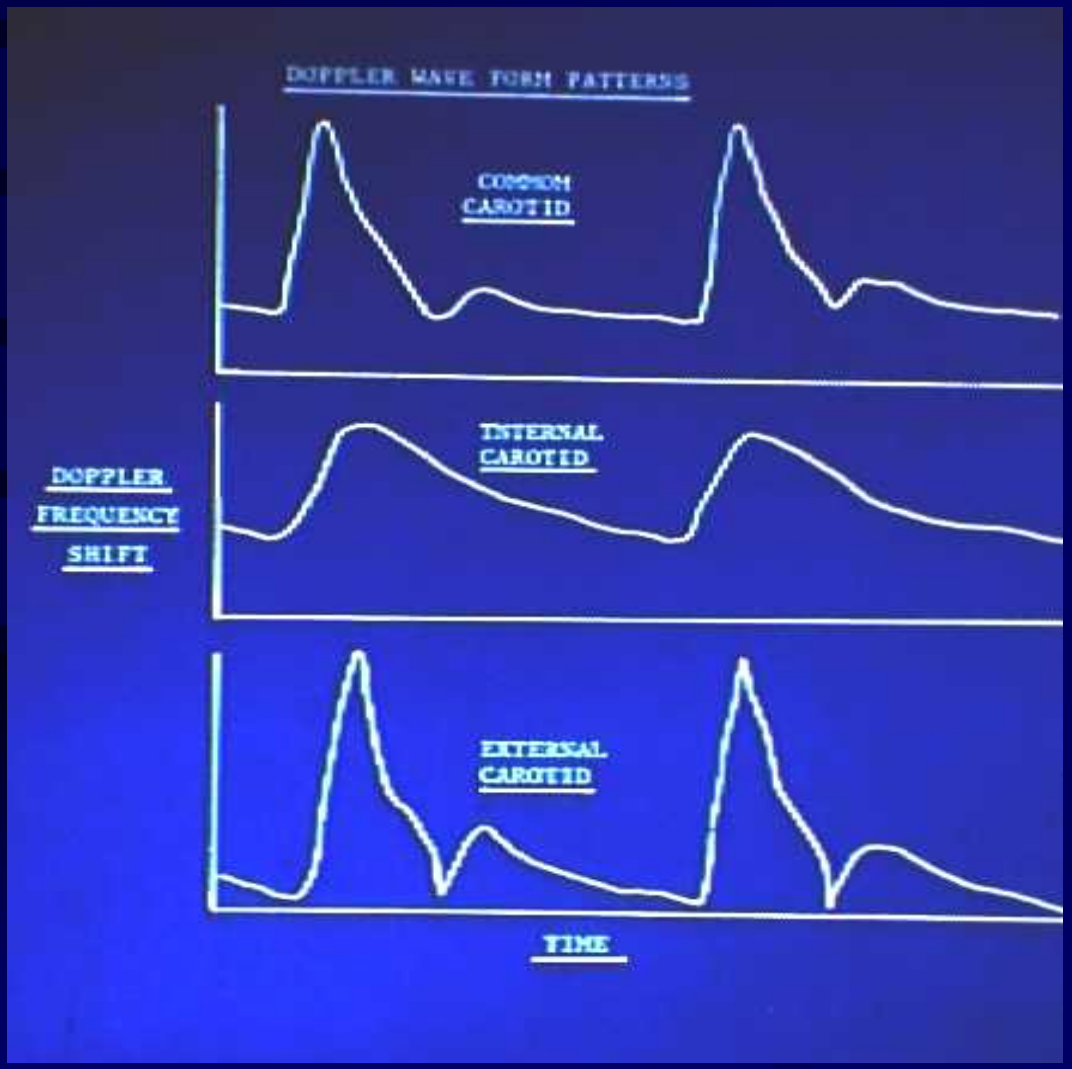

Hemodynamic Effect of Stenosis

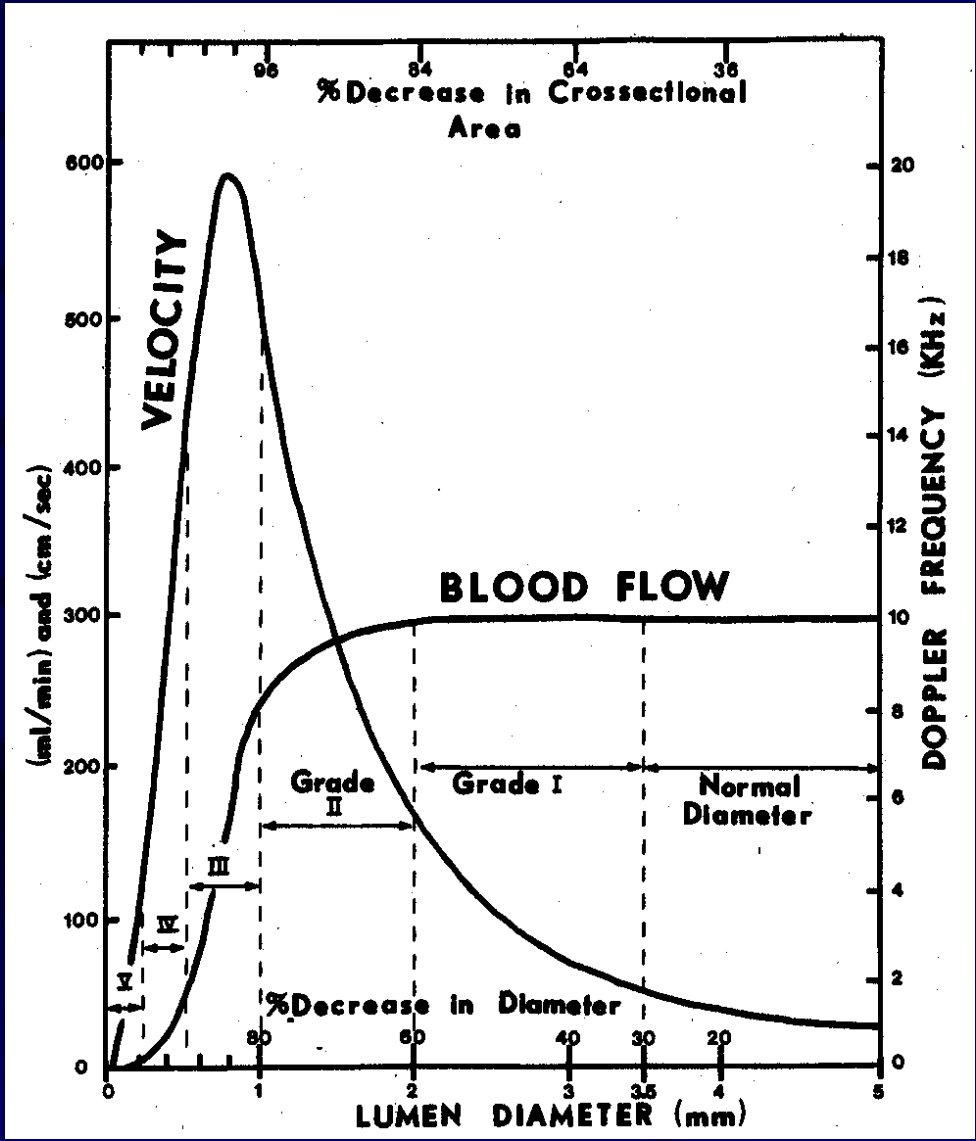

Doppler Velocity Spectral Analysis

Normal ICA Velocity

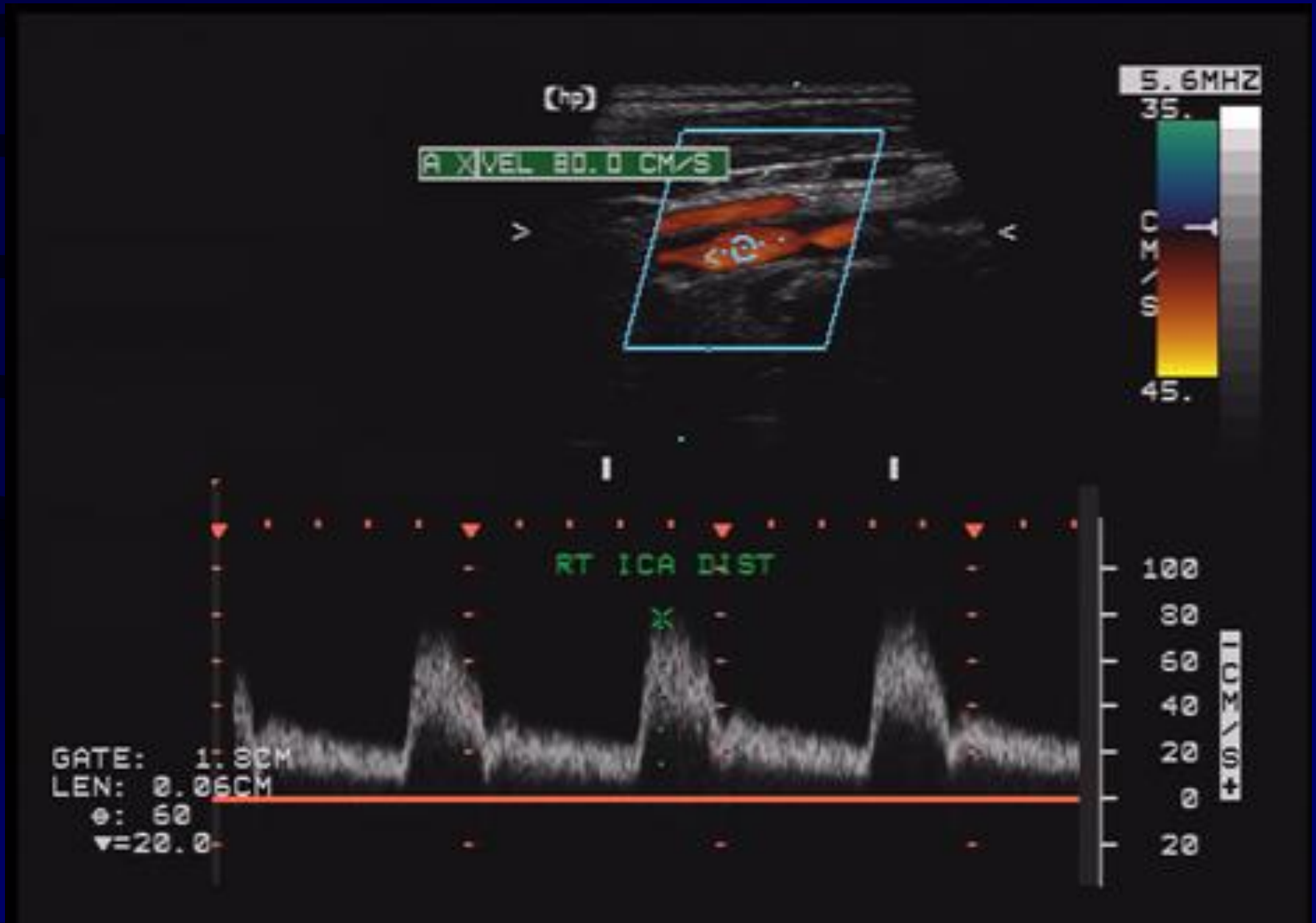

Doppler Spectral Analysis

Changes with Moderate Stenosis

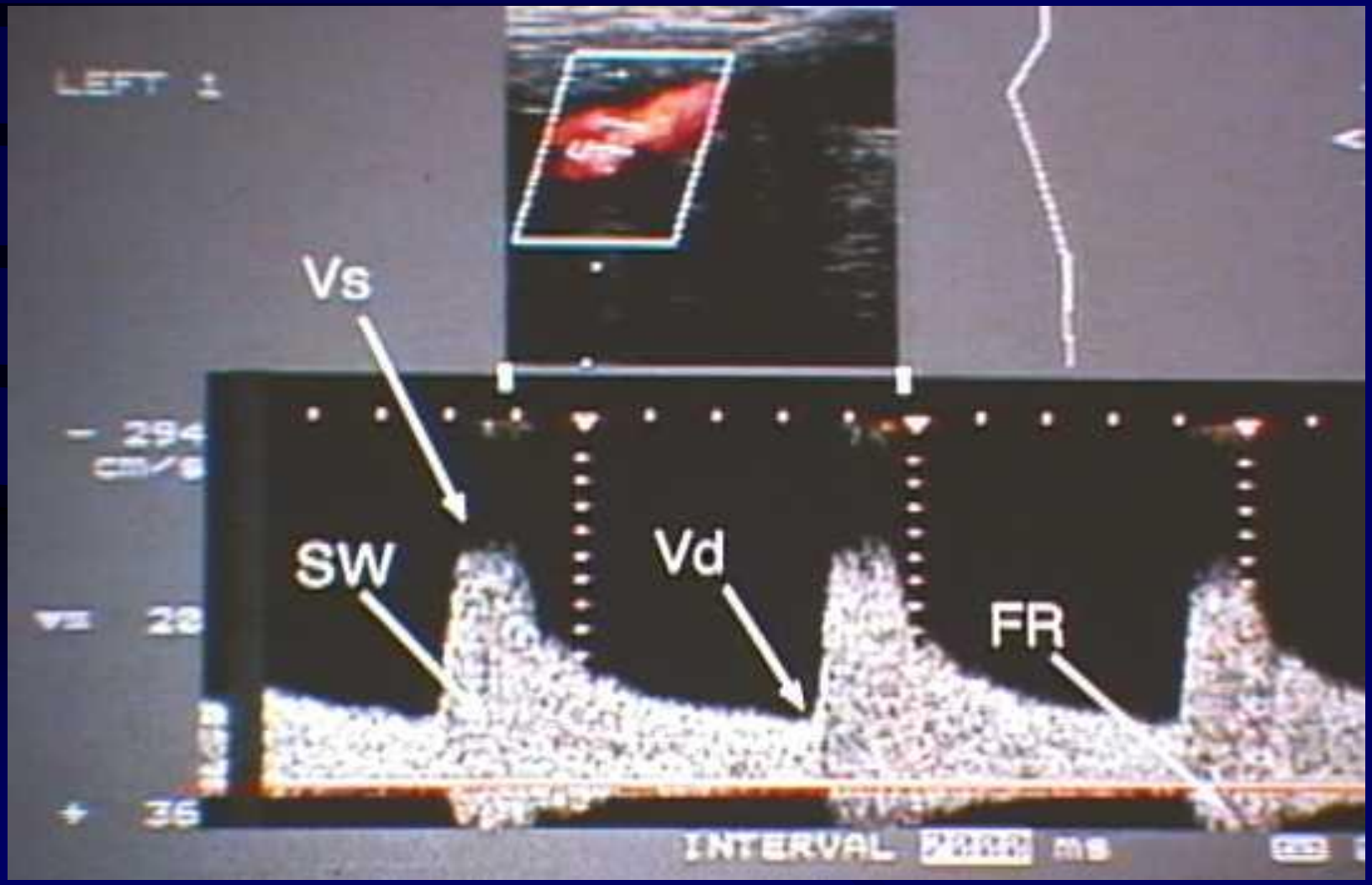

Doppler Spectral Analysis

Severe Stenosis

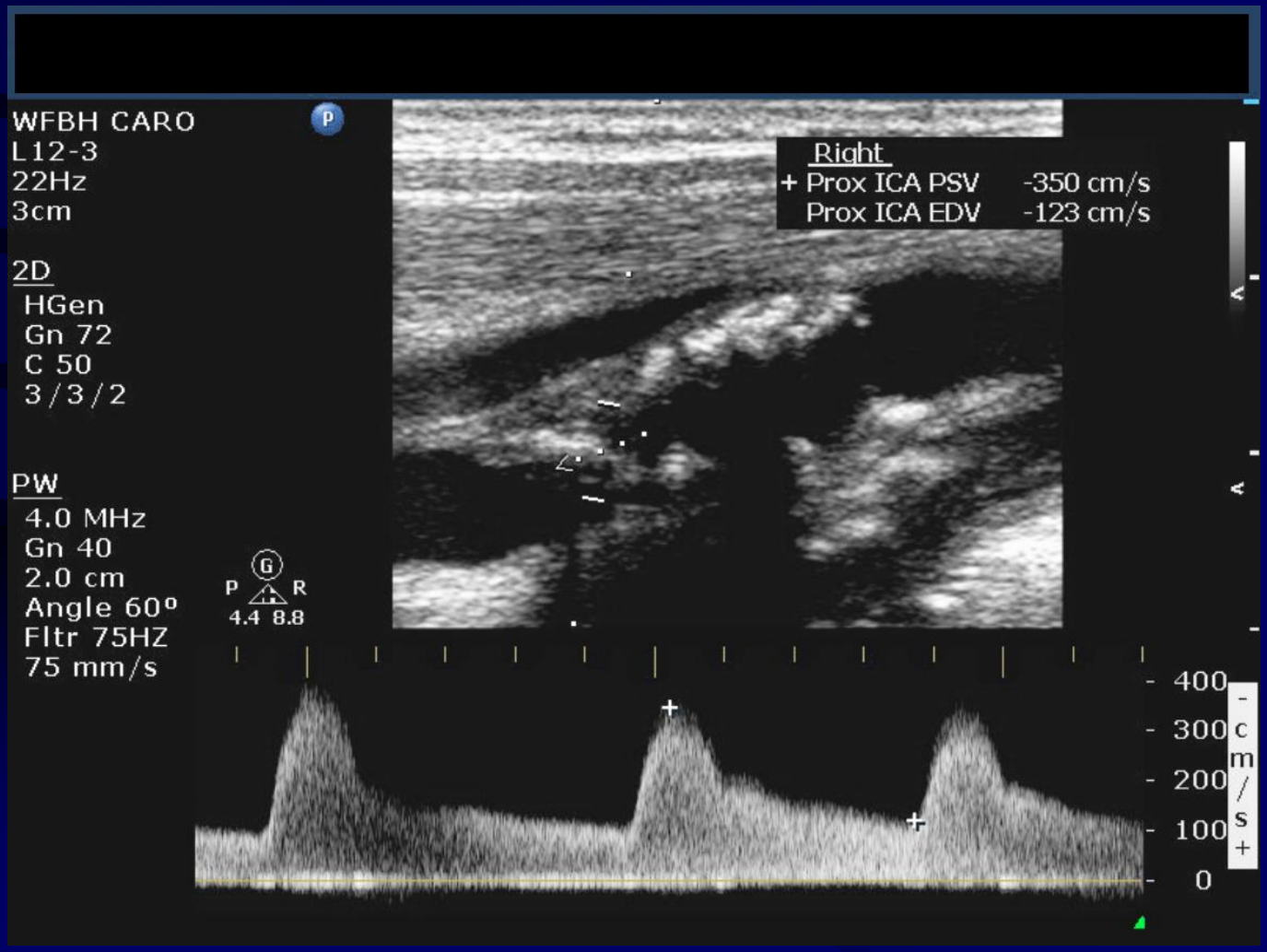

Doppler Spectral Analysis

Severe Stenosis/Near Occlusion



Velocity Criteria at WFBMC

- PRIMARY CRITERIA
- Standard angle peak systolic velocity
- End-diastolic velocity
- SECONDARY PARAMETERS
- Spectral broadening/turbulence, ICA:CCA ratio, resistive pattern in CCA, side differences, extensive plaque on B-mode

Criteria for Carotid Stenosis

WFBMC

% Stenosis	PSV	EDV	ICA:CCA
< 50%	< 140 cm/s	< 40 cm/s	< 2.0
50-69%	> 140 cm/s	< 100 cm/s	2.0-3.0
70-99%	> 140 cm/s	> 100 cm/s	>3.0
Probable Occlusion	N/A	N/A	N/A

Consensus Panel ICA Stenosis Criteria

	Primary	Parameters	Secondary	Parameters
% Stenosis	ICA PSV (cm/s)	Plaque % estimate	ICA/CCA PSV Ratio	ICA EDV (cm/s)
Normal	<125	None	<2.0	<40
<50	<125	<50	<2.0	<40
50-69	125-230	>50%	2.0-4.0	40-100
70-95	>230	>50	>4.0	>100
95-99	High, low, or none seen	Visible	Variable	Variable
Total occlusion	Undetectable	Visible, no lumen	N/A	N/A

Grant et al, 2003

Velocity Criteria
ICA:CCA Ratios

- Relationship between velocity at stenotic site and proximal or distal segments
- Higher stenosis, higher ratio
- Remains constant even if bad heart so can't generate velocity to make stenotic criteria
- ICA:CCA, ICA:Distal ICA validated
- Obtain CCA sample in mid to distal CCA

Indirect Changes

Distal Occlusion

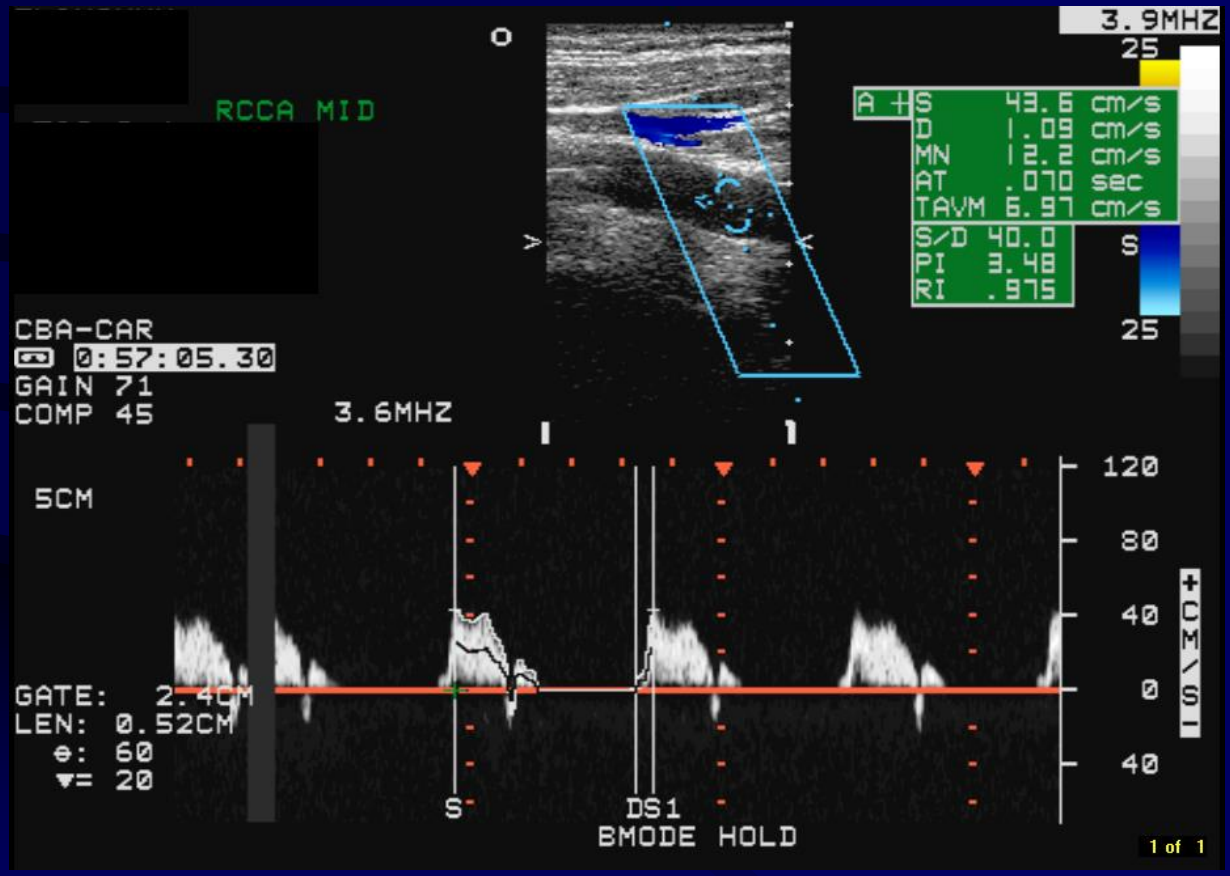

ICA Occlusion

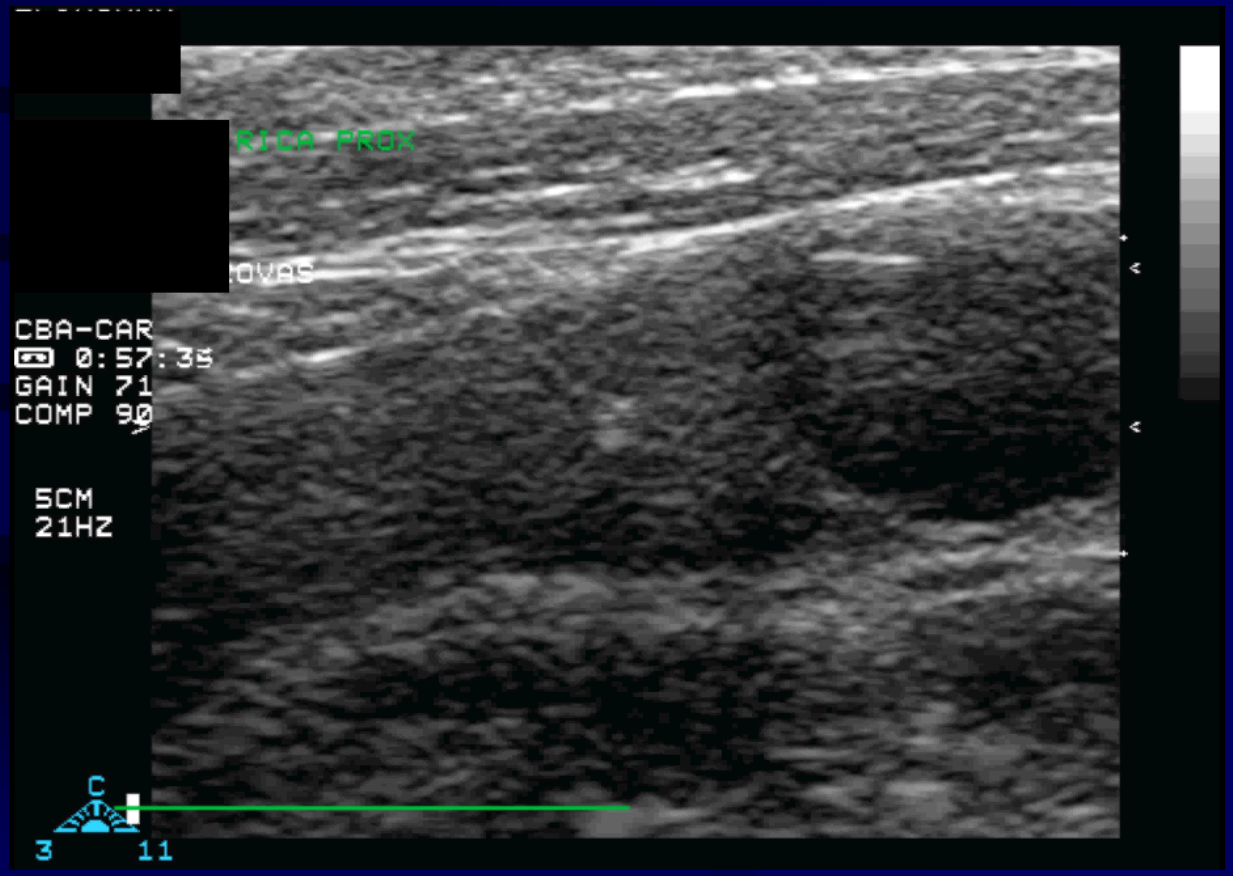

Indirect Changes Proximally

Right ICA String Sign

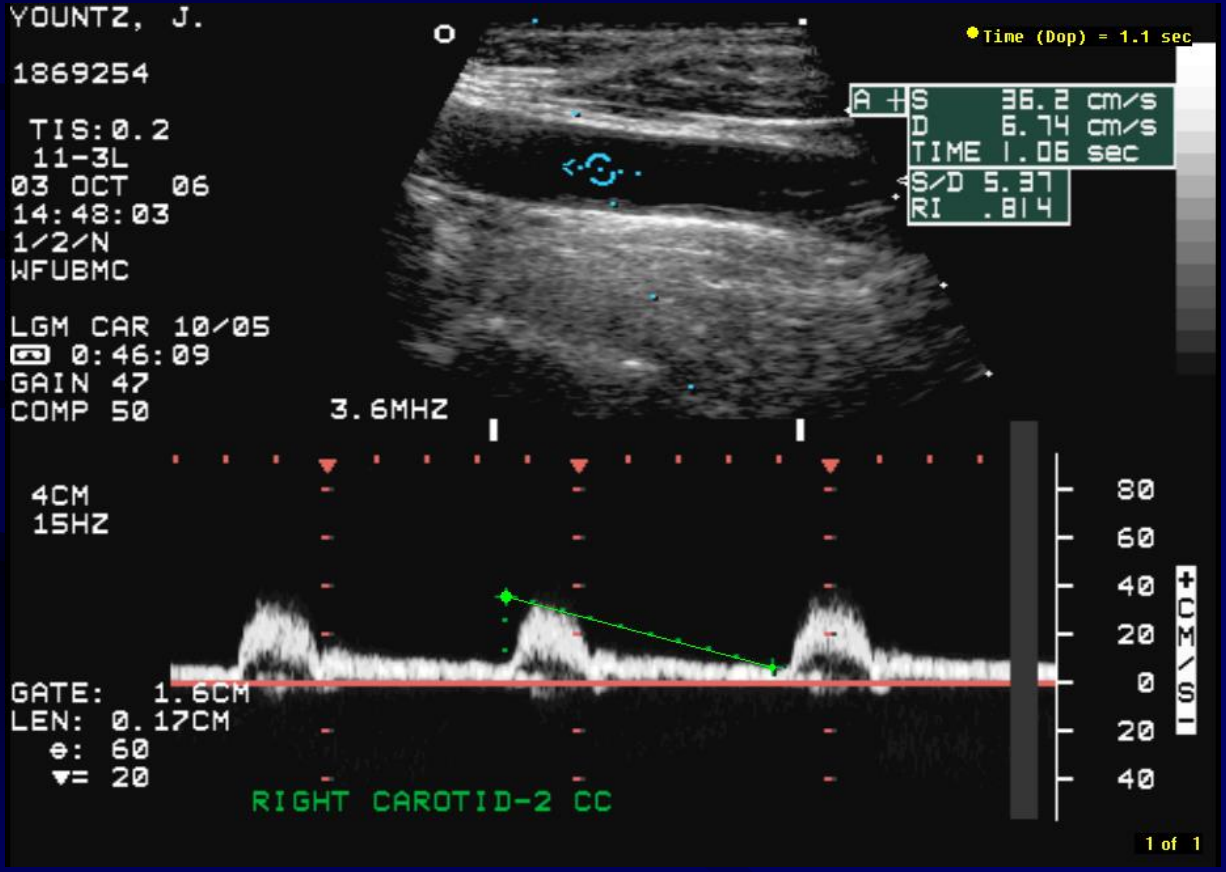

Right ICA String Sign

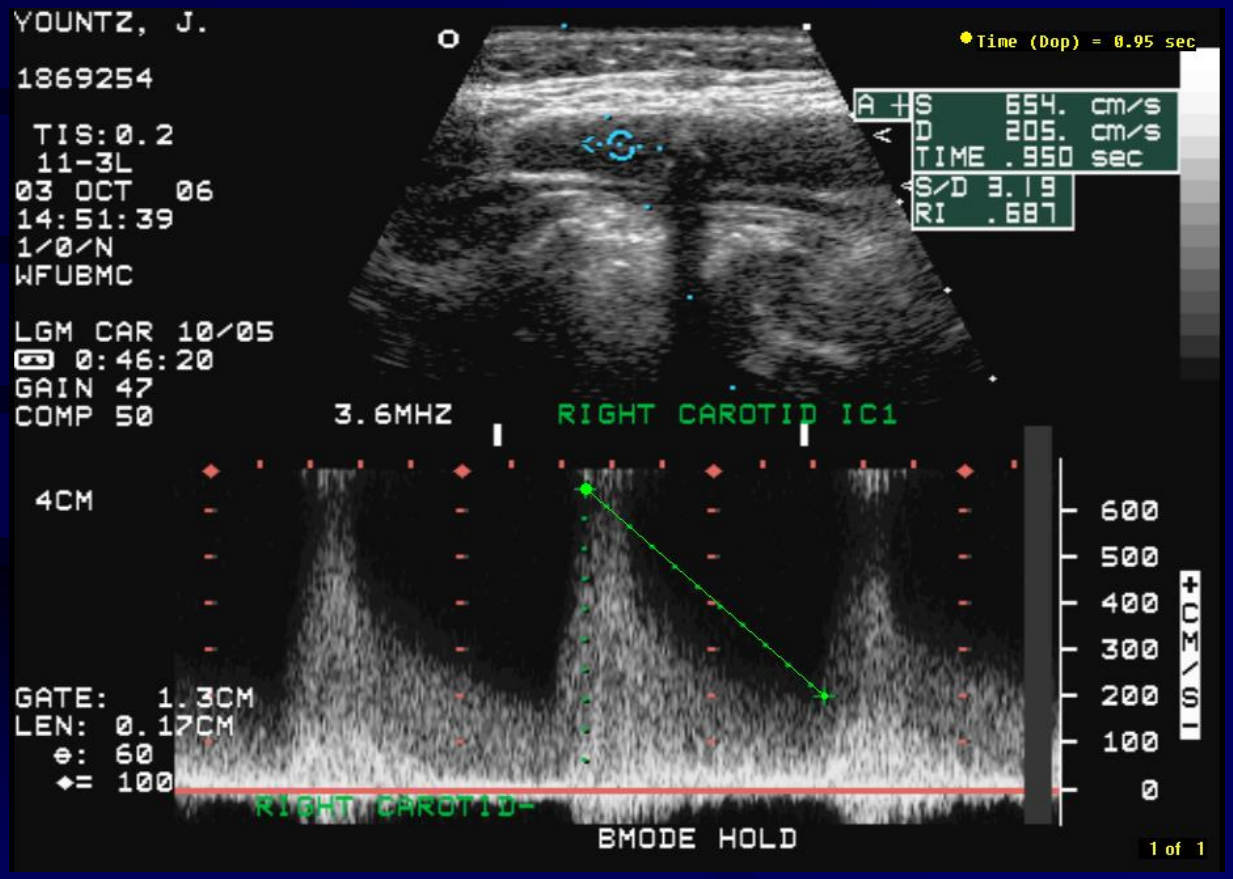

ICA String Sign

Distal Turbulence

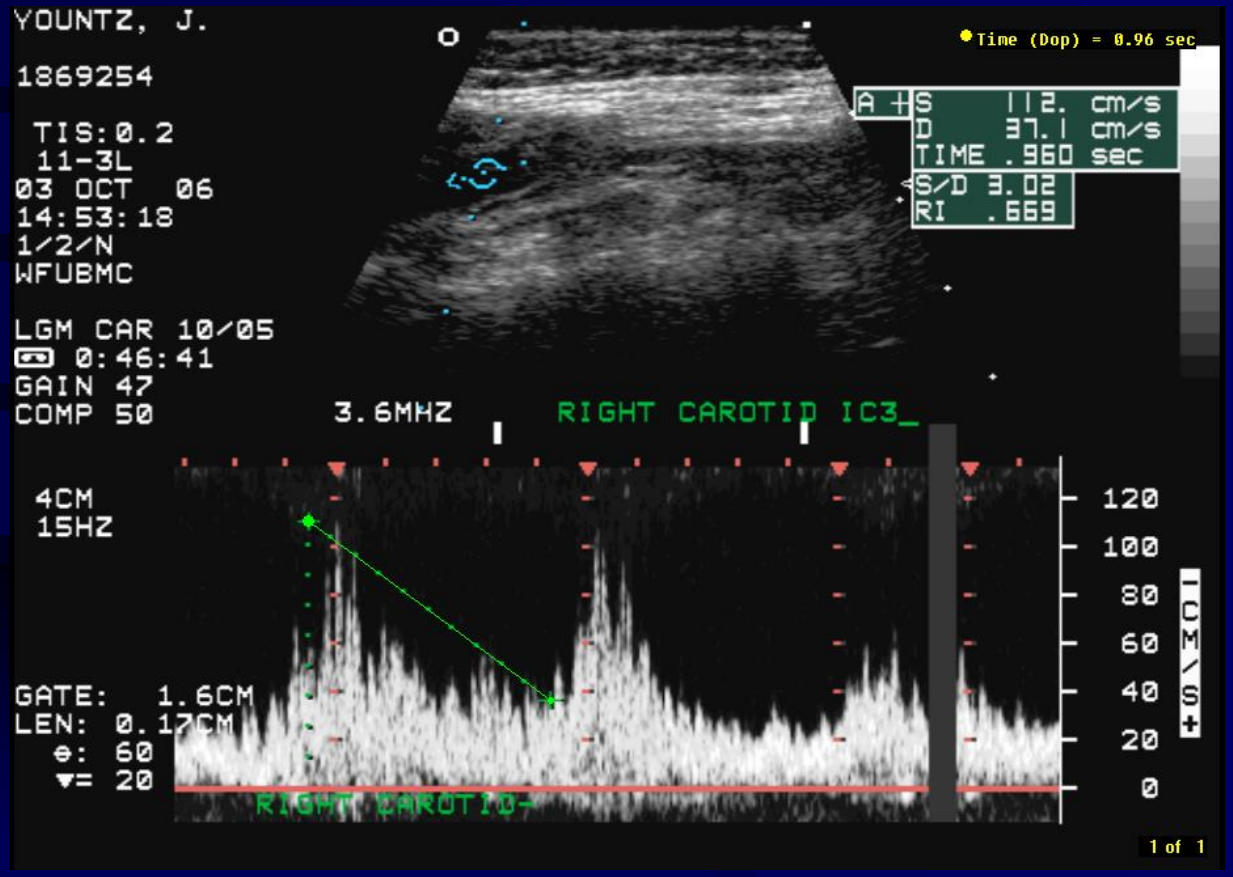

Effect of Cardiac Disease

Aortic Insufficiency

Right CCA waveform

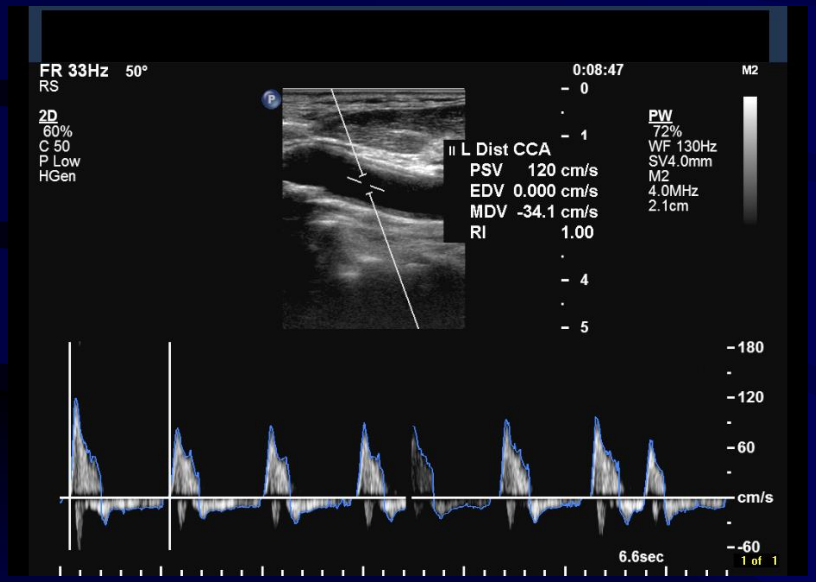

Left CCA waveform

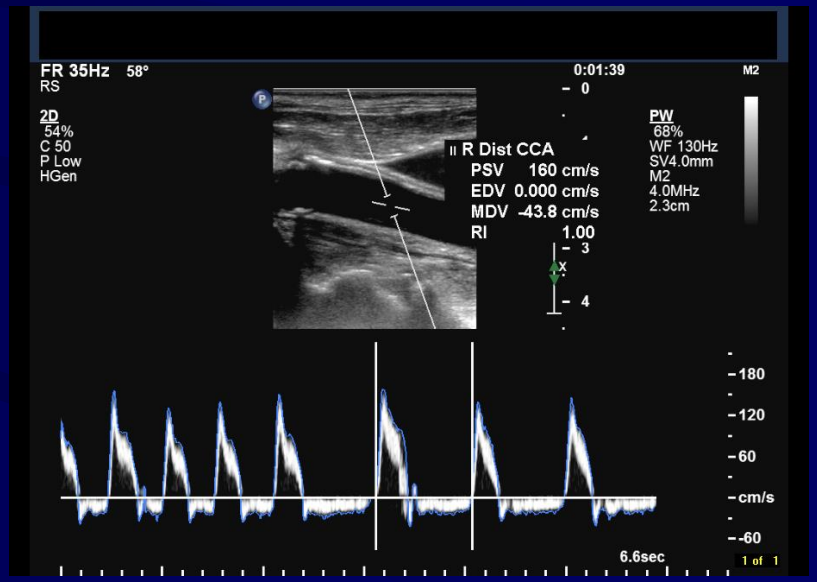

Contralateral Effects

Velocity in Very Proximal CCA

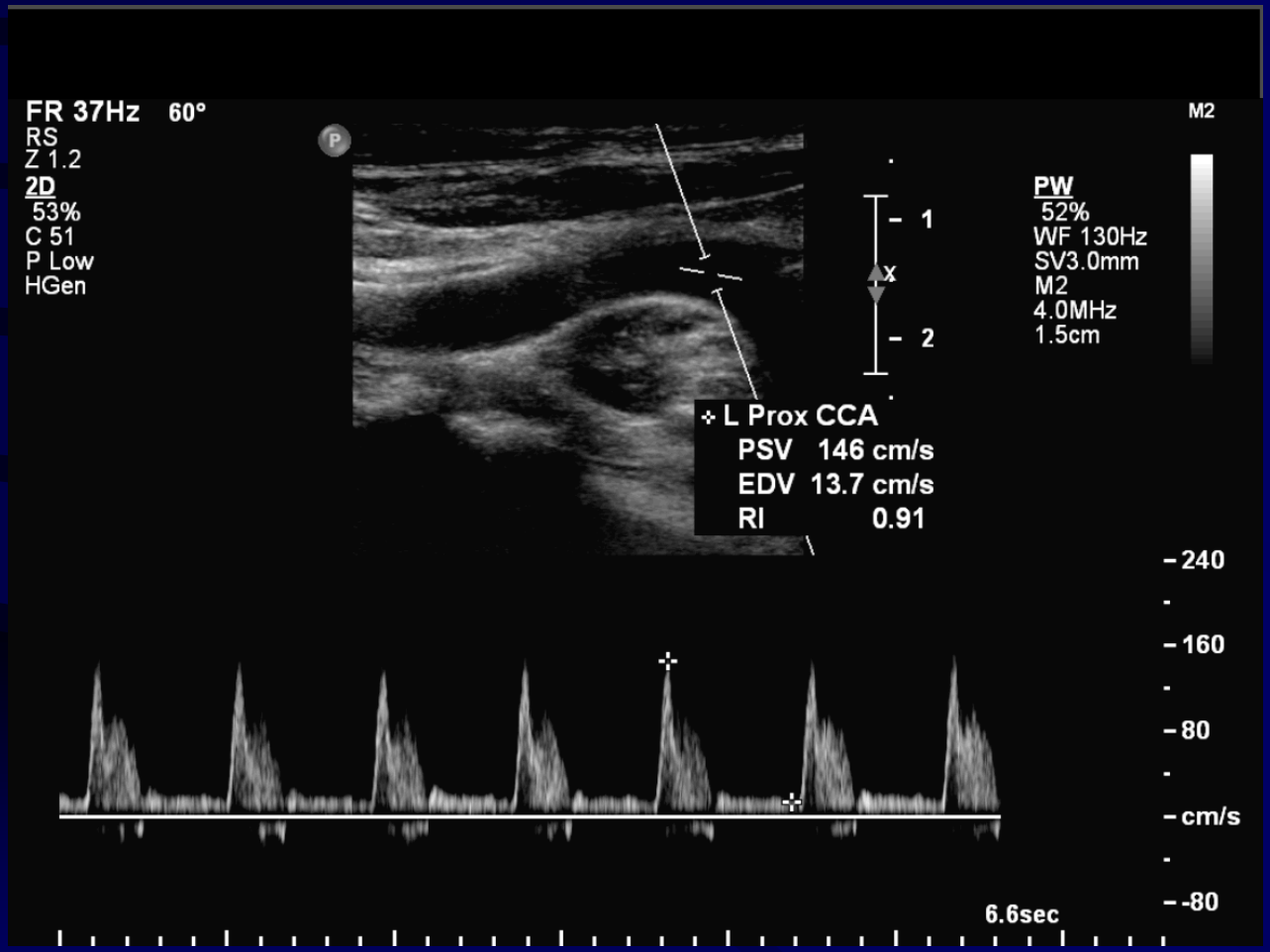

Venous Signal with ICA

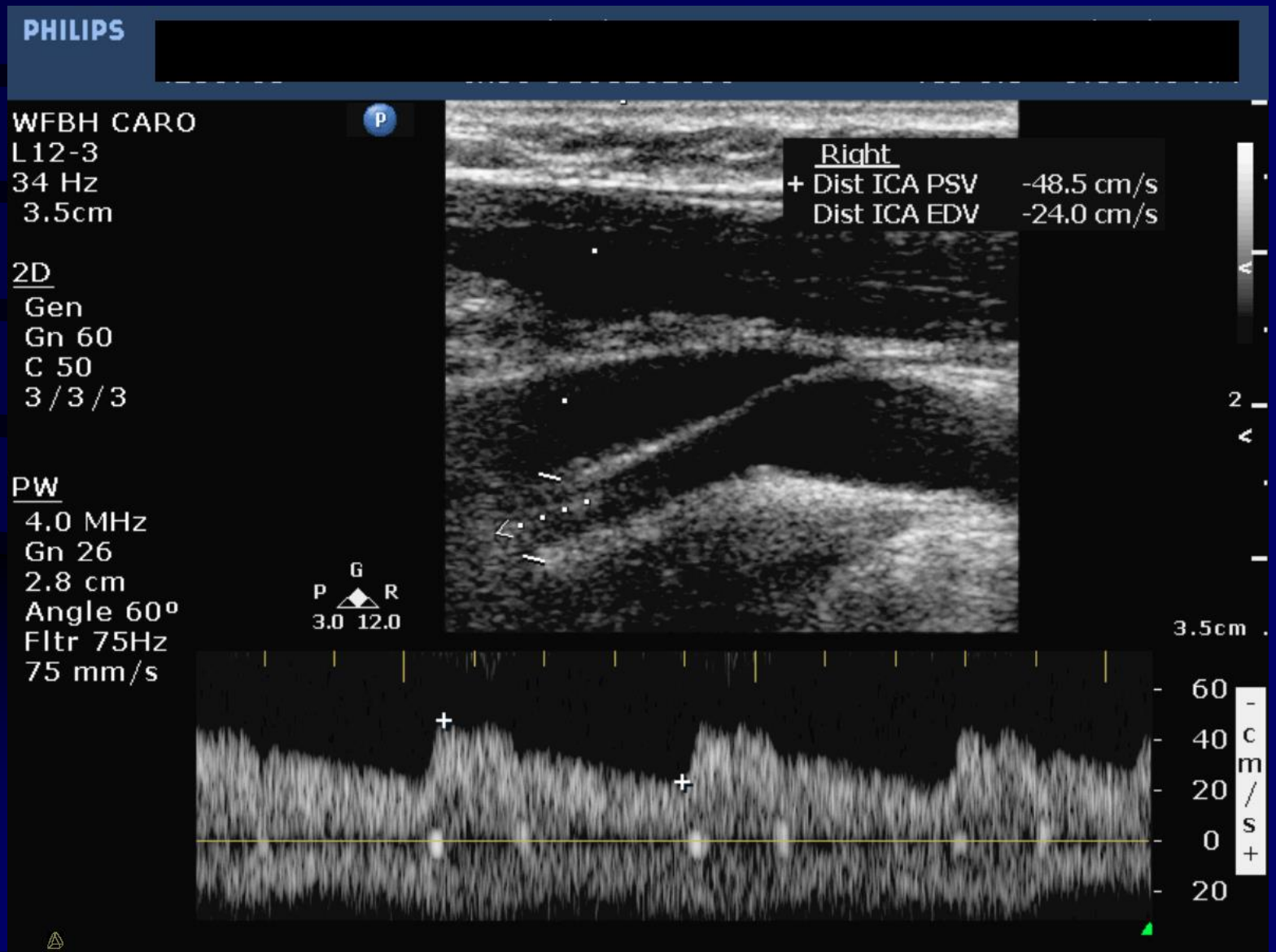

Venous Signal with VA

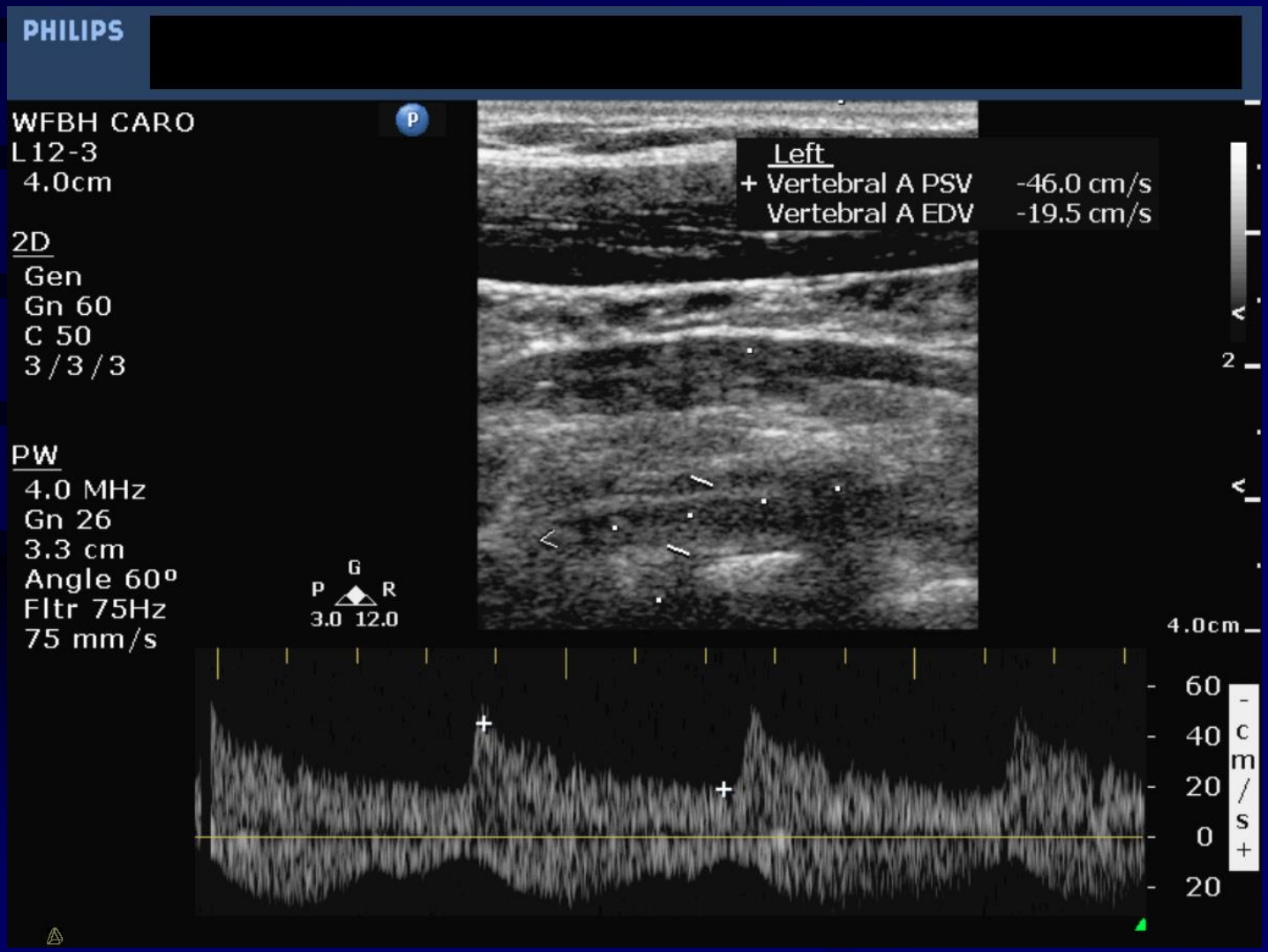

Right ICA Severe Stenosis Case

Resistive Signal in CCA

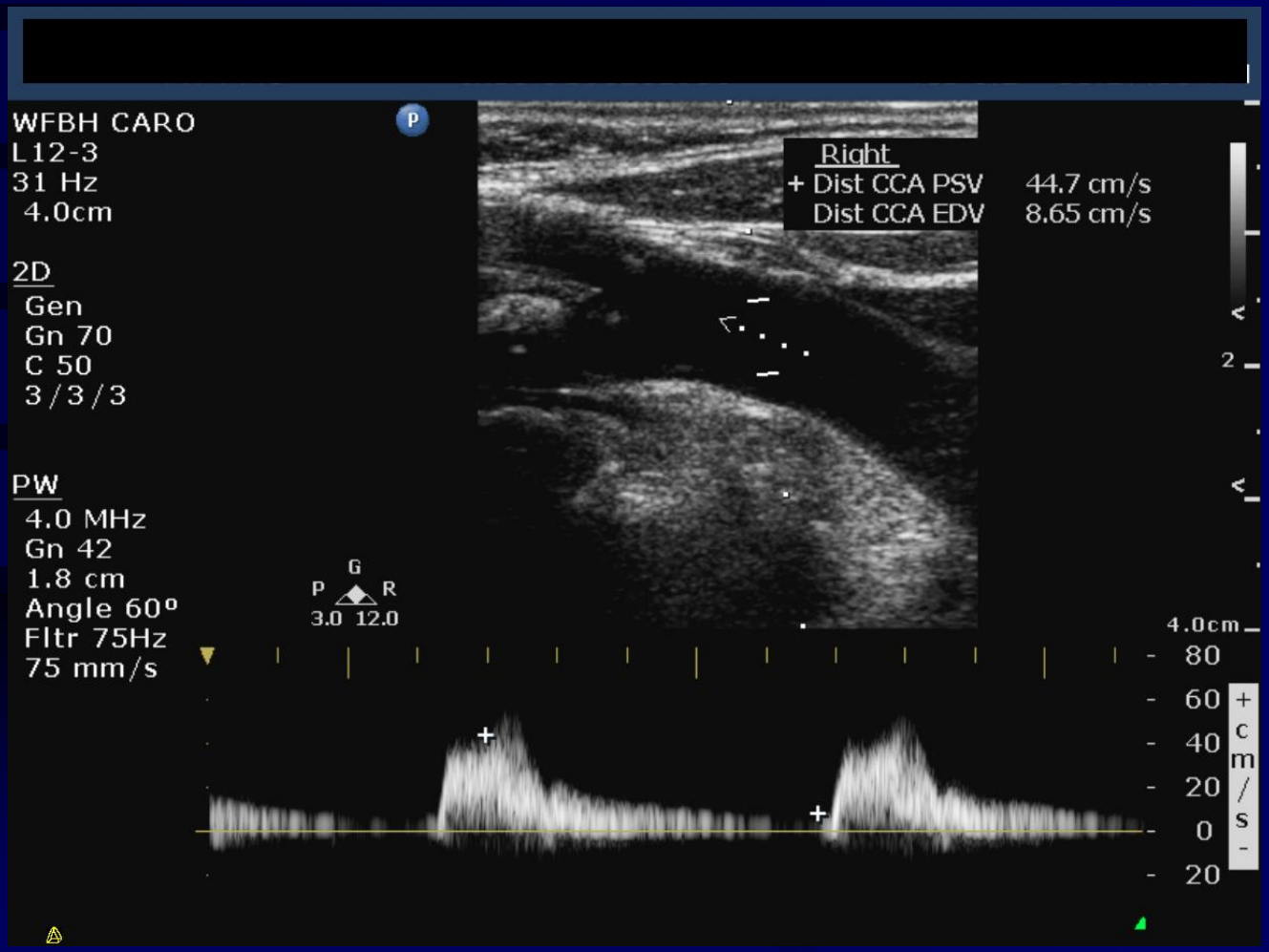

Right ICA Severe Stenosis

Increased Diastolic Velocity ECA

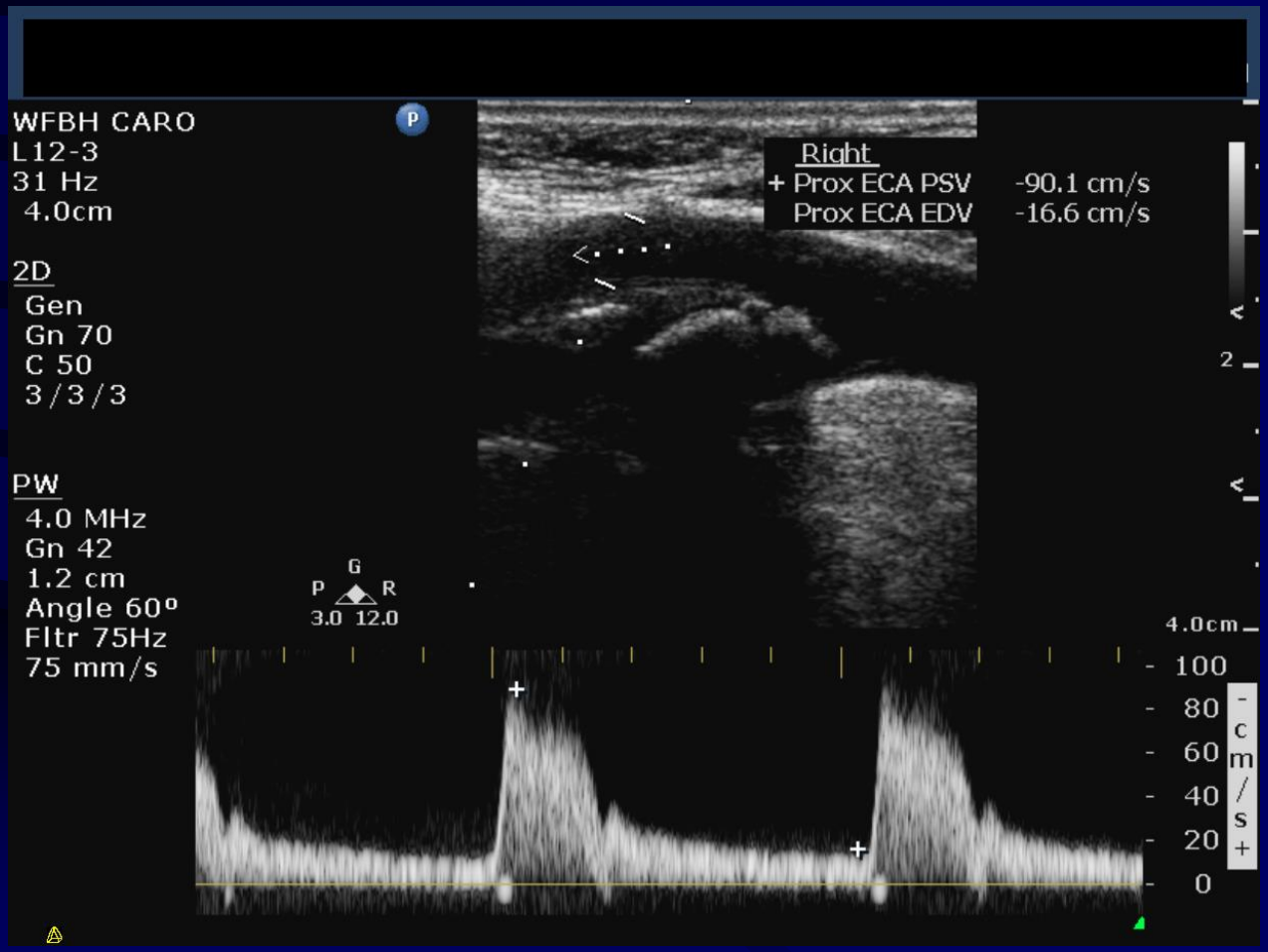

Right ICA Severe Stenosis

Aliasing with actual systolic velocity >800 cm/s

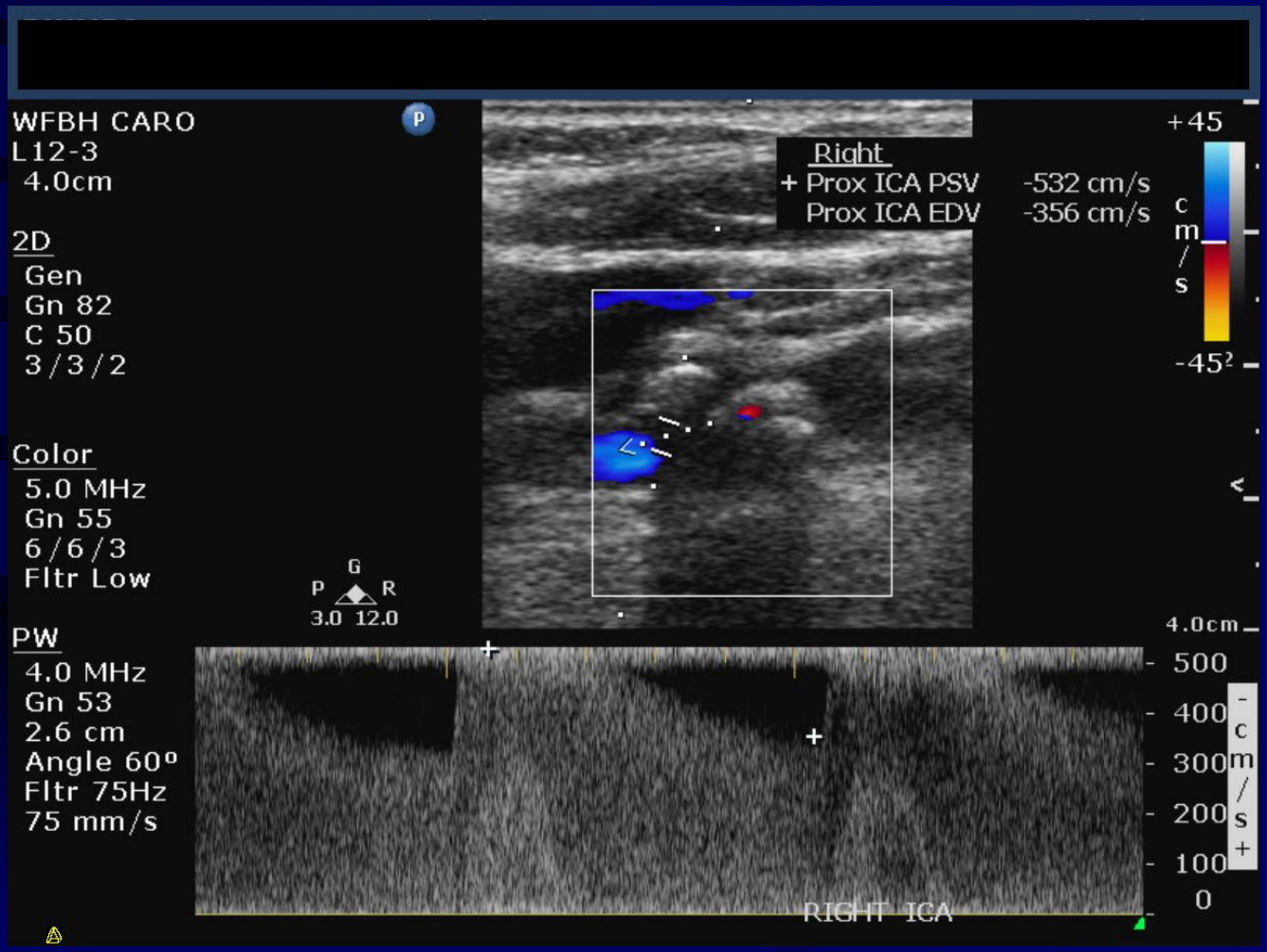

Right ICA Severe Stenosis

Post-Stenotic Turbulence

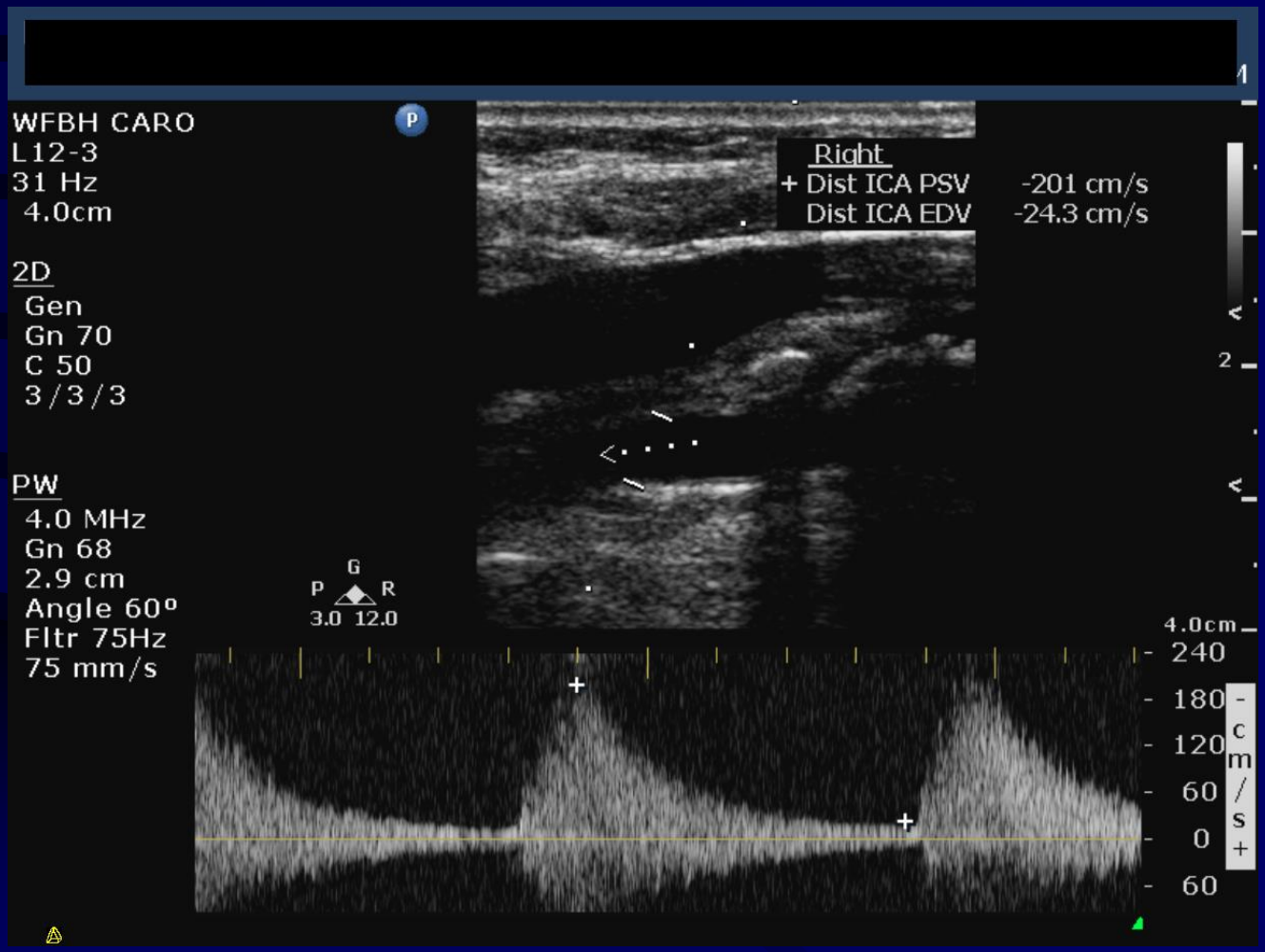

Right ICA Severe Stenosis

Decreased Acceleration Slope Distally

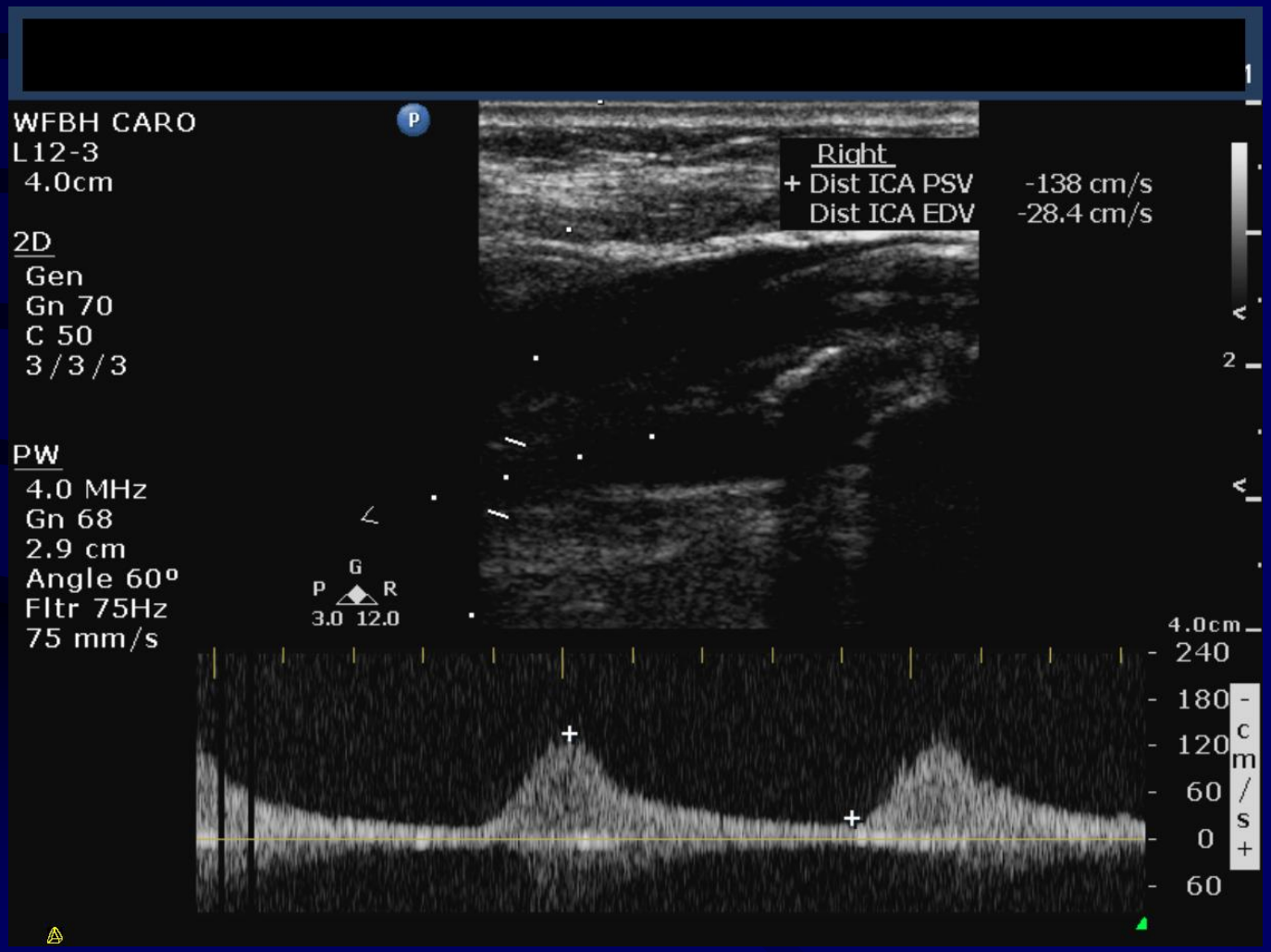

Right ICA Severe Stenosis

Reversed OA as Collateral Pathway

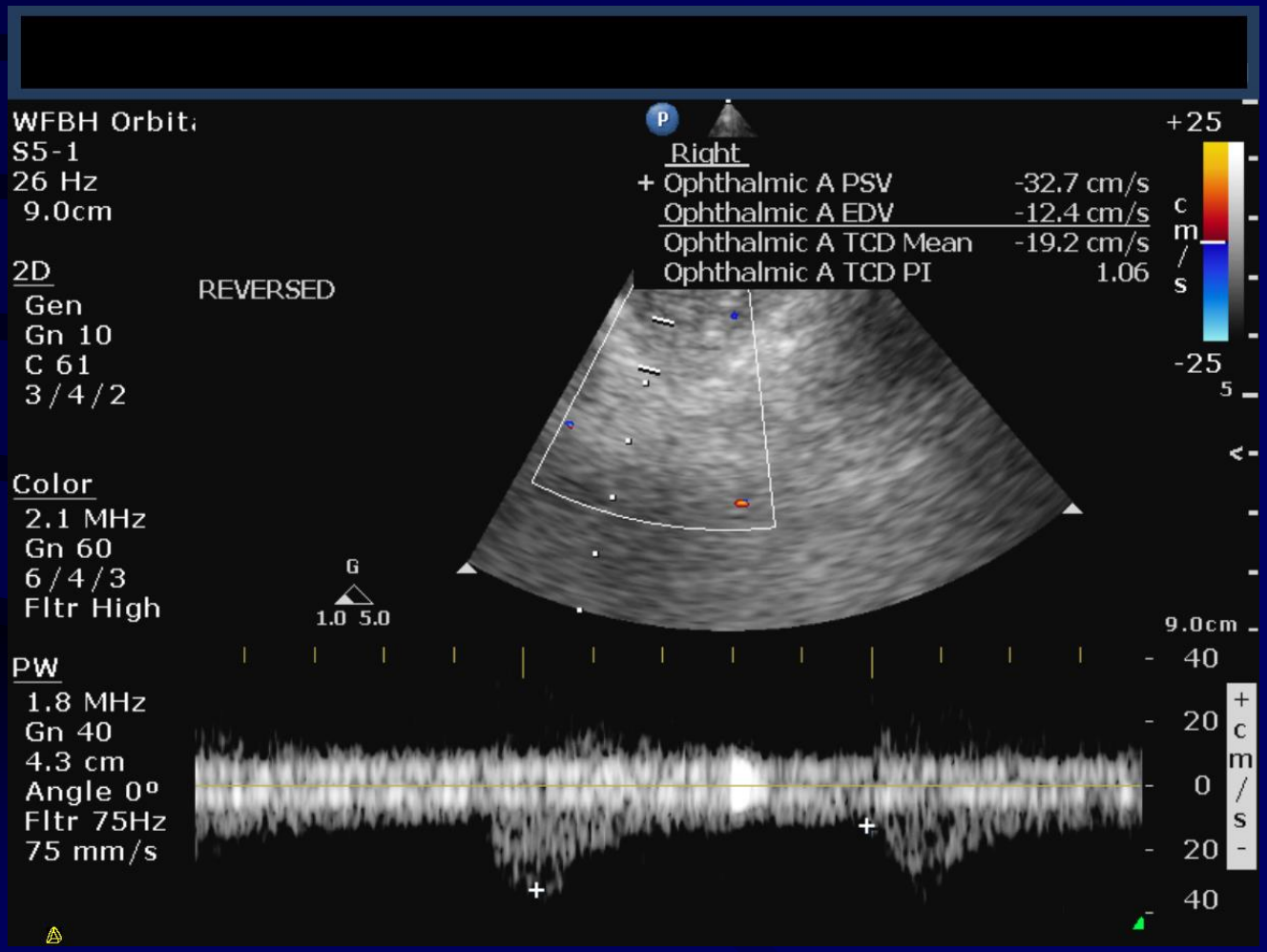

Stump Signal

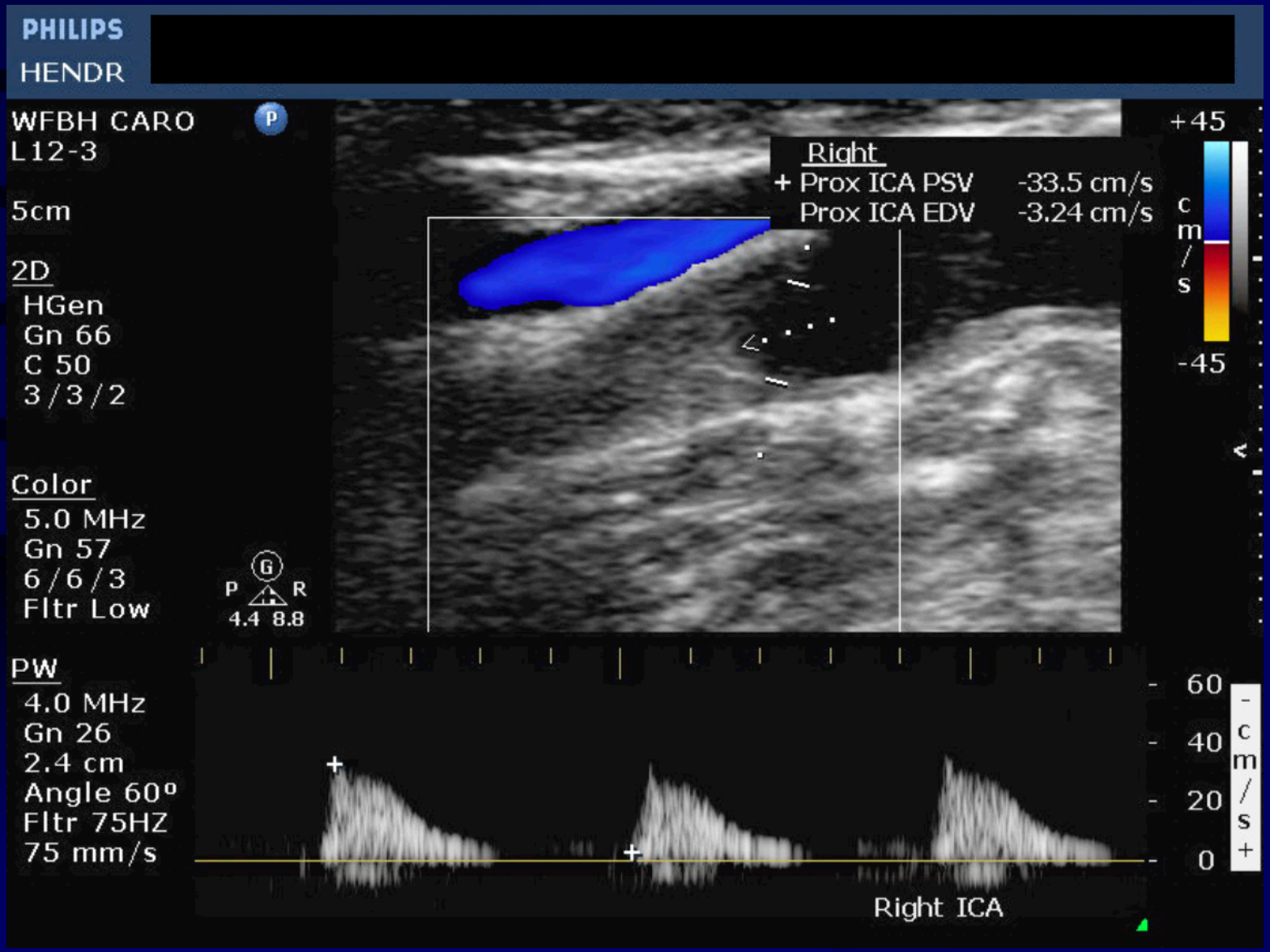

ICA Occlusion

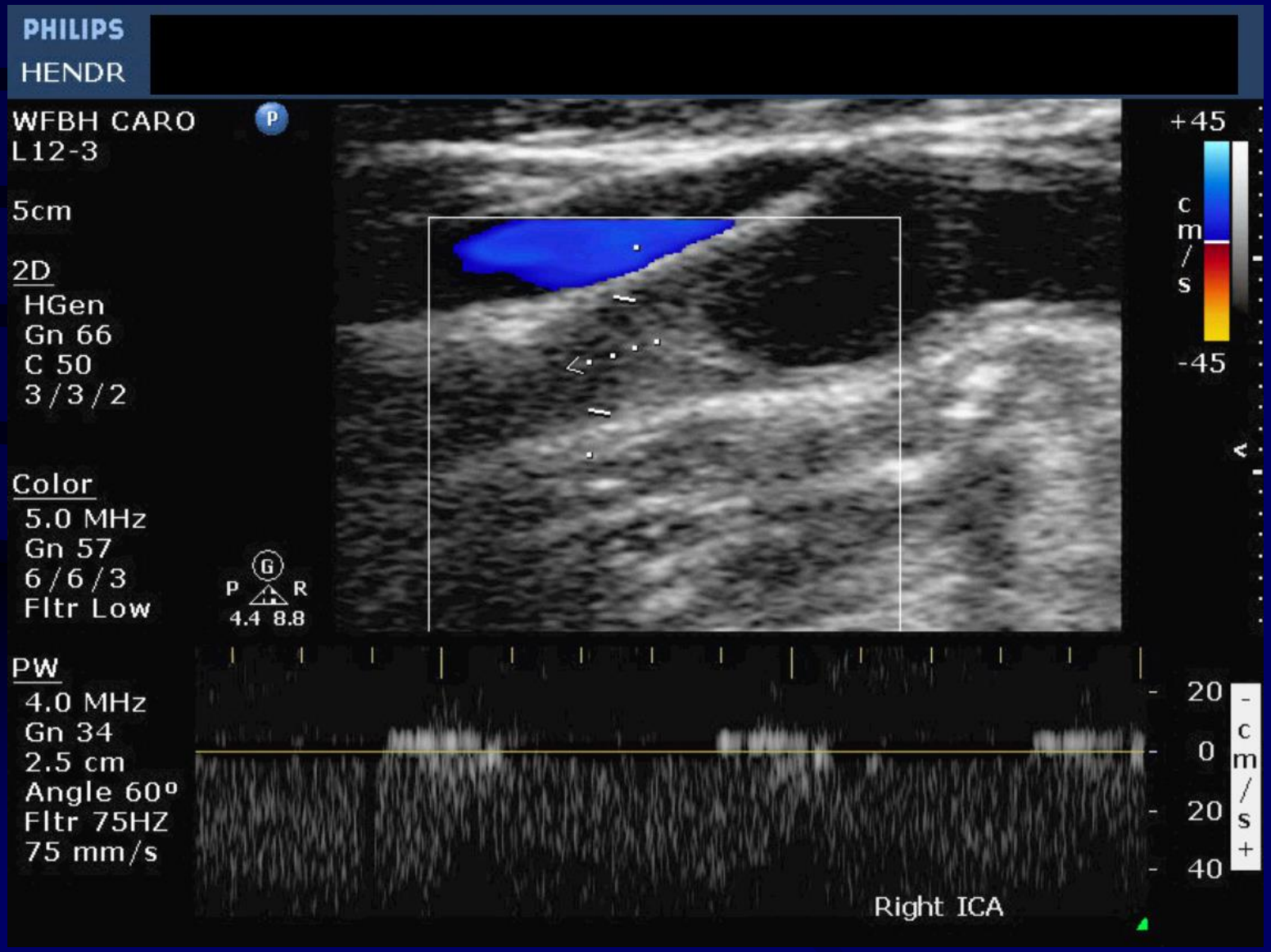

Small Caliber Distal ICA

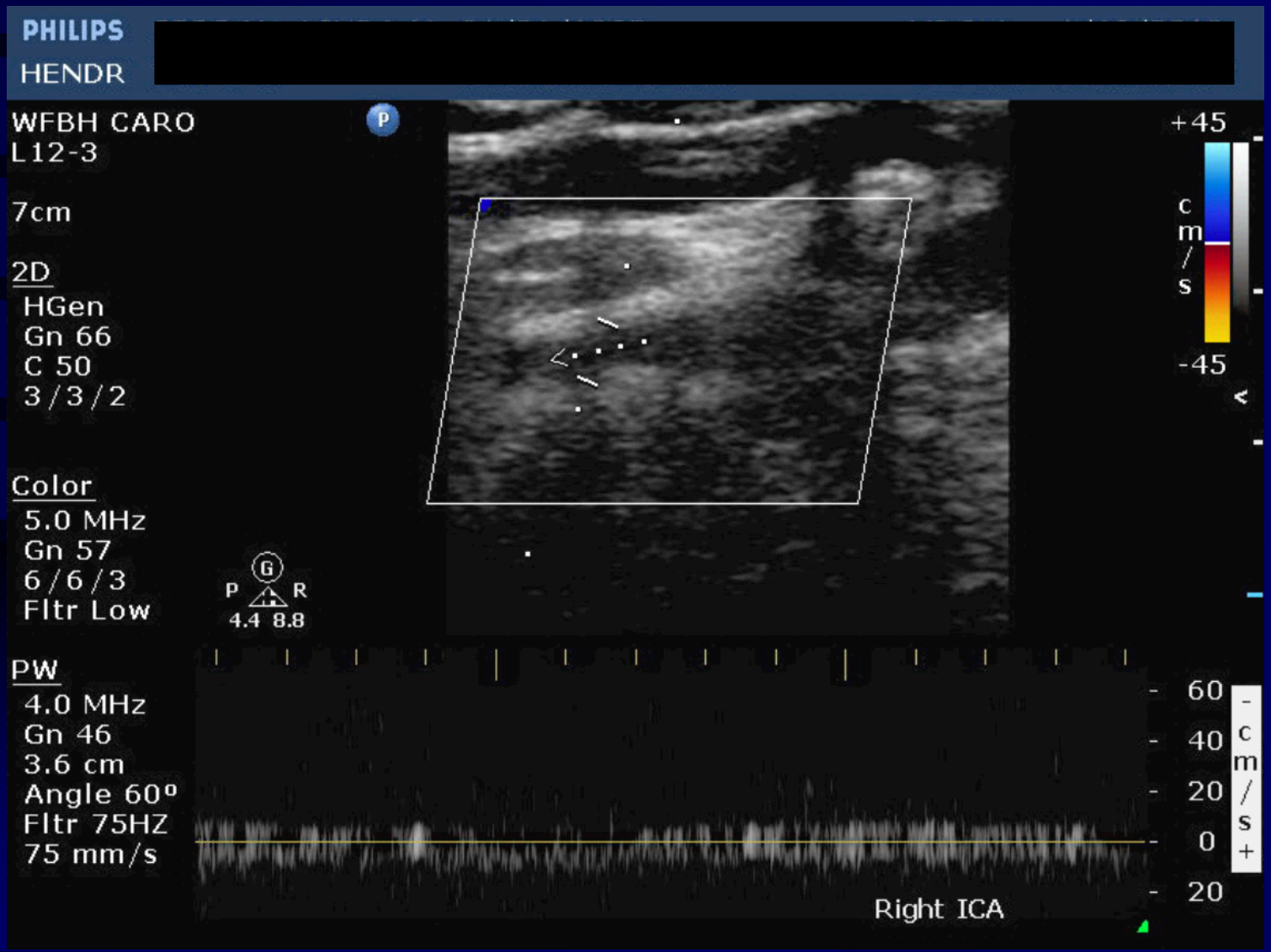

CCA Volume Flow

Distal Occlusion

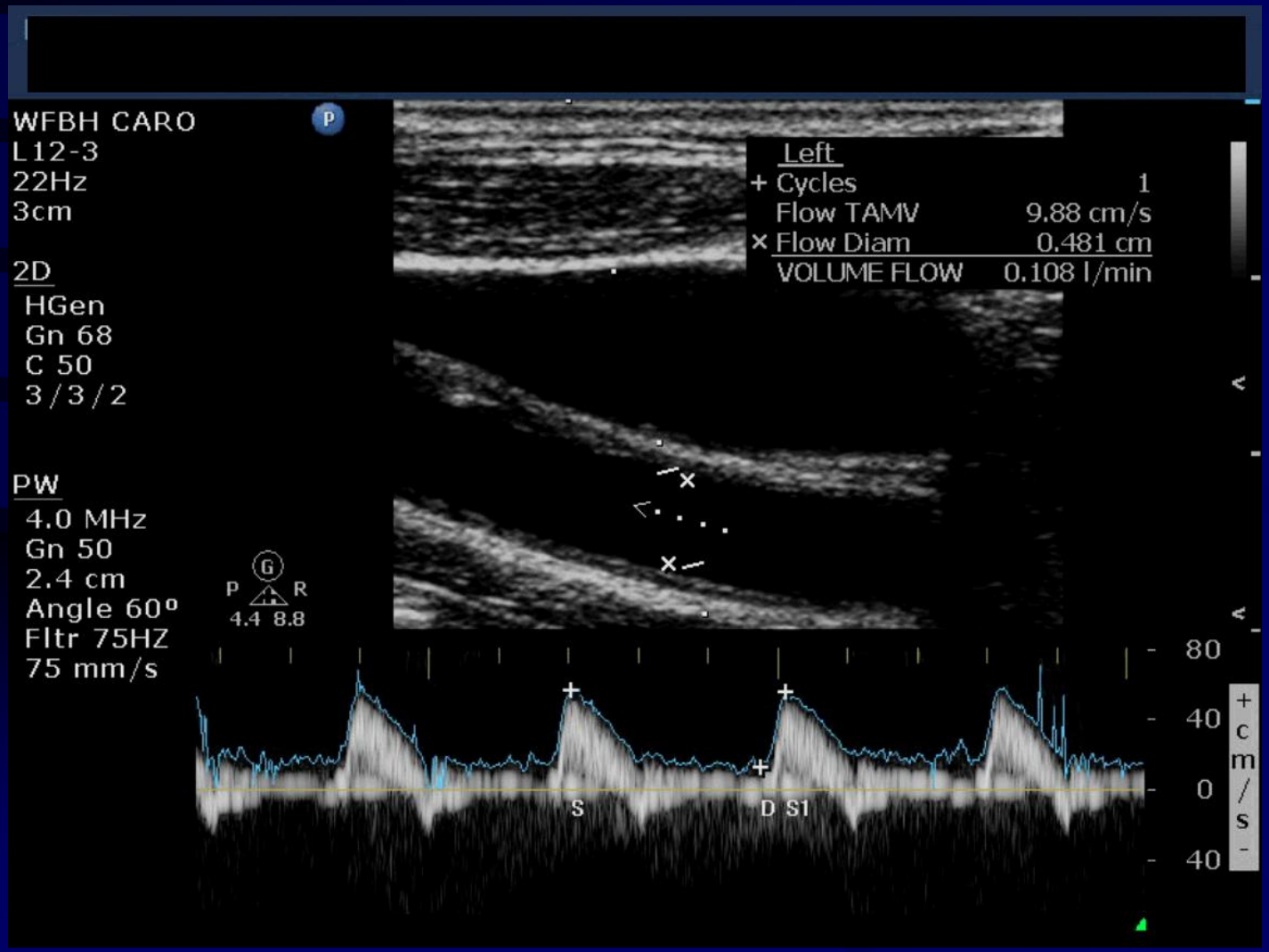

CCA Volume Flow
Opposite to Occlusion

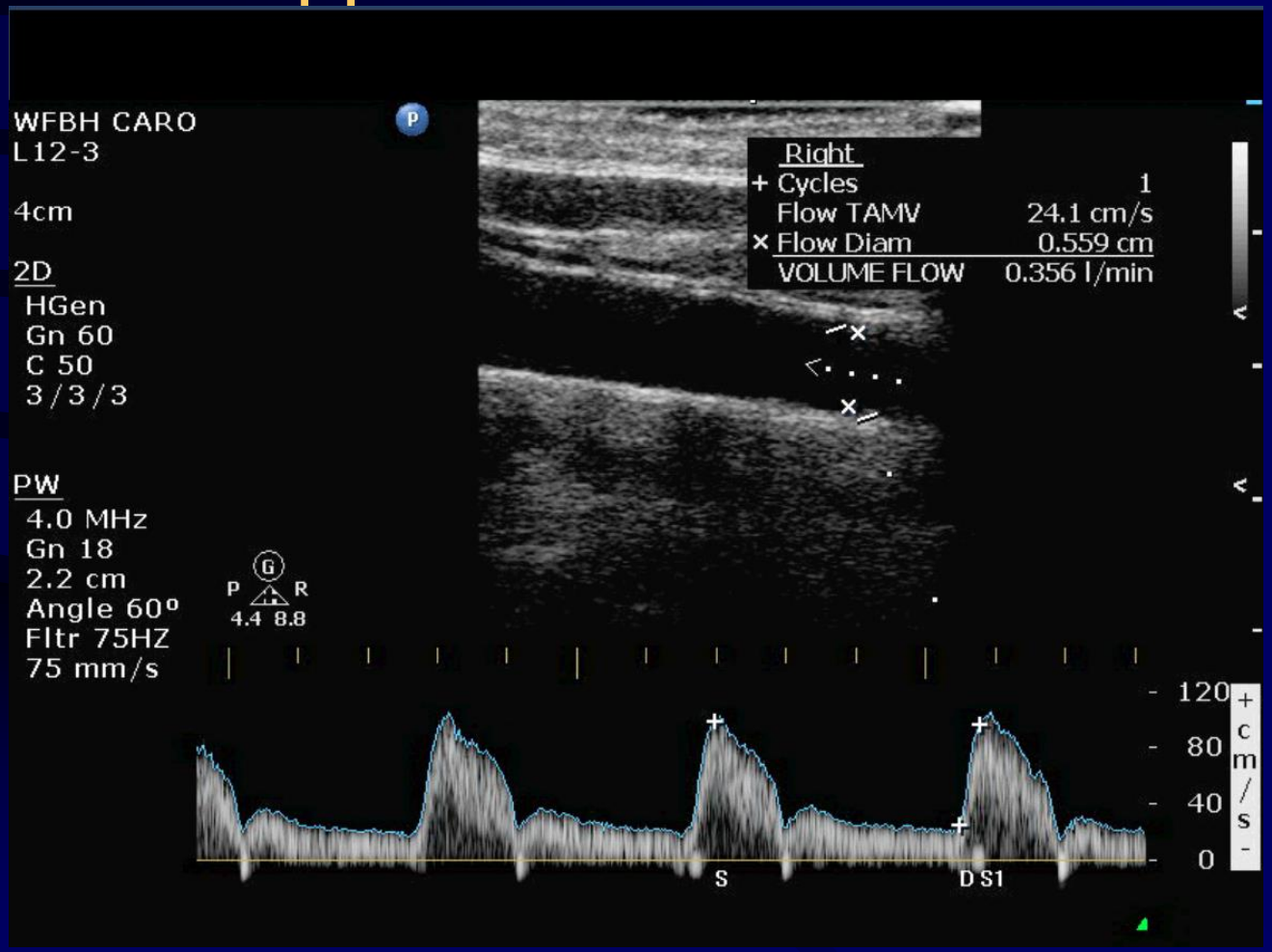

Carotid B-Mode Imaging

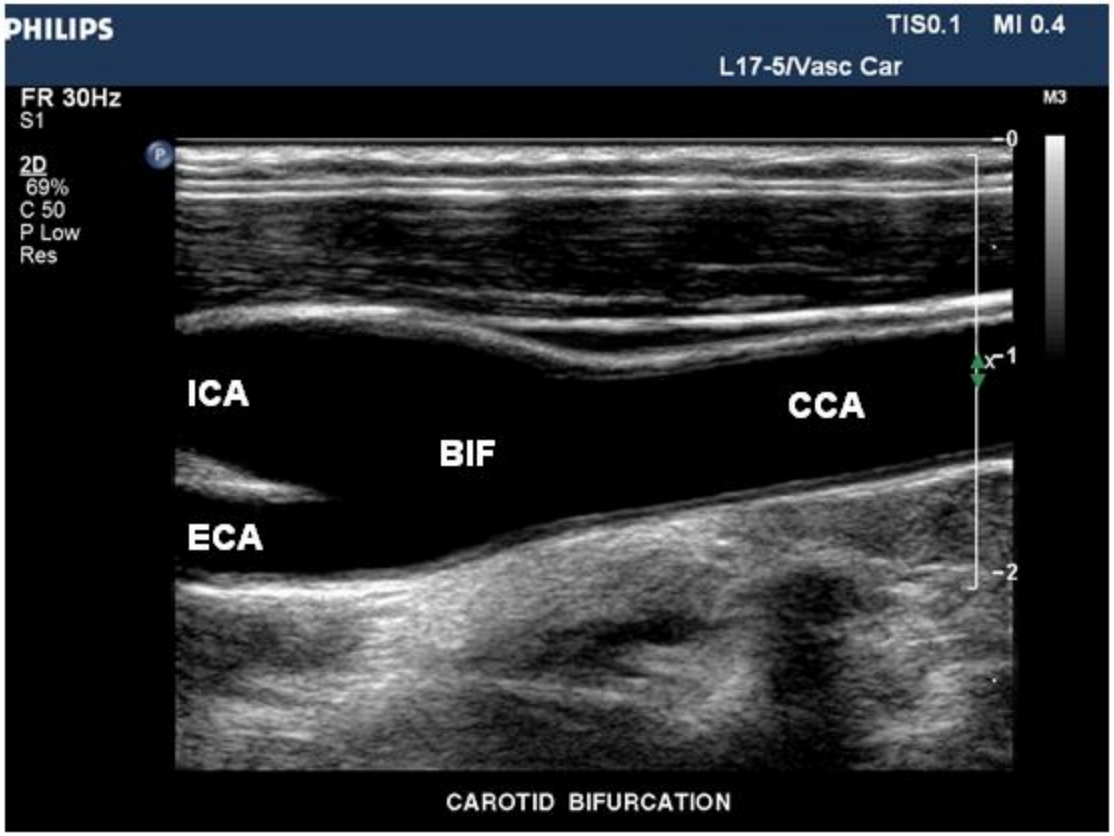

Carotid Protocol & Techniques

Key Elements of Protocol – B-mode

- B-mode imaging gives 2-D gray scale image of vessel, wall, plaque, & soft tissue
- Location, size, course of vessels
- Information on plaque features: location, thickness, surface (smooth, irregular, ulcer), texture (homogeneous/heterogeneous), echodensity, and any movement

Plaque Features:
Smooth and Homogeneous

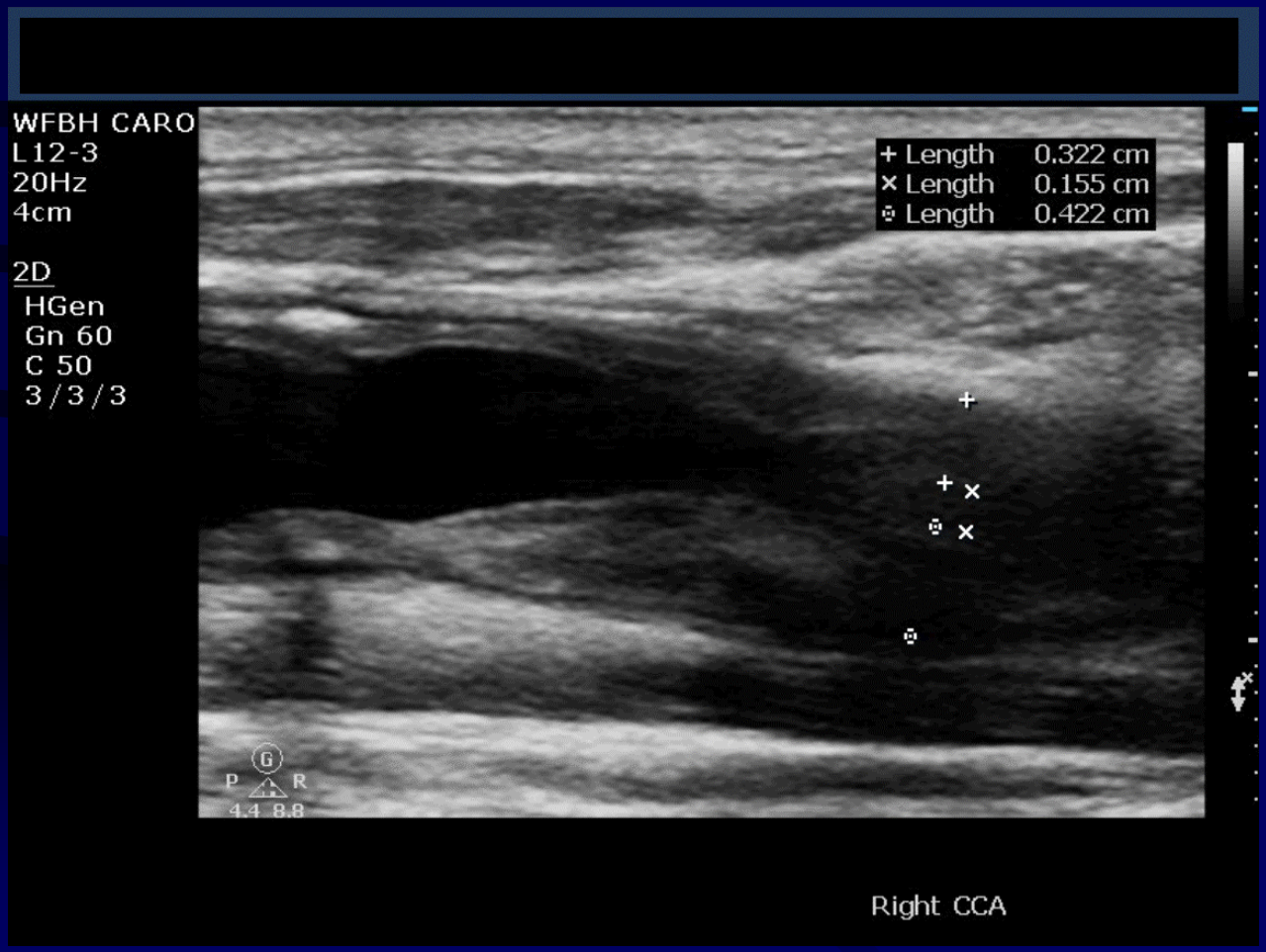

Irregular Plaque

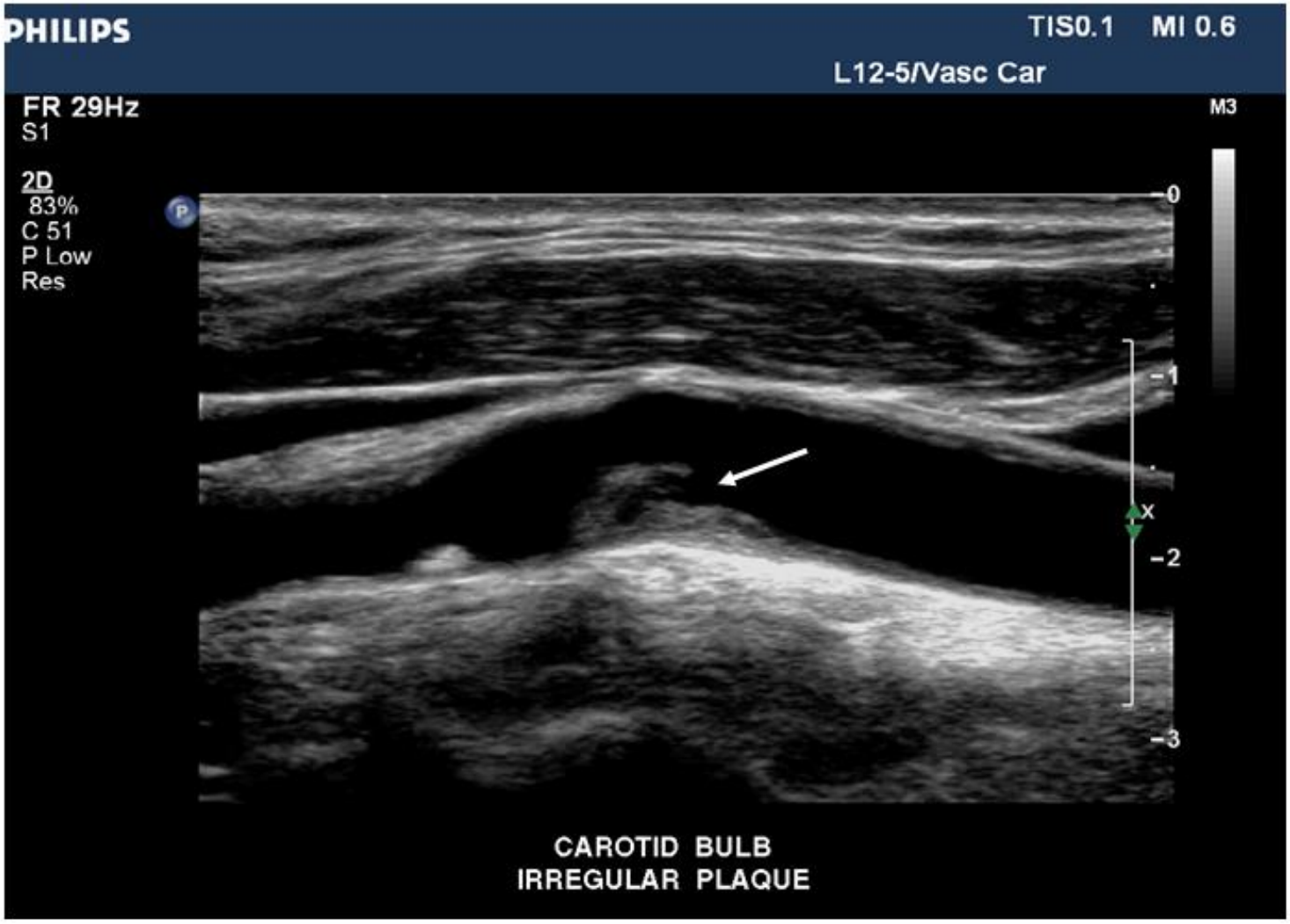

Calcification/Shadowing

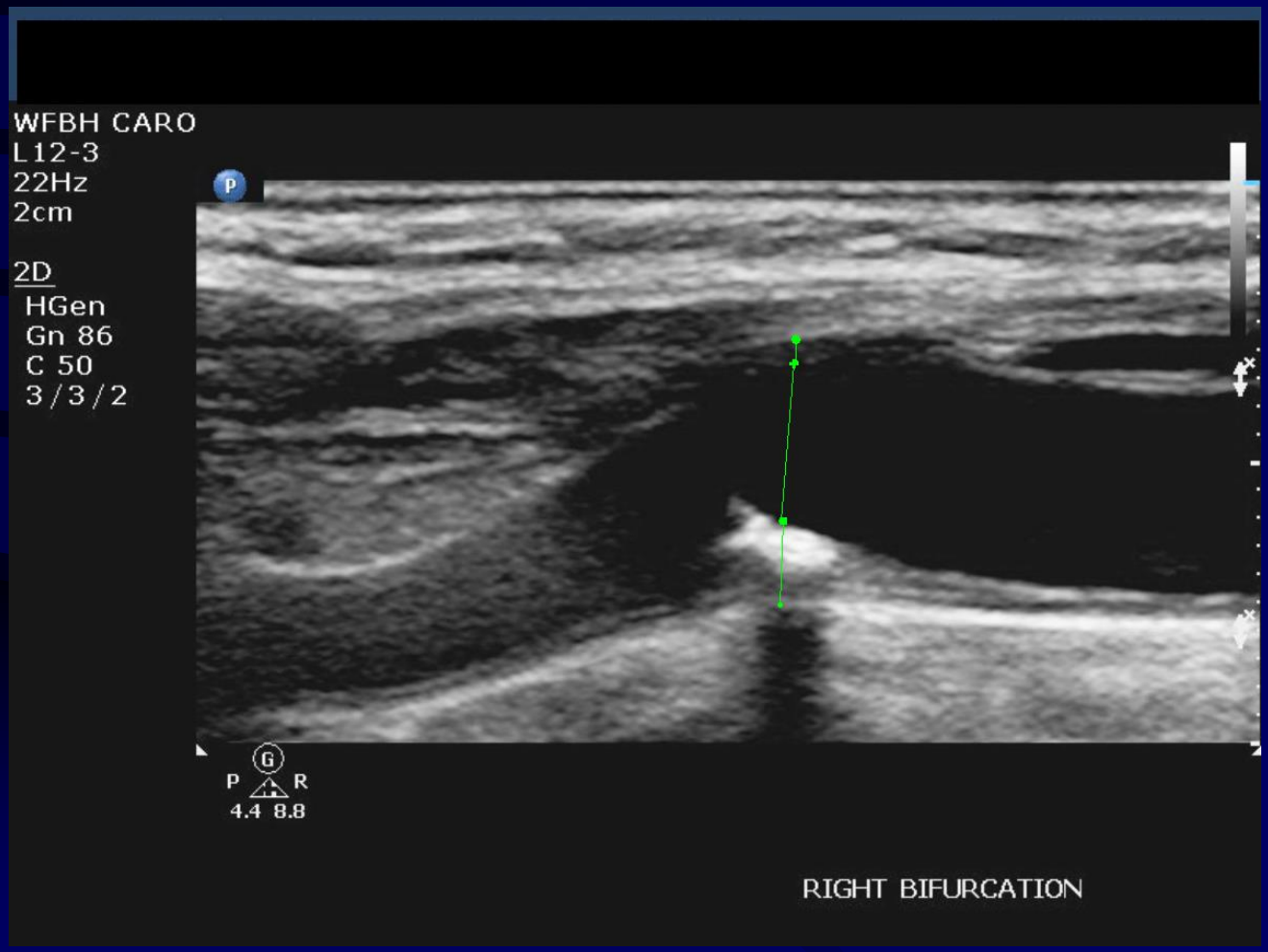

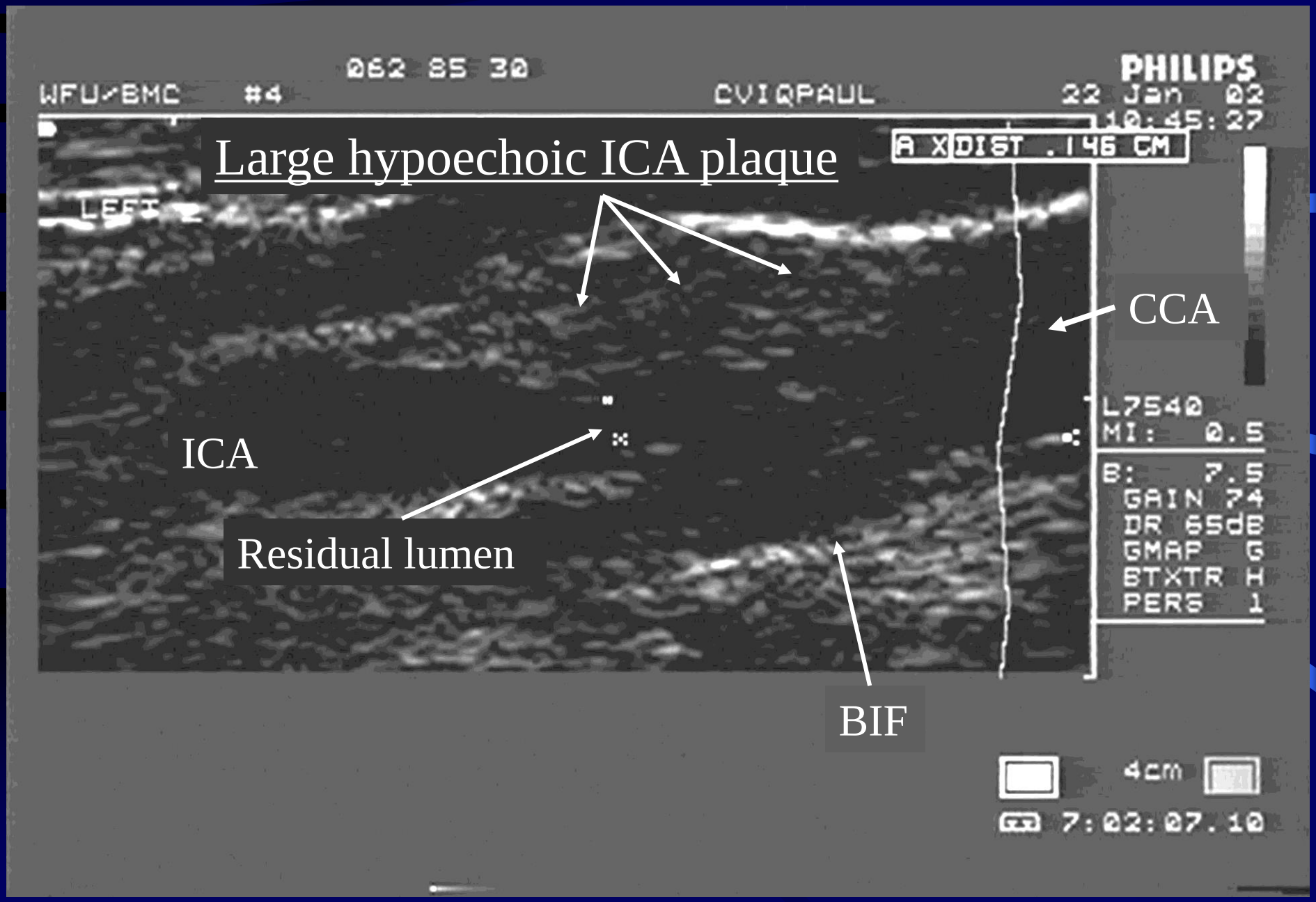
Large hypoechoic ICA plaque
CCA
ICA
Residual lumen
BIF
WFU/BMC #4
062 85 30
CVIQPAUL
PHILIPS
22 Jan 02
10:45:27
A X DIST .146 CM
LEFT
L7540
MI: 0.5
B: 7.5
GAIN 74
DR 65dB
GMAP G
BTXTR H
PERS 1
4cm
7:02:07.10

Plaque Features:
Hypoechoic region/? IPH

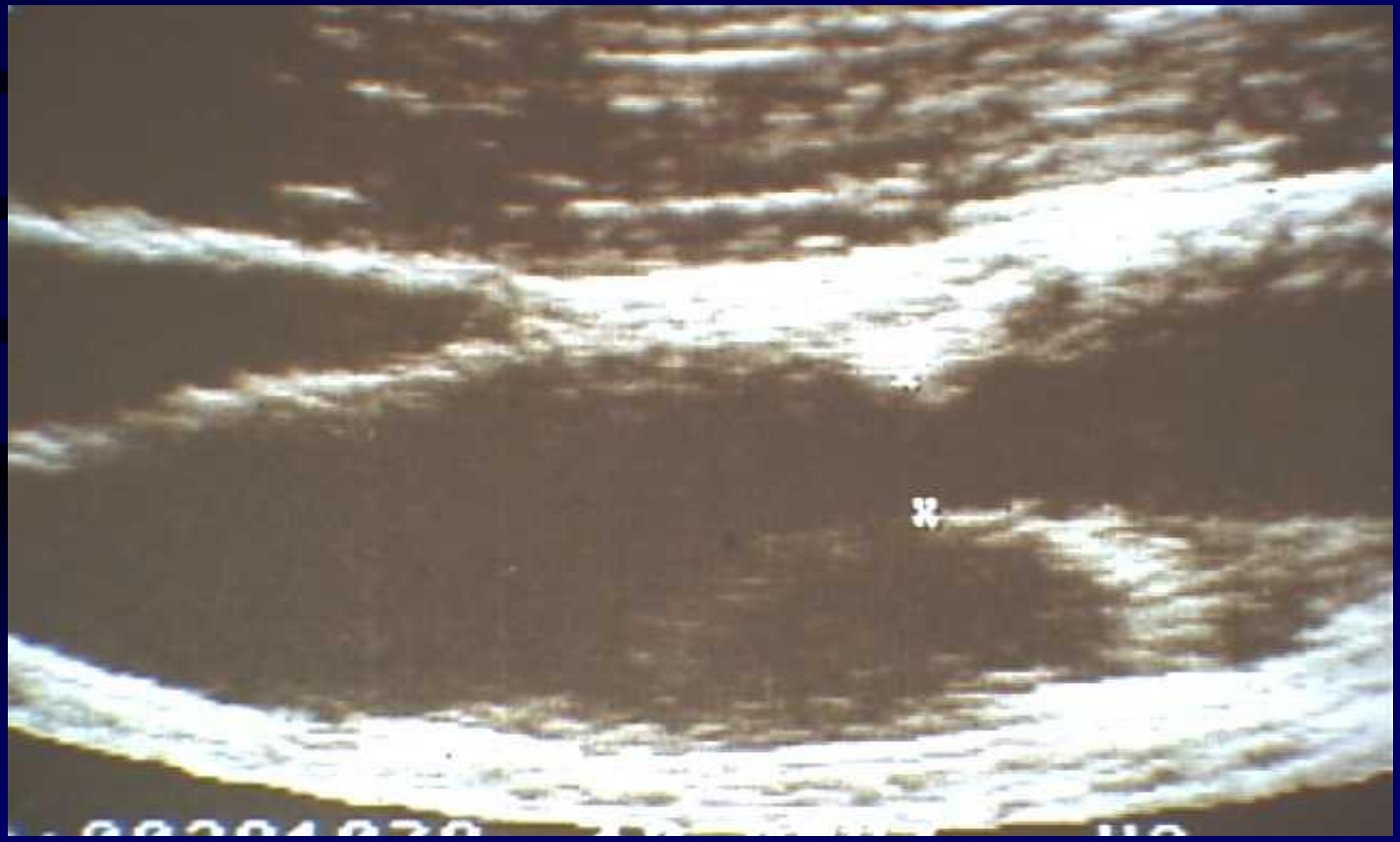

Complex Plaque ICA

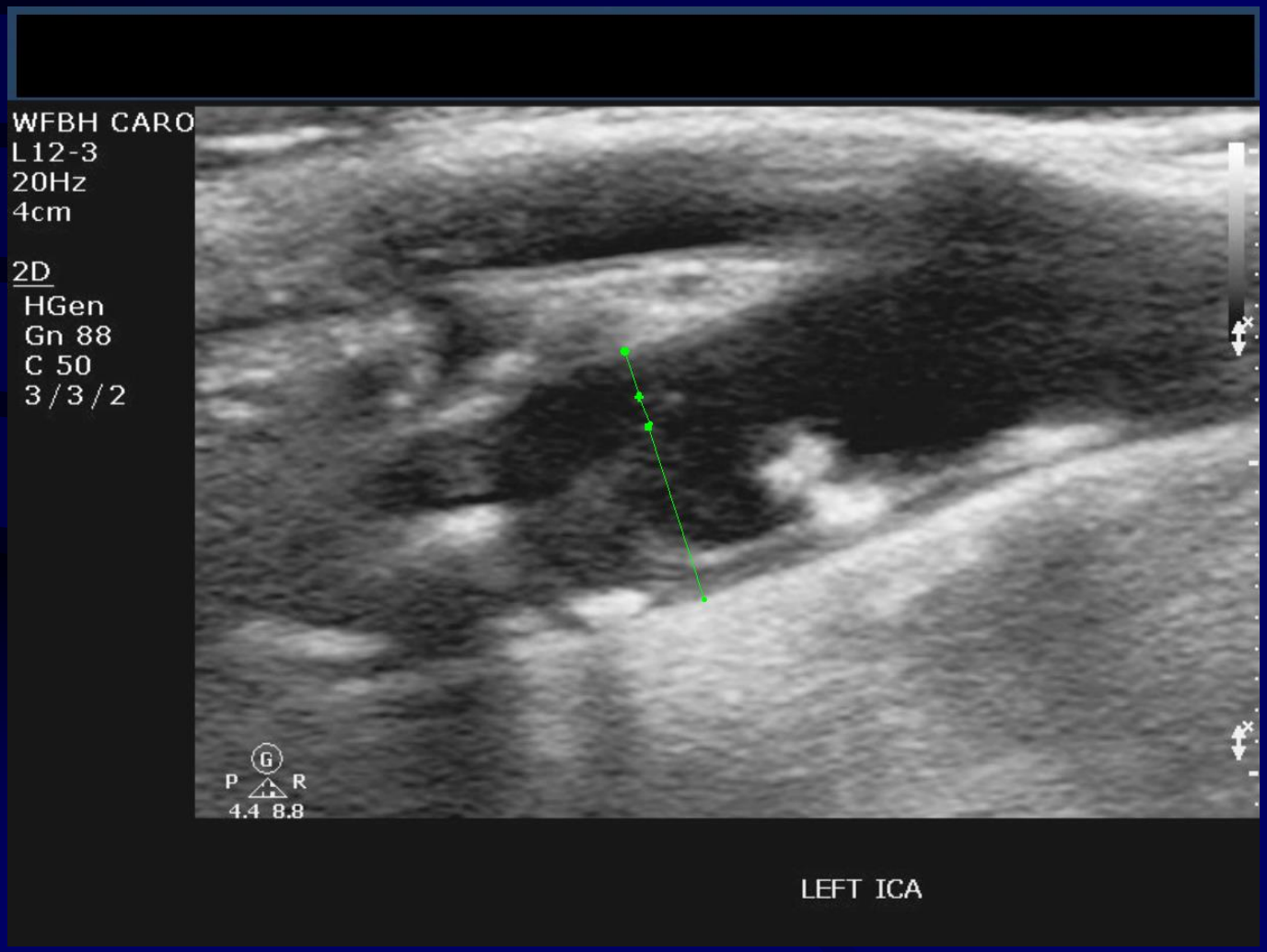

Thrombosis/Occlusion of ICA

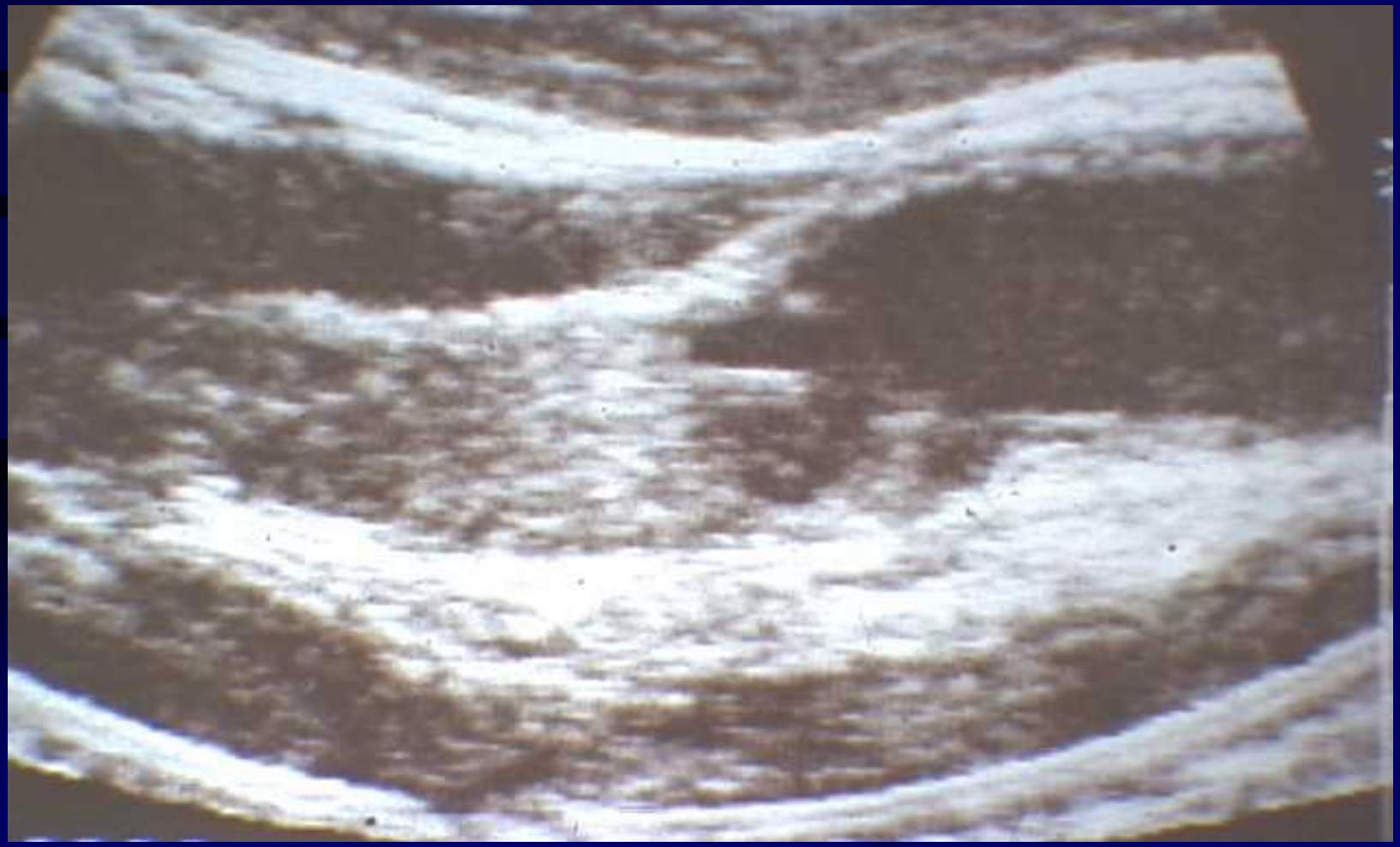

Mobile Thrombus

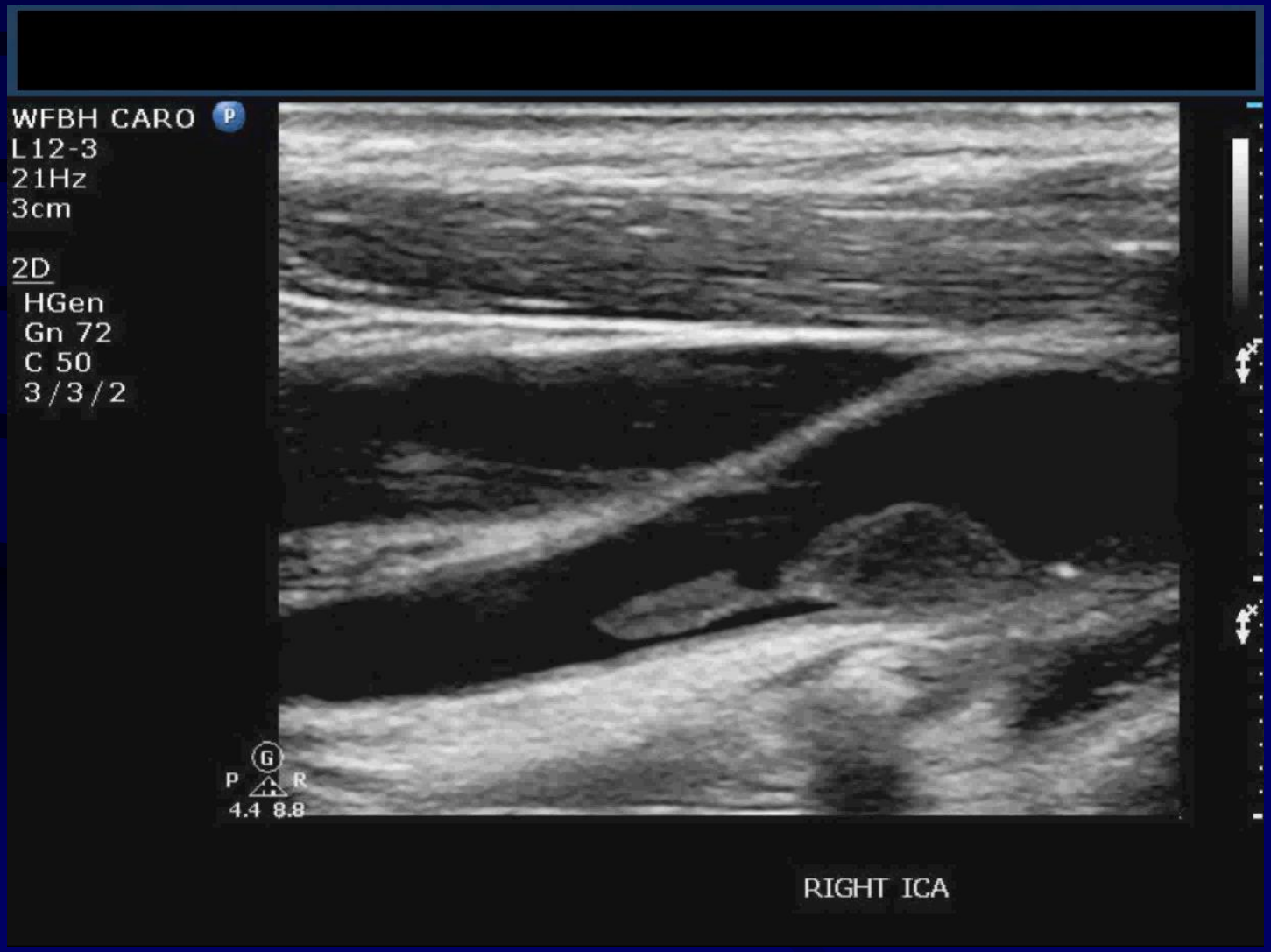

Longitudinal Pulsation

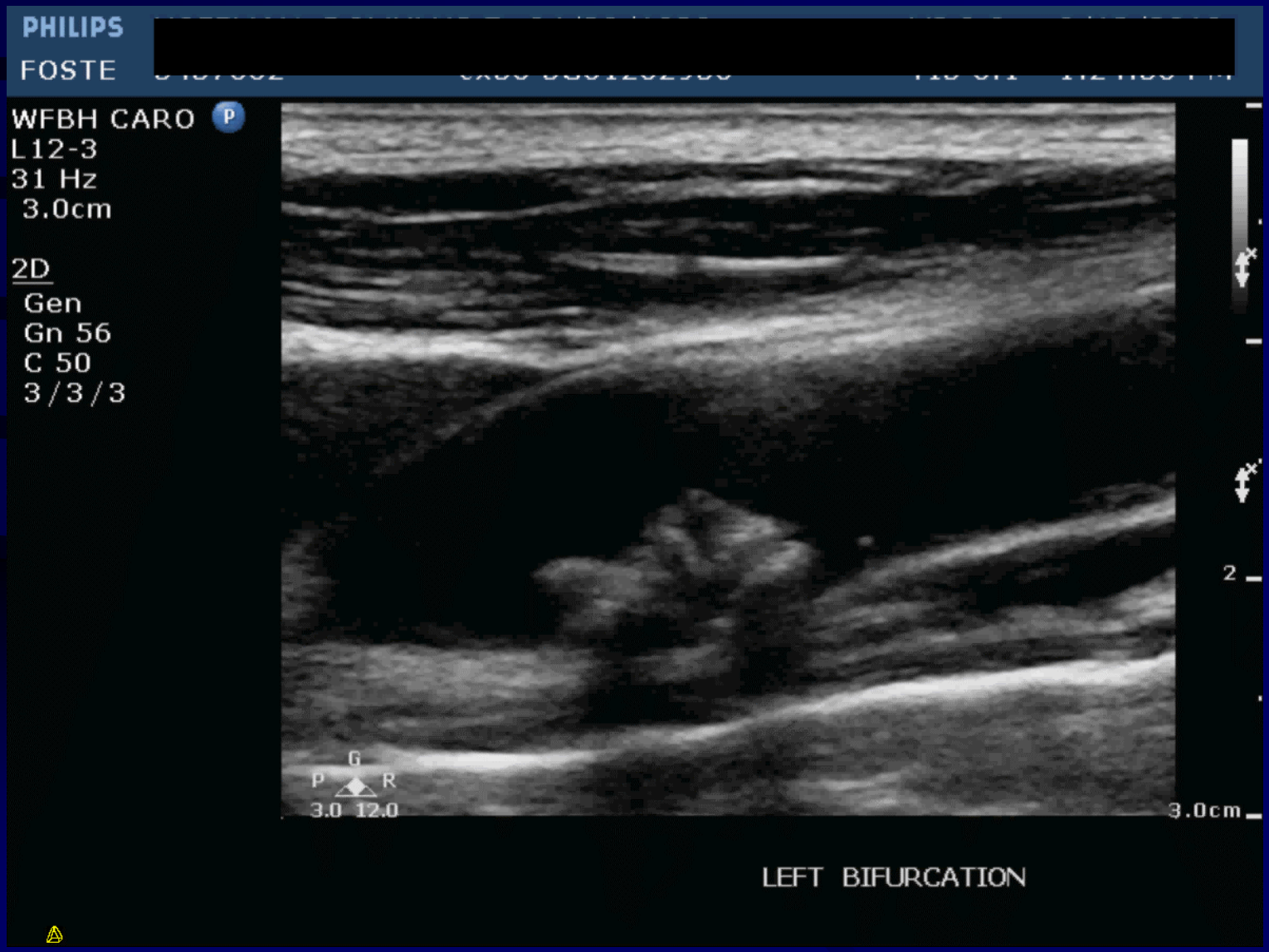

Mobile Lesion Distal CCA

6 months before stroke

Mobile Lesion Distal CCA

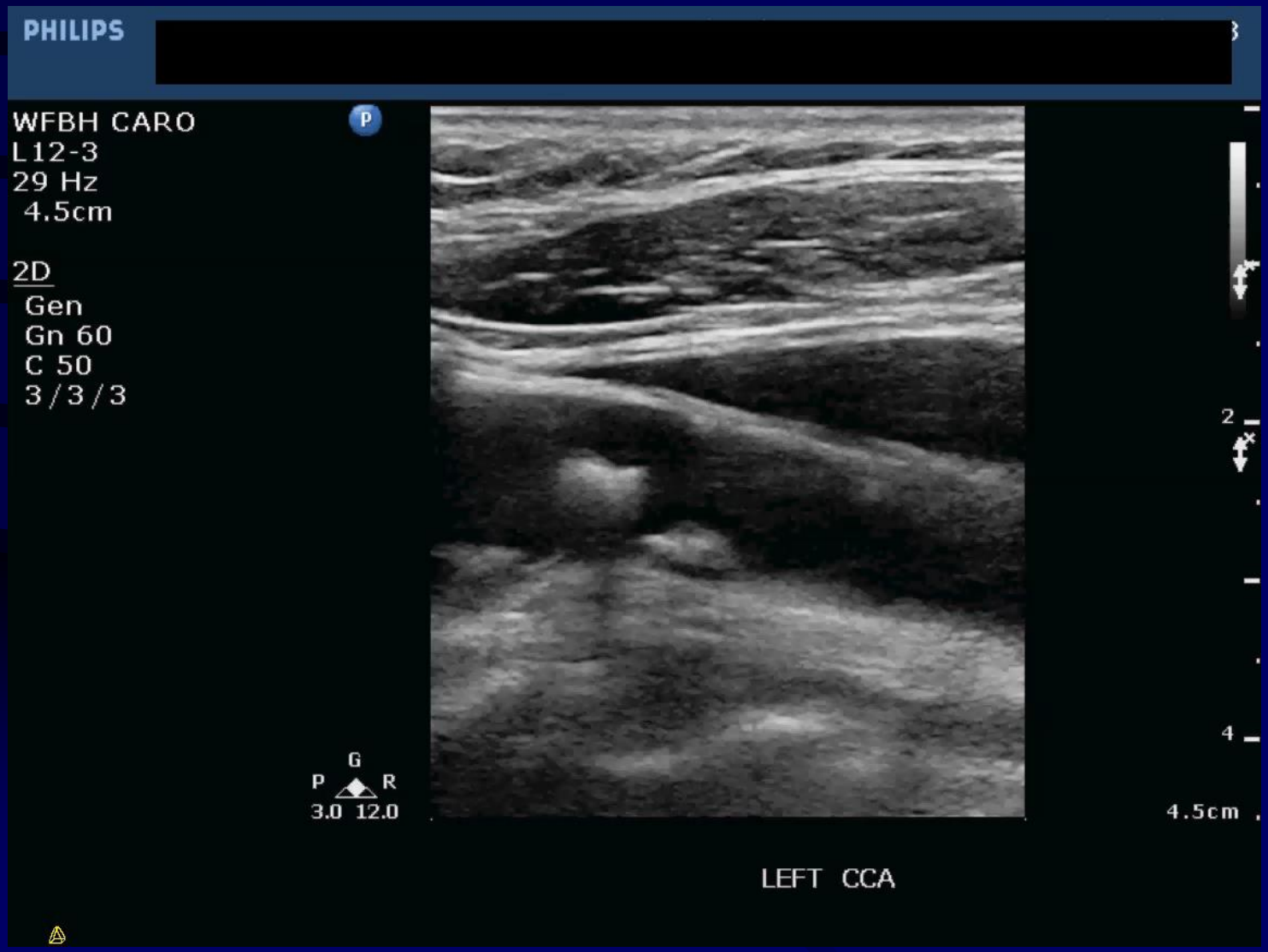

Transverse View

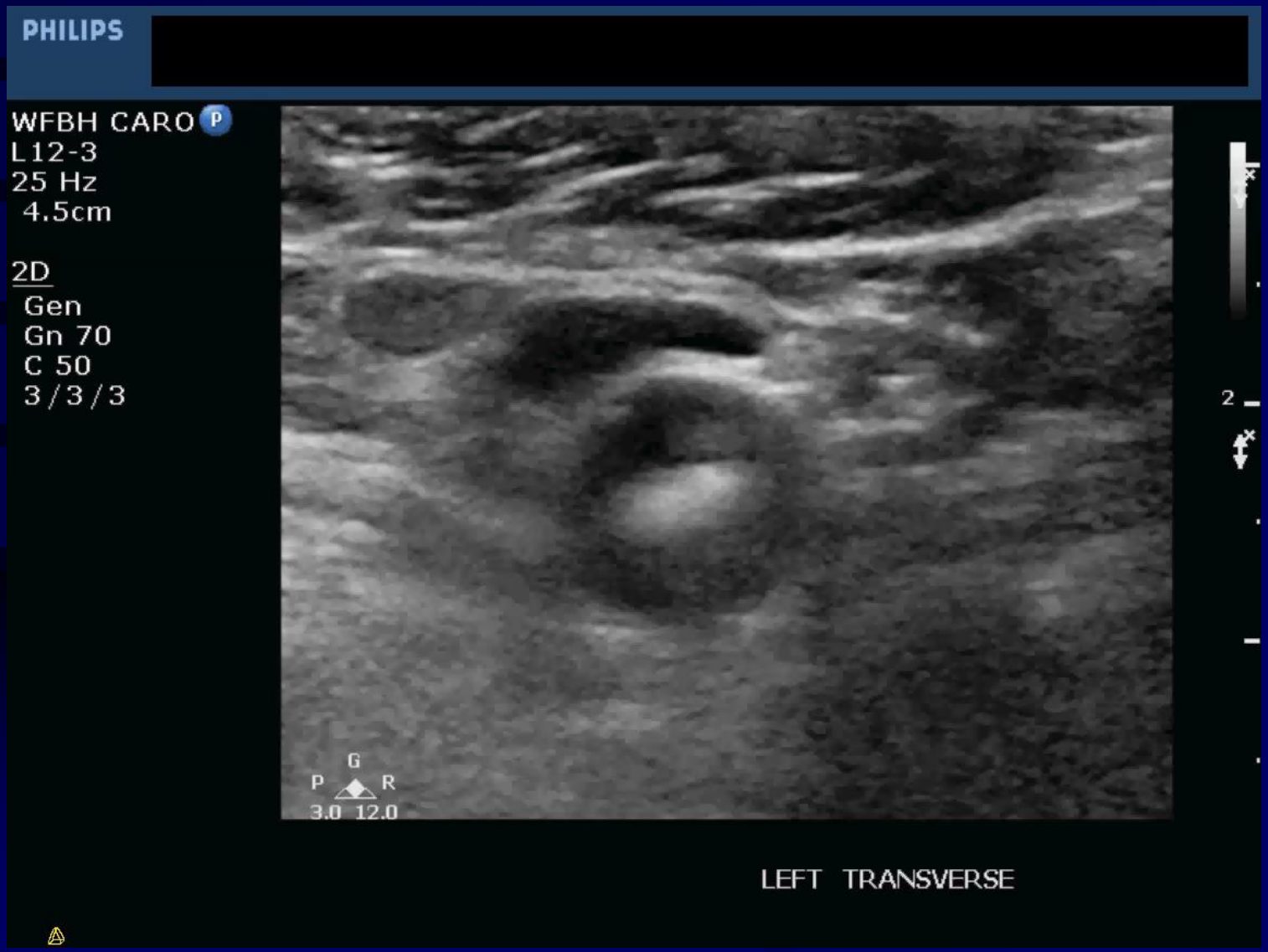

CCA Dissection

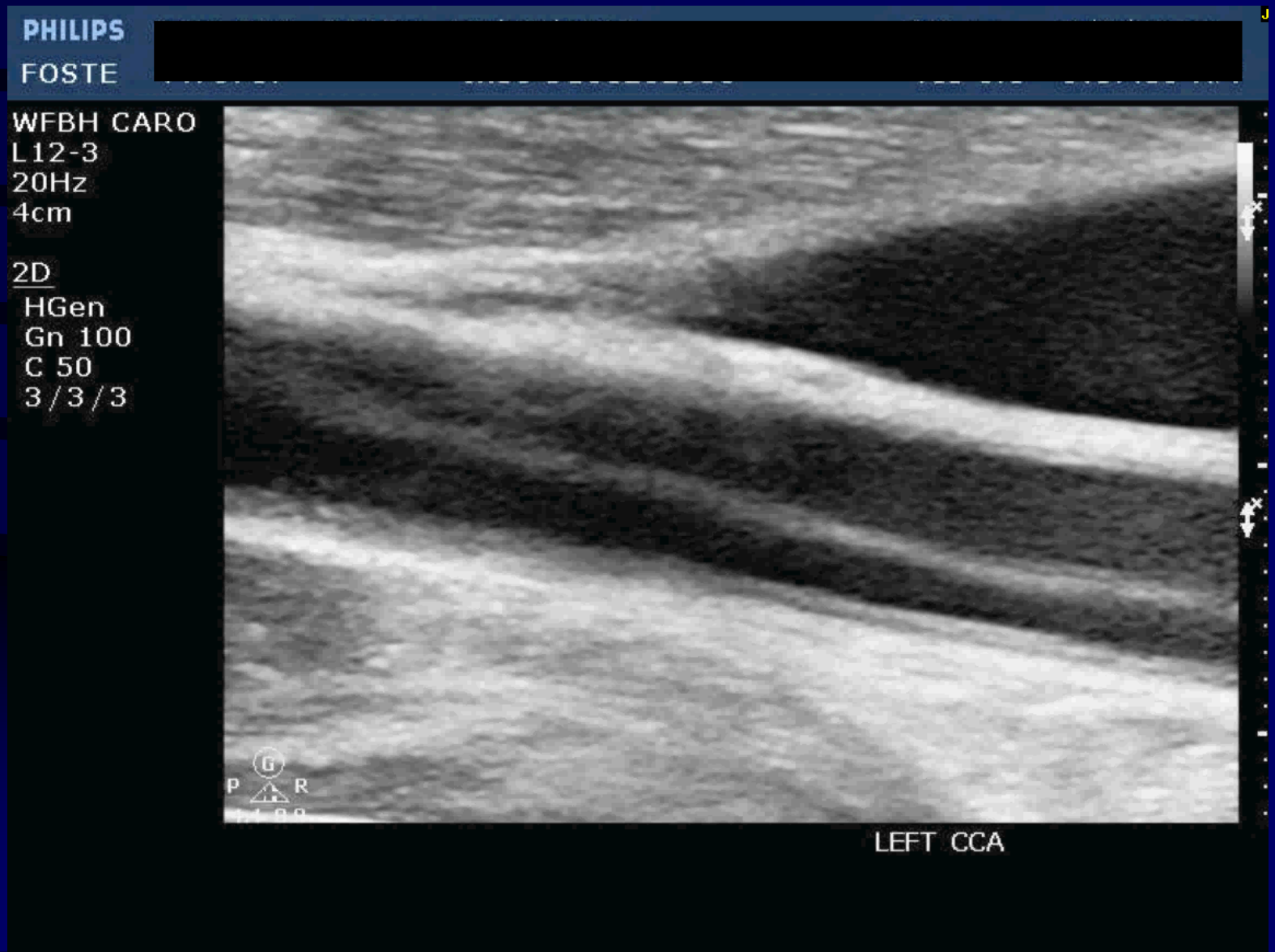

Distal CCA Dissection

ICA Dissection

Caution Side Wall Plaque

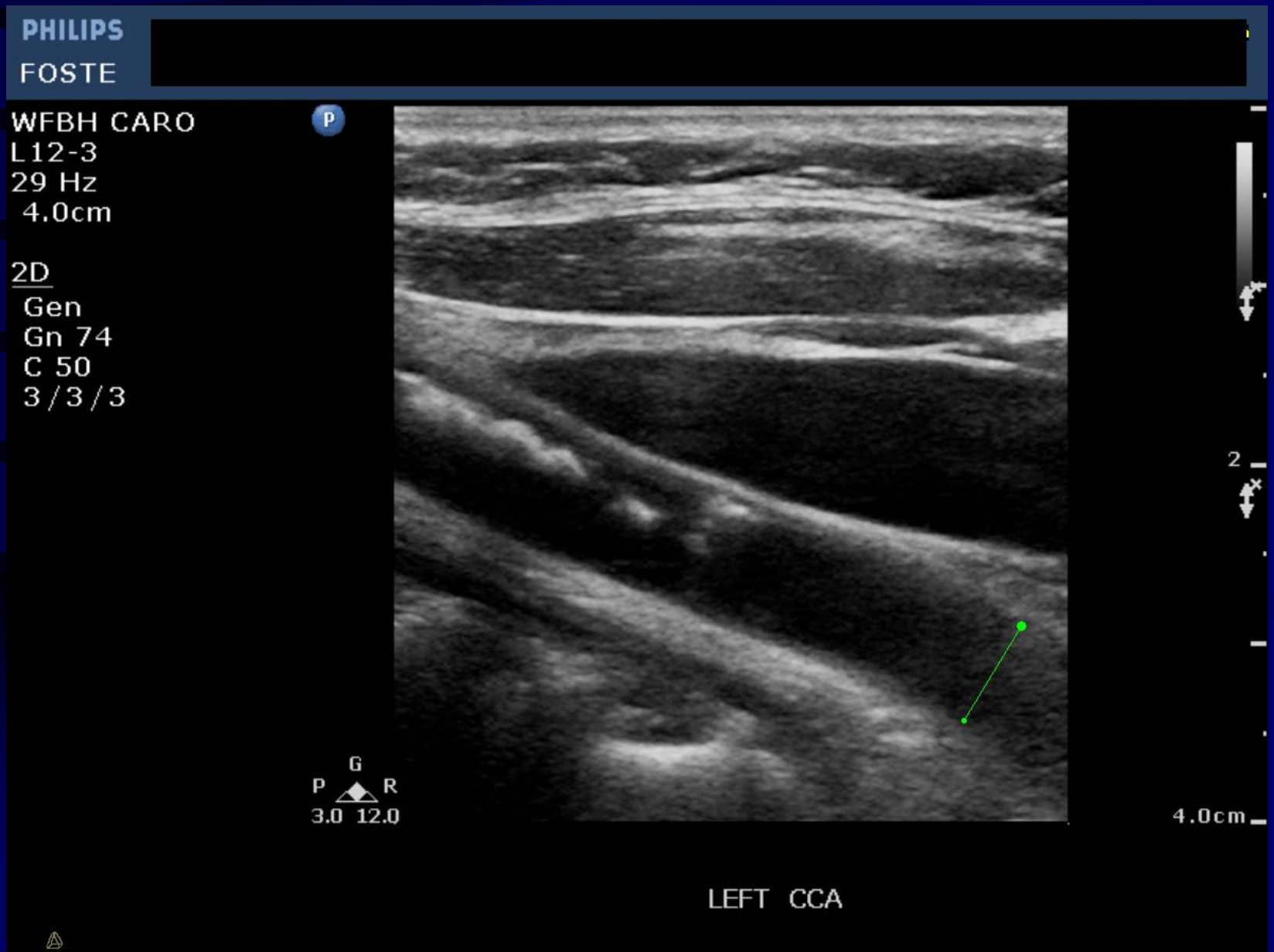

Transverse Truth

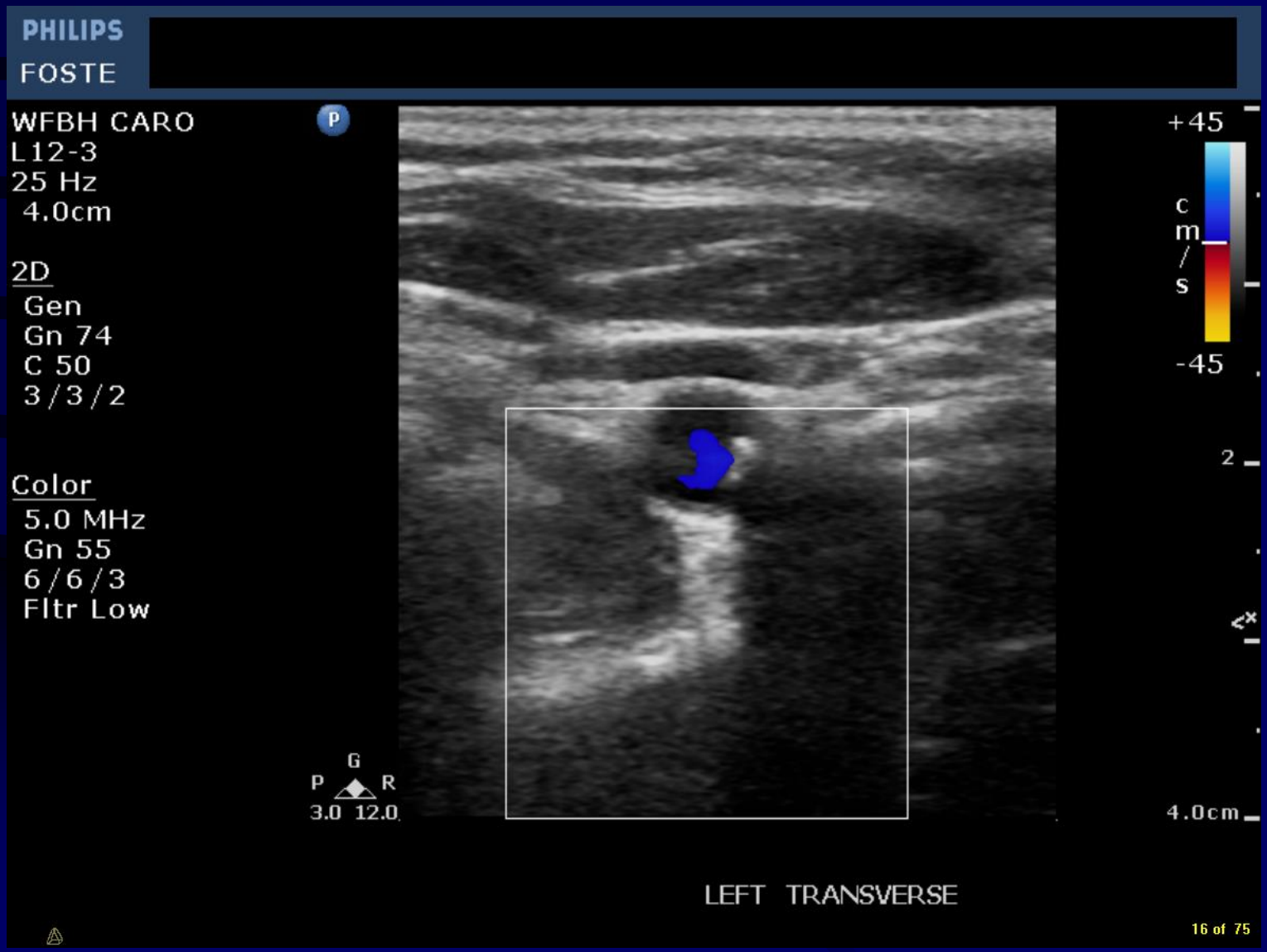

Prior CEA Suture Line

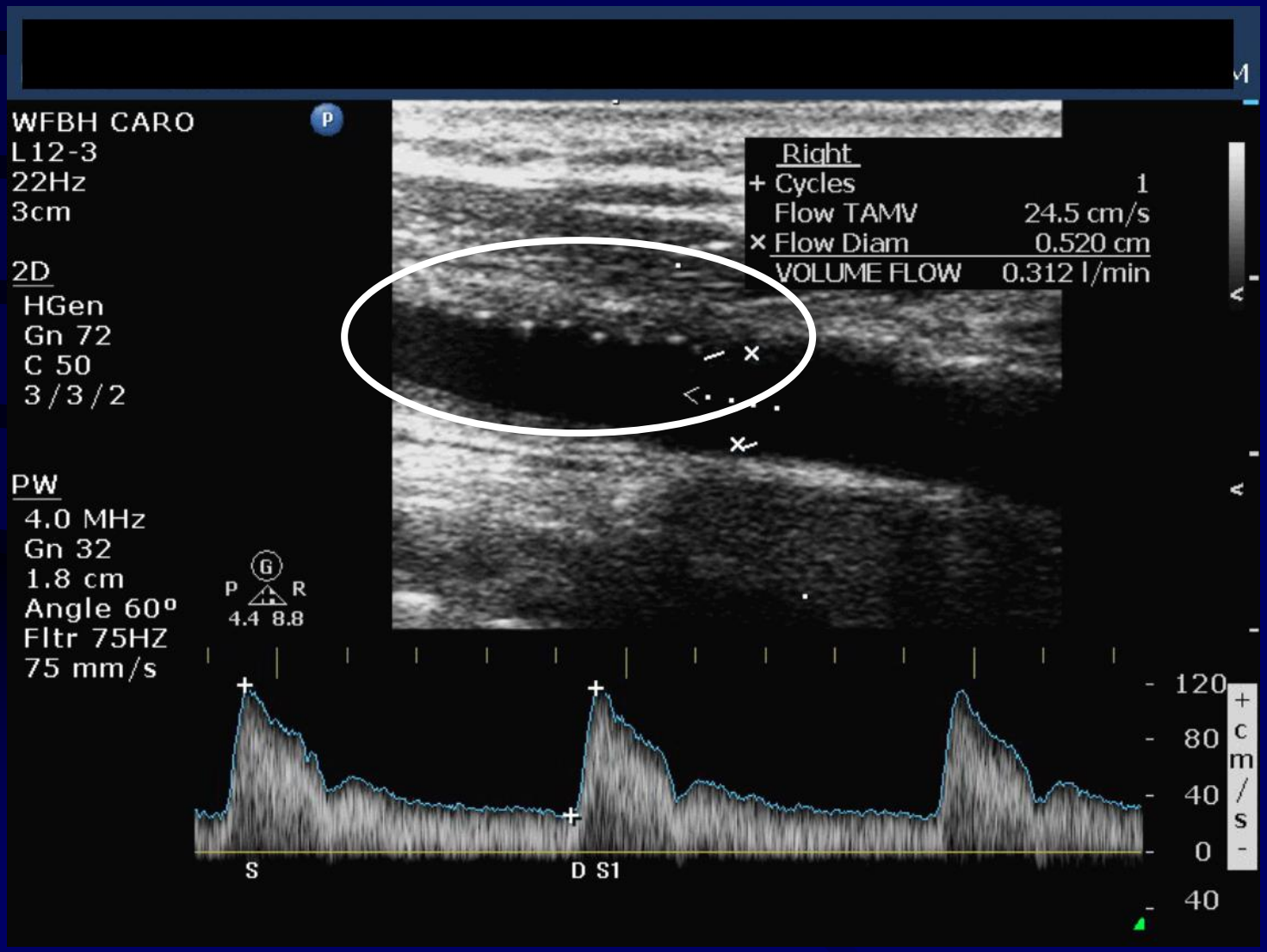

Typical Take-off of Superior Thyroidal

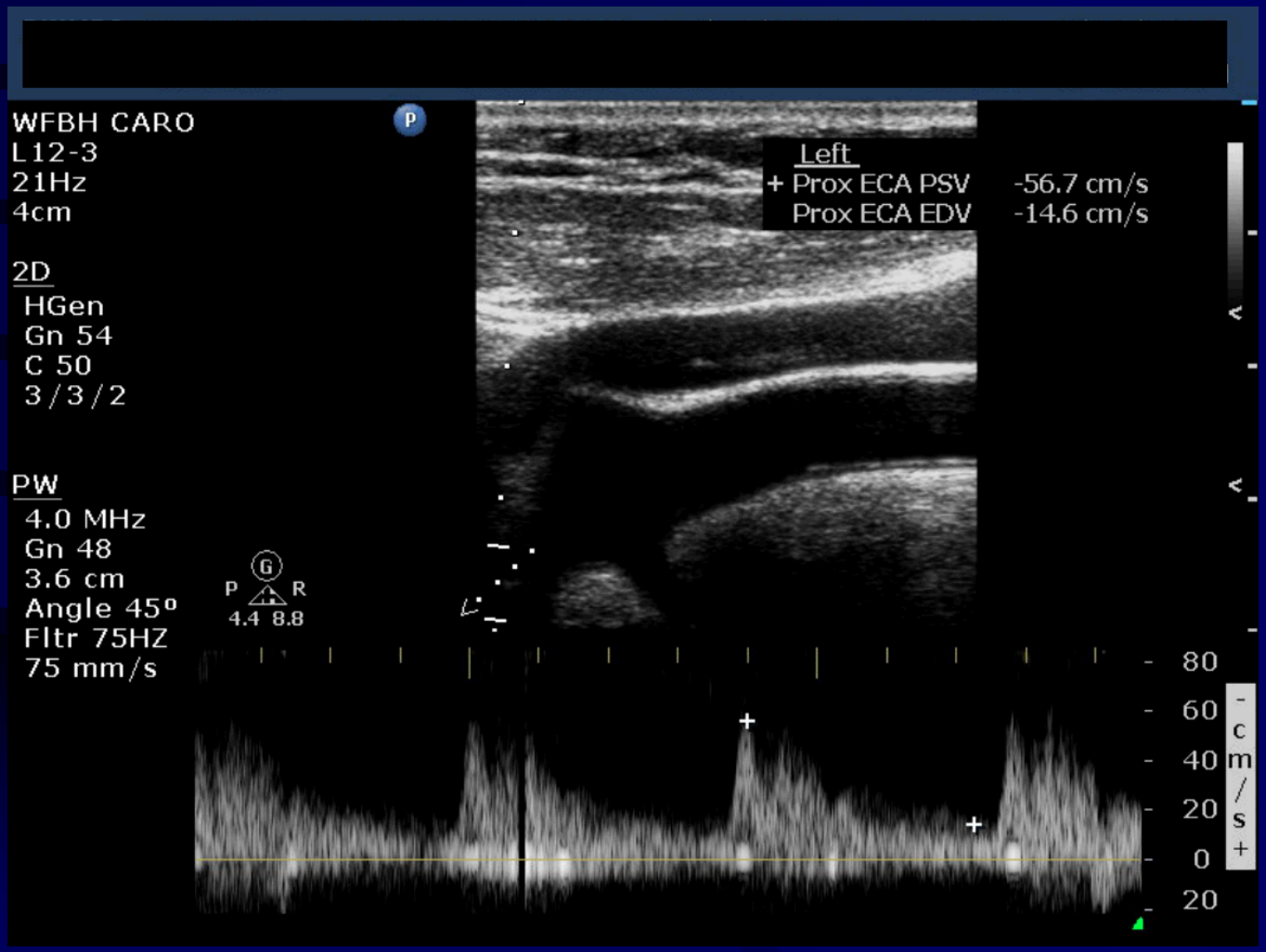

Low Take-Off of Superior Thyroidal Artery

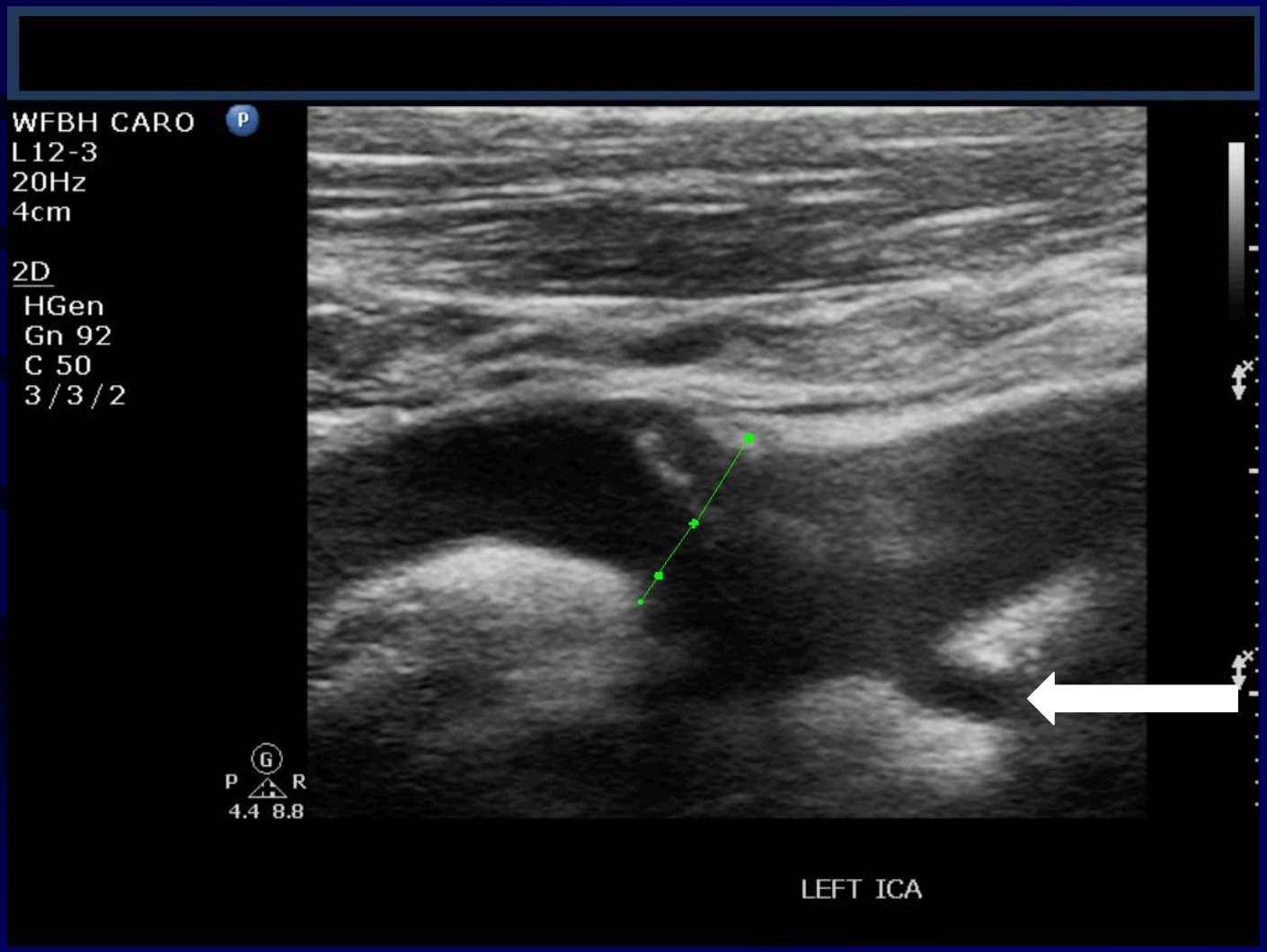

Distal Take-off of Superior Thyroidal

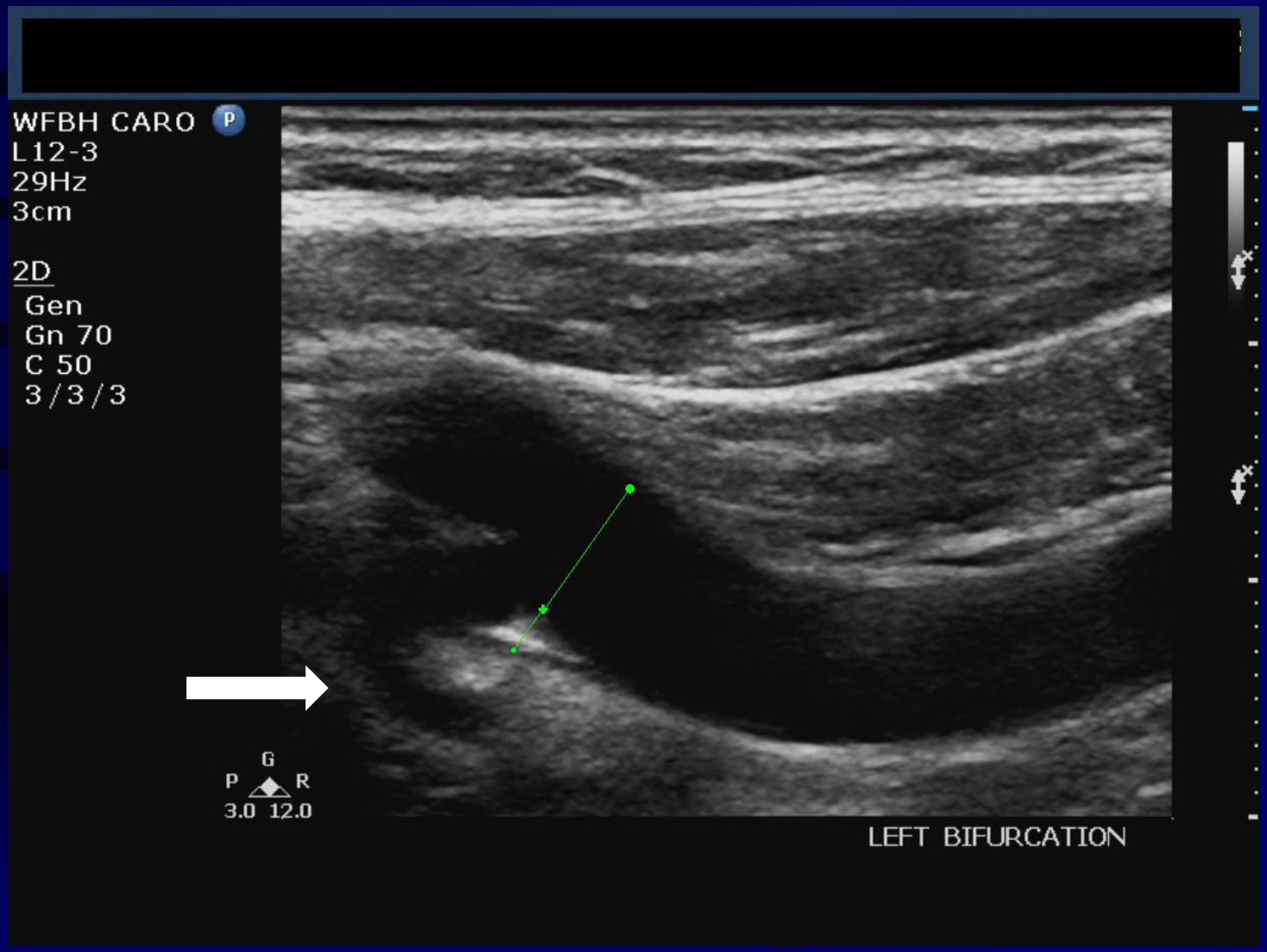

Distal CCA Cut-off from Prior CEA

Abrupt CCA Cut-off From Prior CEA

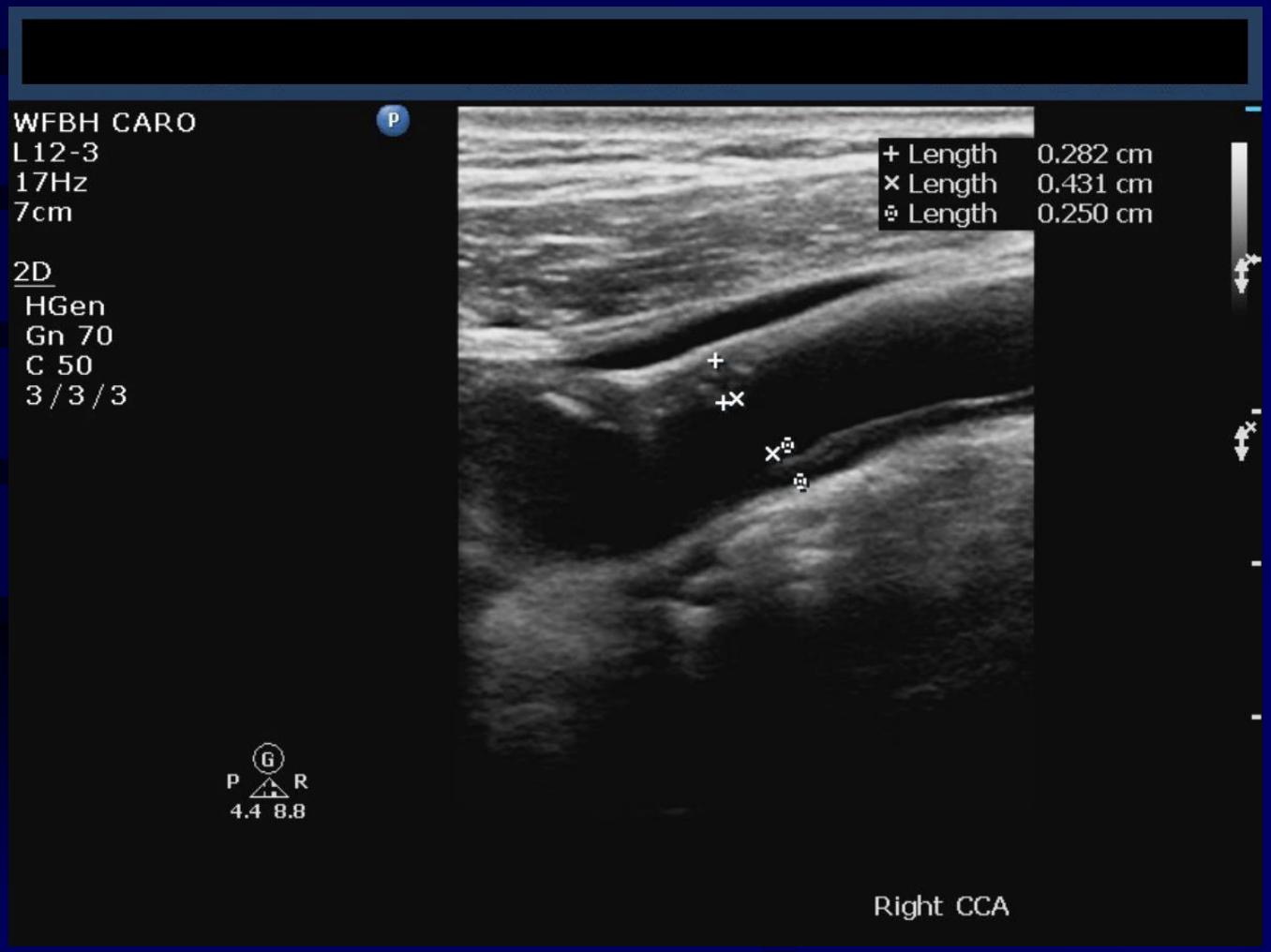

Dacron Patch Graft ICA Post-CEA

Dacron Patch Graft Post-CEA

Proximal, Transverse, with Plaque

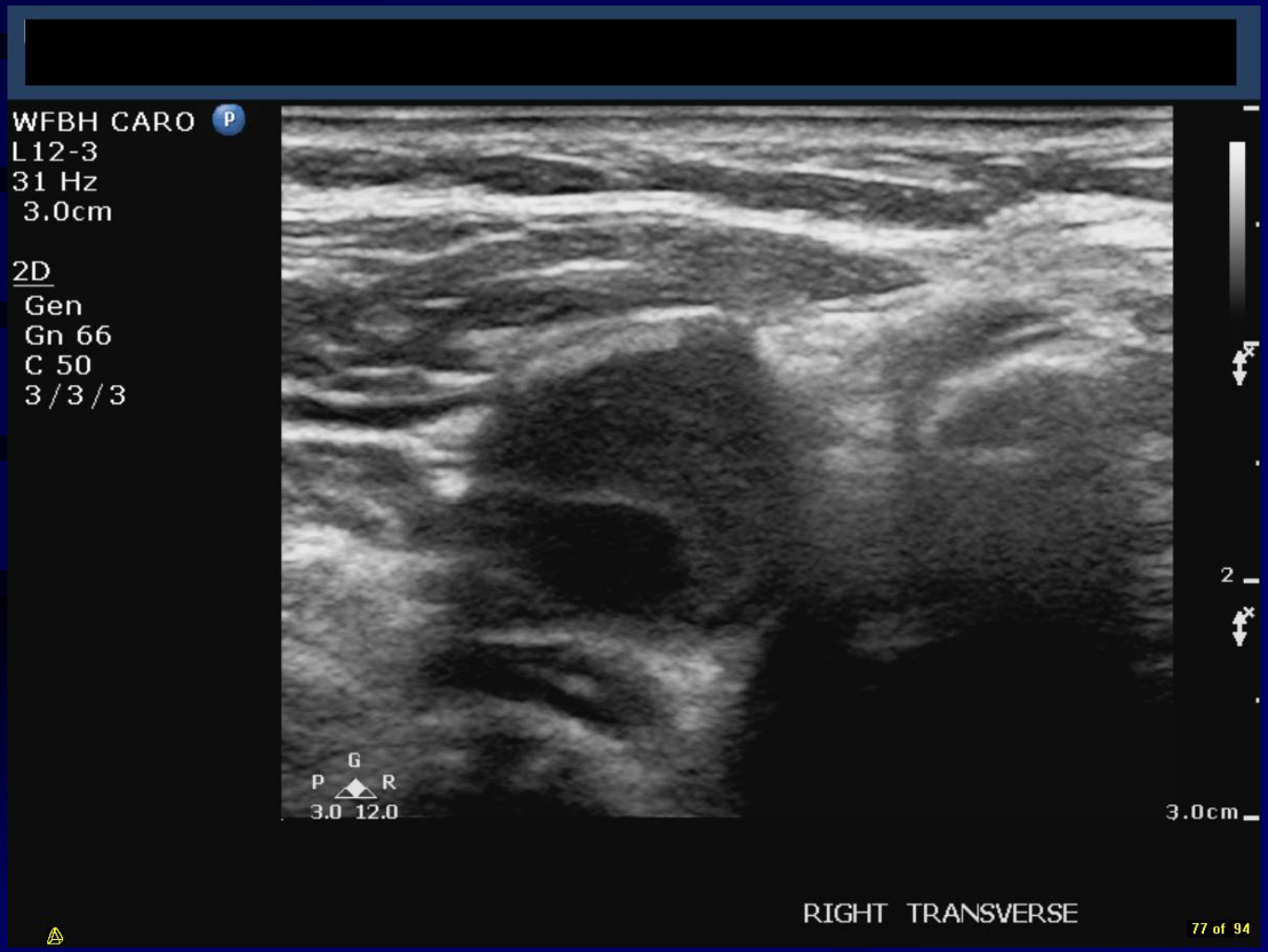

Internal Jugular Spontaneous Echo Contrast

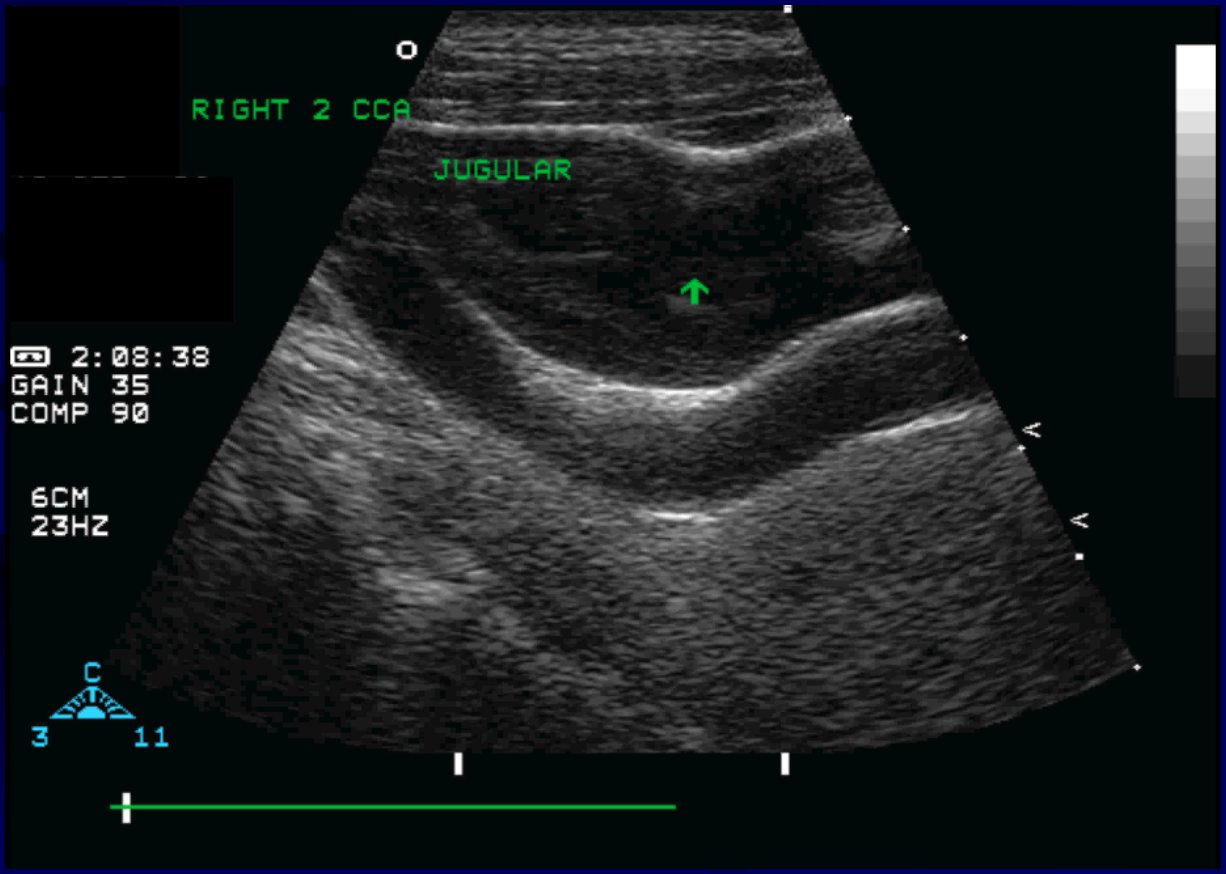

Internal Jugular Thrombosis

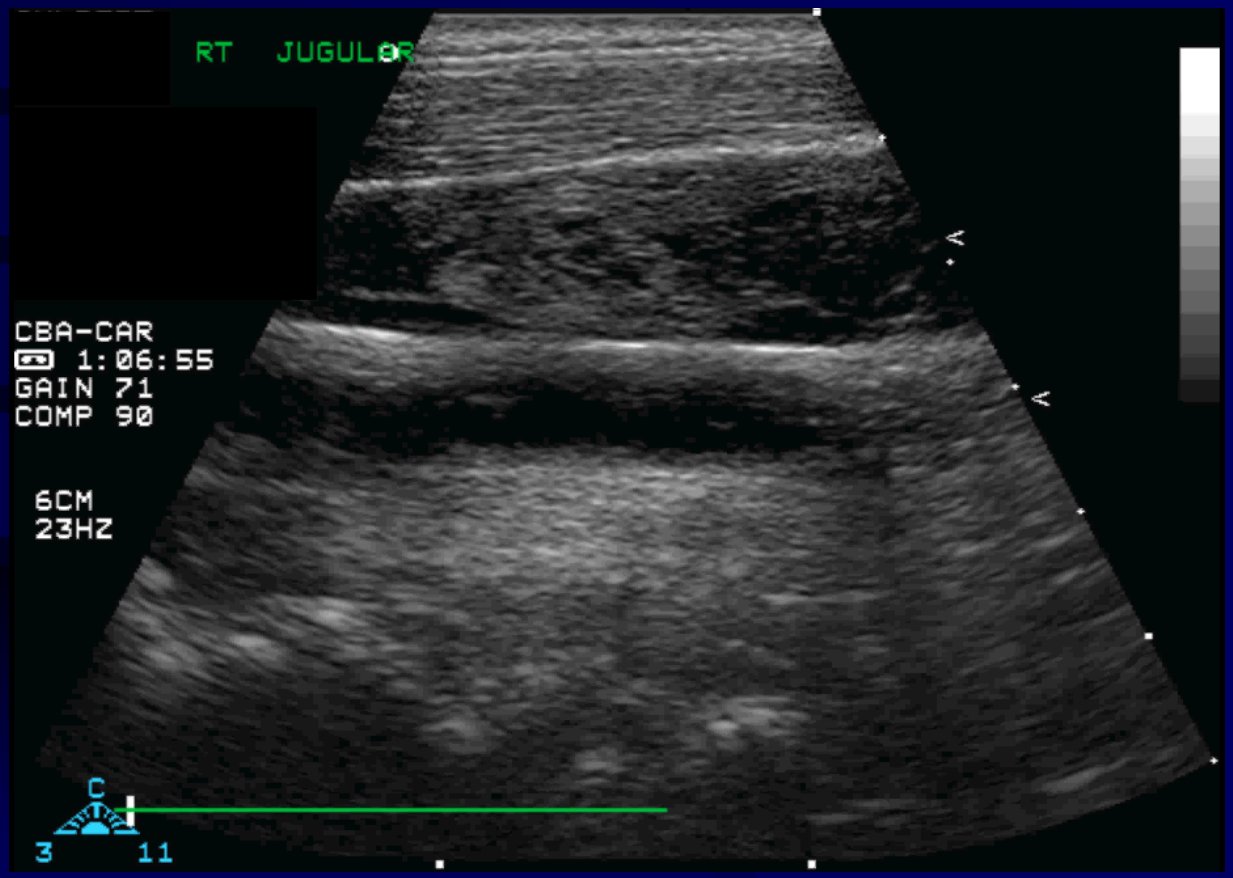

Color Flow Imaging CCA

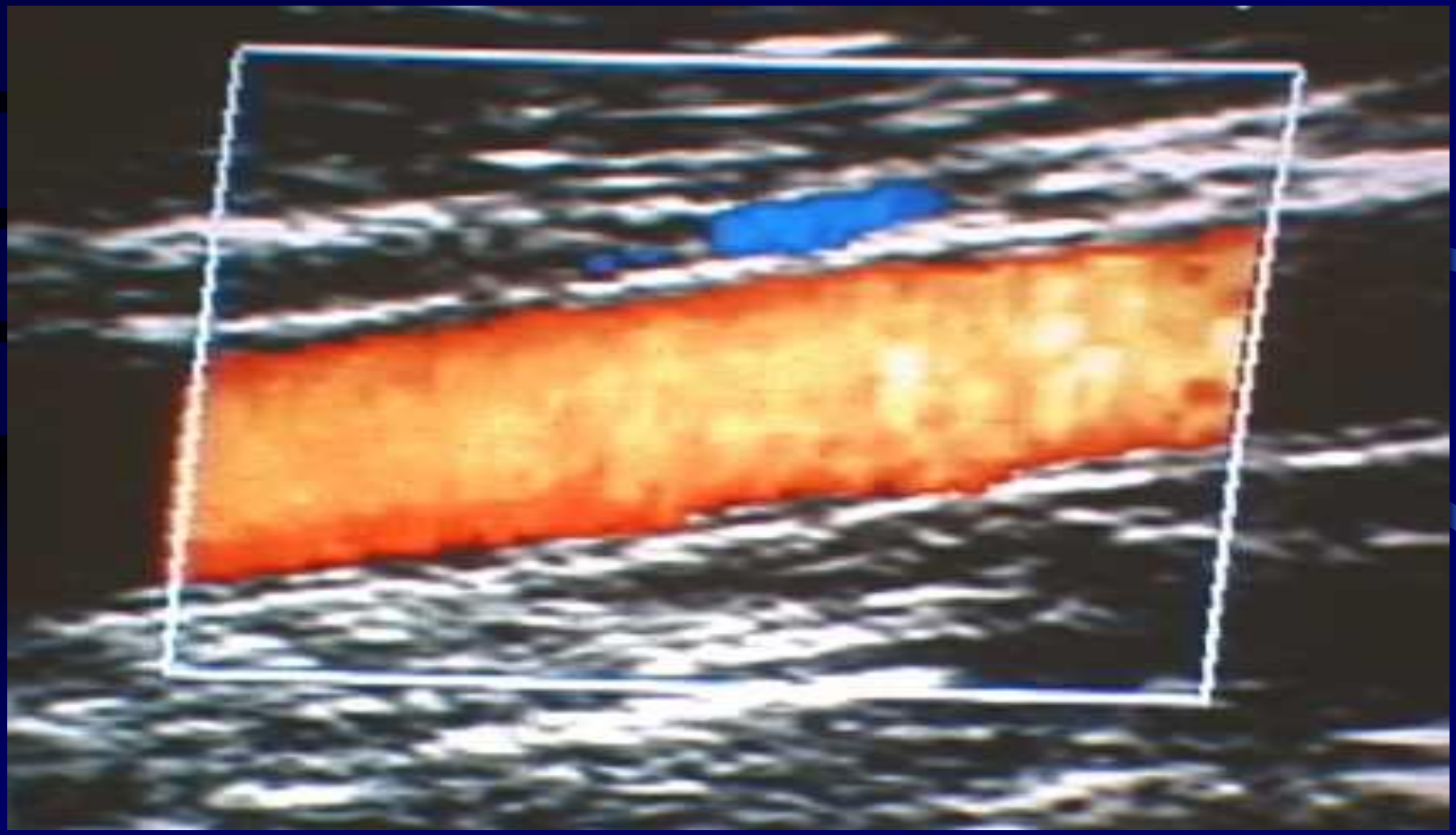

Color Flow Imaging

- Quick ID presence/direction of flow
- Road map for spectral Doppler
- More accurate angle of insonation
- Improved data on surface features
- ID of hypoechoic plaque (color void)
- ID string sign/near occlusions
- Speed up examination

Color Changes
Direction of Flow Relative to Transducer

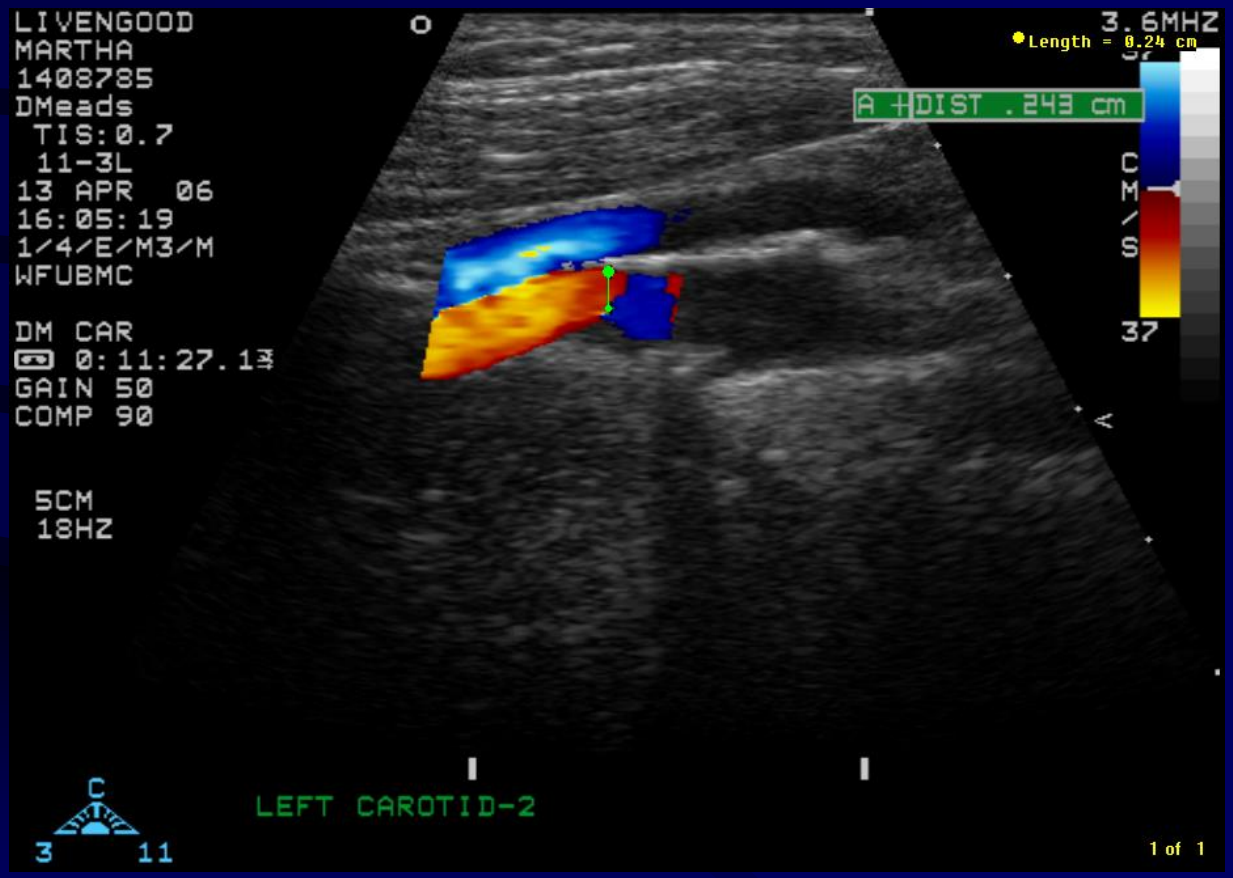

ICA Loop

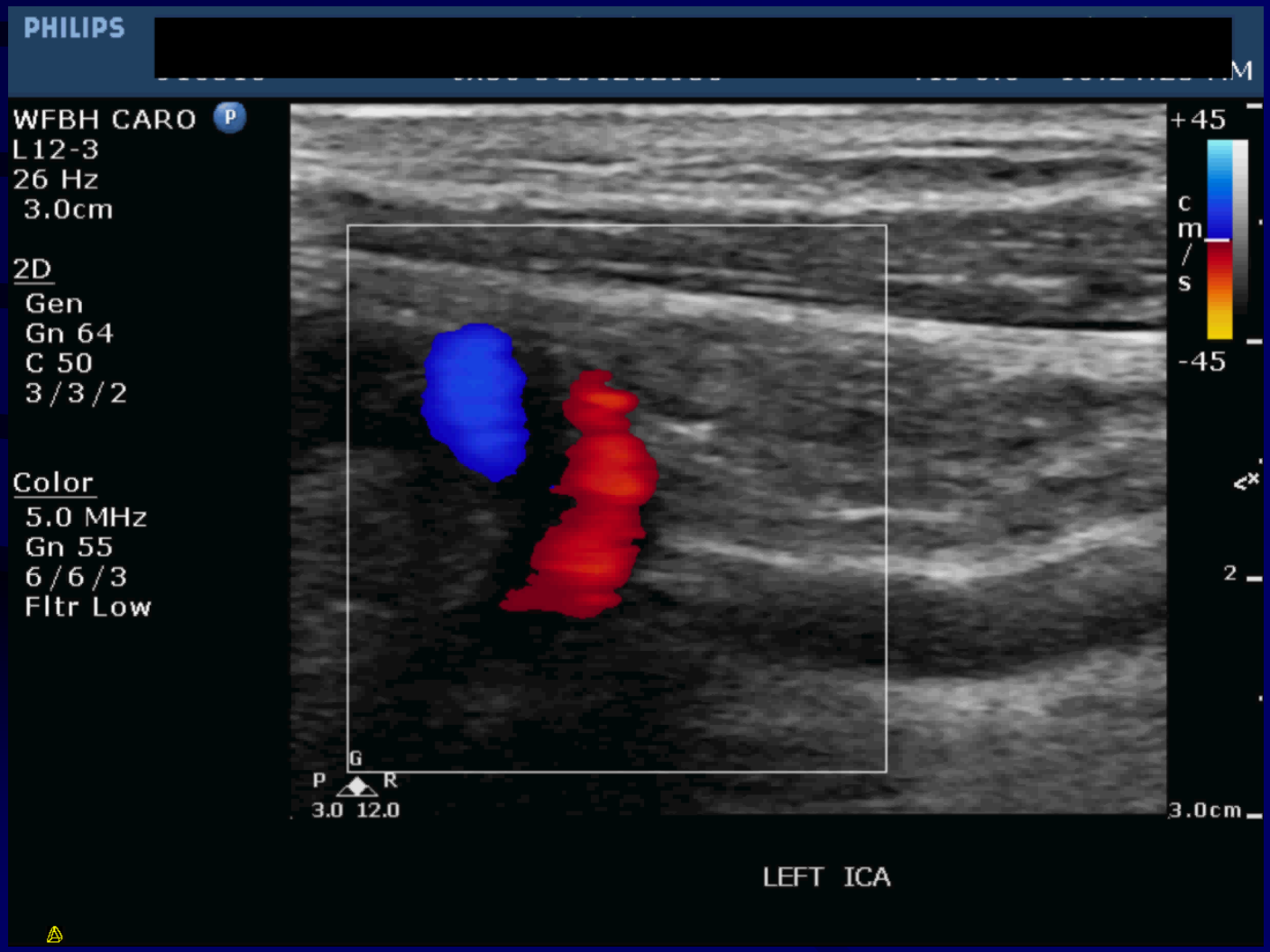
PHILIPS
[redacted]
WFBH CARO
L12-3
26 Hz
3.0cm
2D
Gen
Gn 64
C 50
3/3/2
Color
5.0 MHz
Gn 55
6/6/3
Fltr Low
+45
cm/s
-45
2
G
P
R
3.0 12.0
3.0cm
LEFT ICA

Color Flow Tight Stenosis

Color Flow Imaging

Color void of hypoechoic plaque - transverse

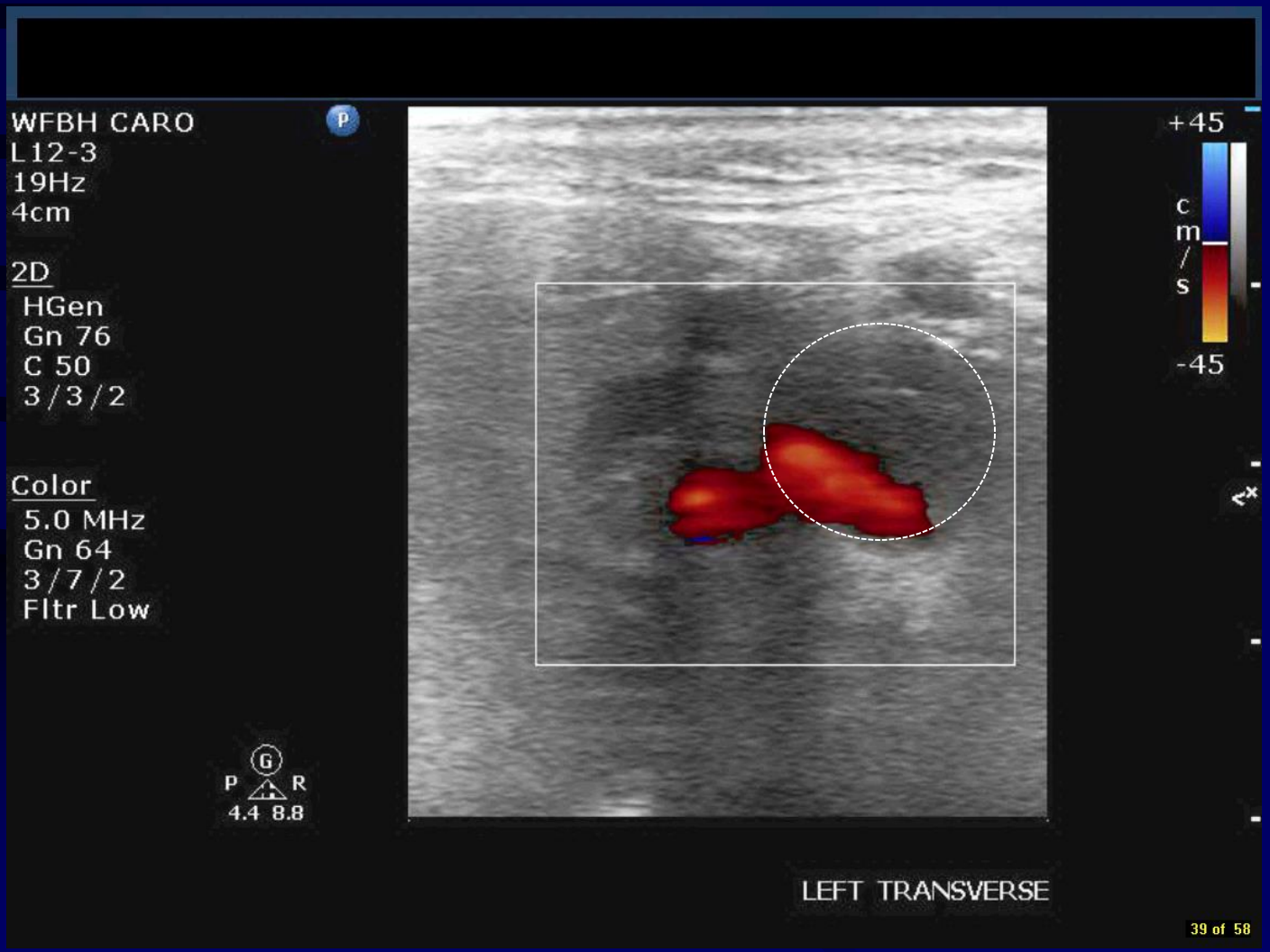

Boundary Layer Separation

Stent: Proximal End

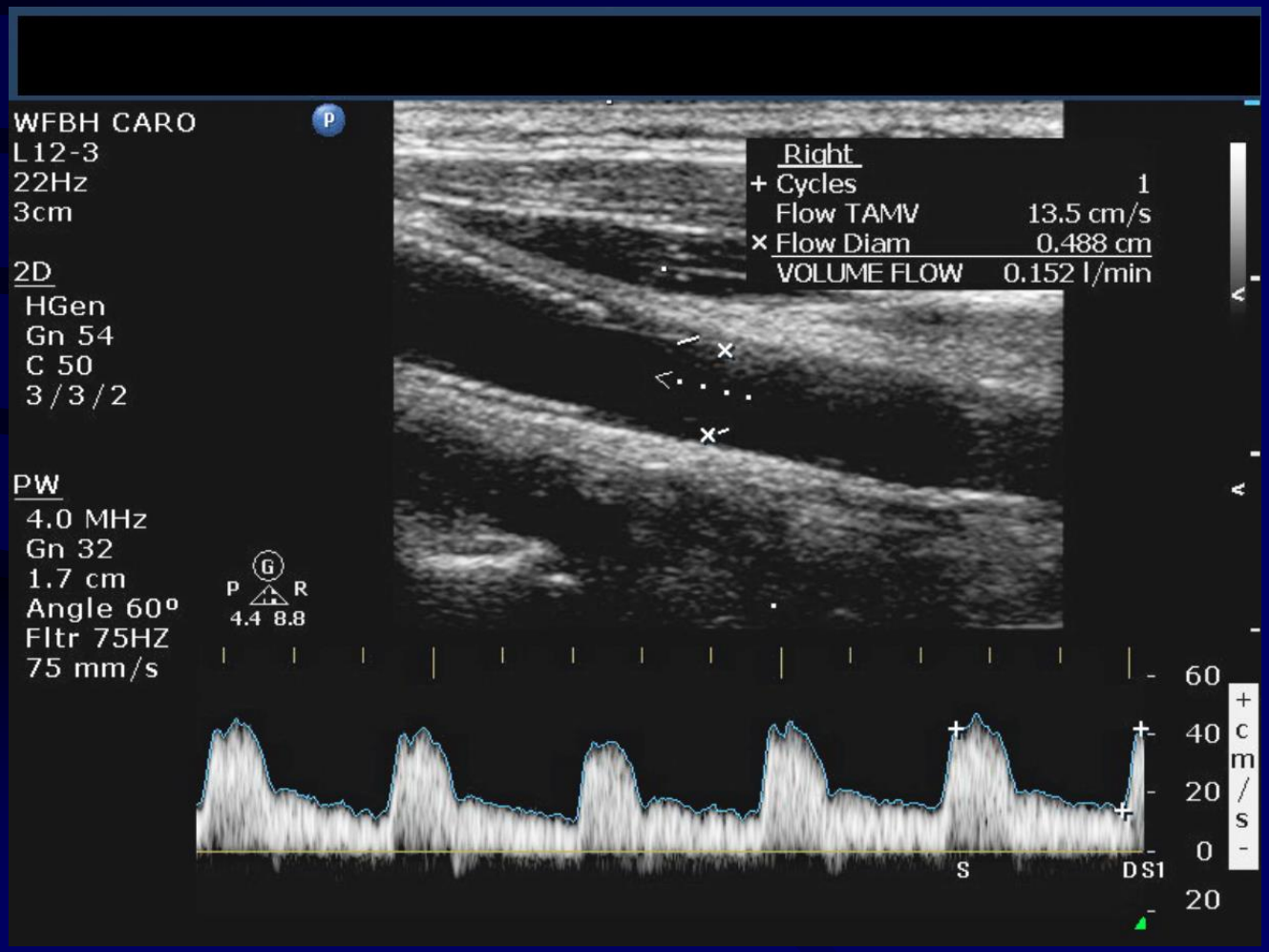

Stent: Color Flow

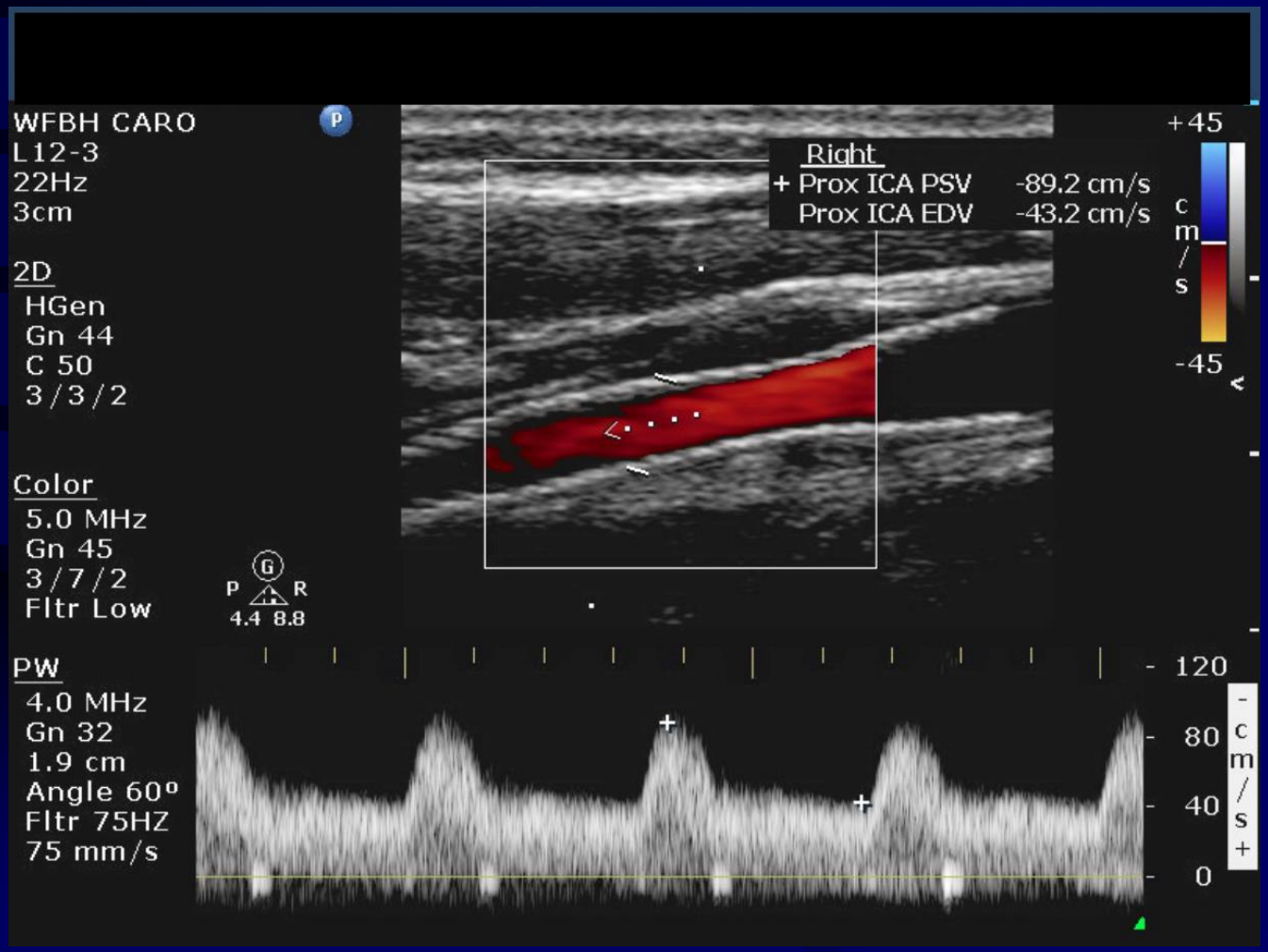

Stent: Lumen Measurement

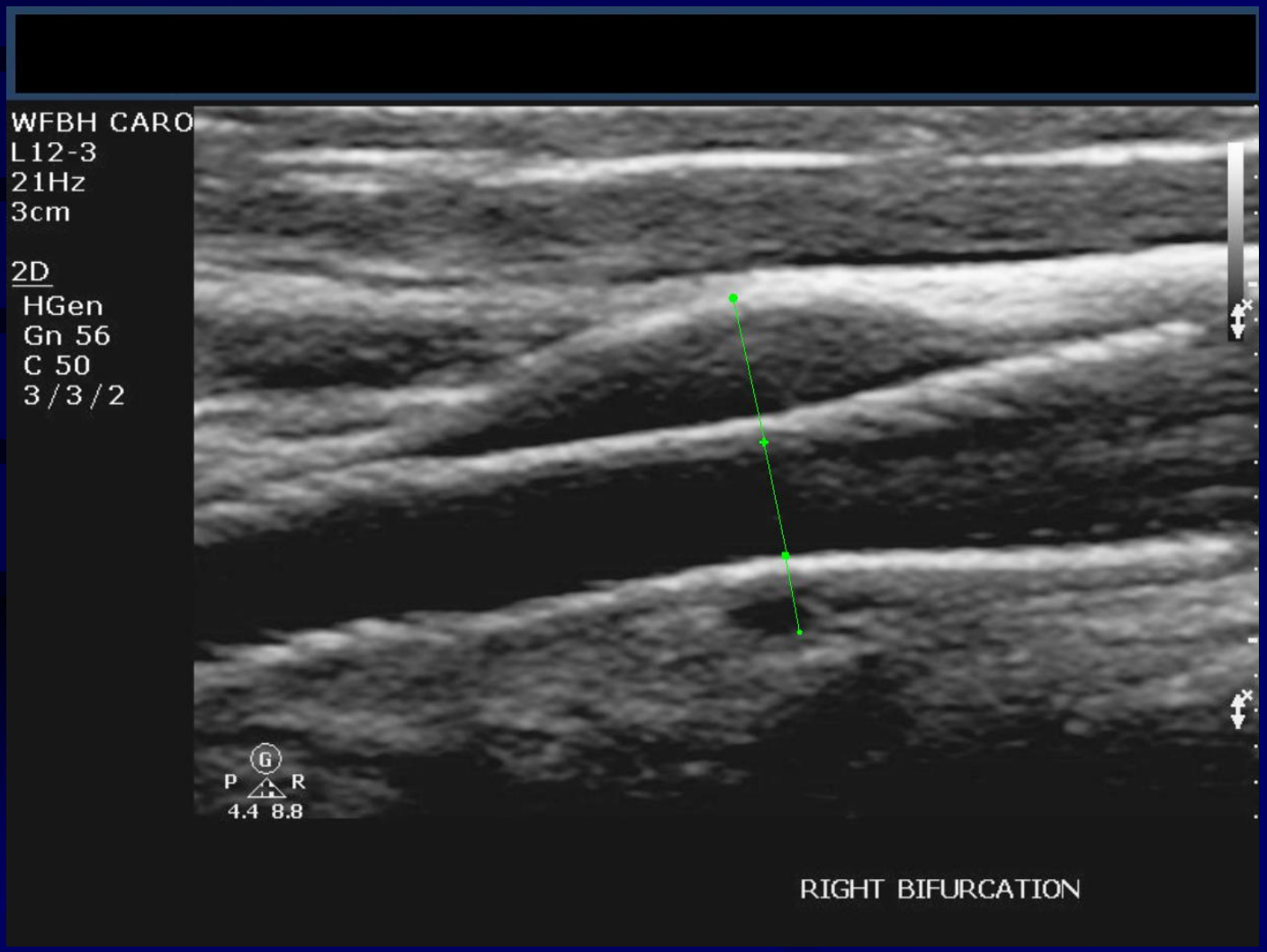

Stent Stenosis

Post-Stenotic Turbulence

Color Blooimg

Large ICA Plaque

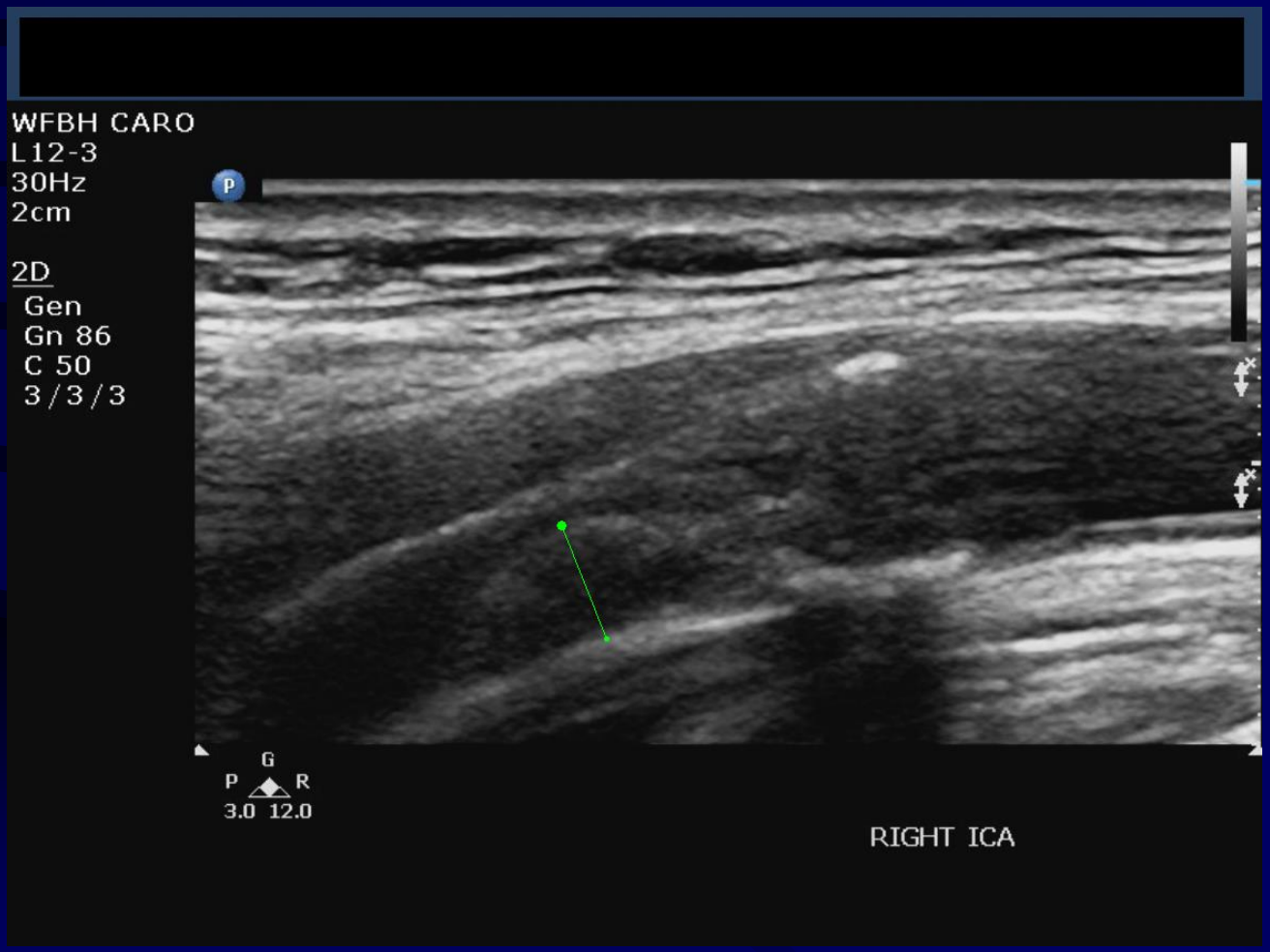

Color Blooming Beyond True Lumen

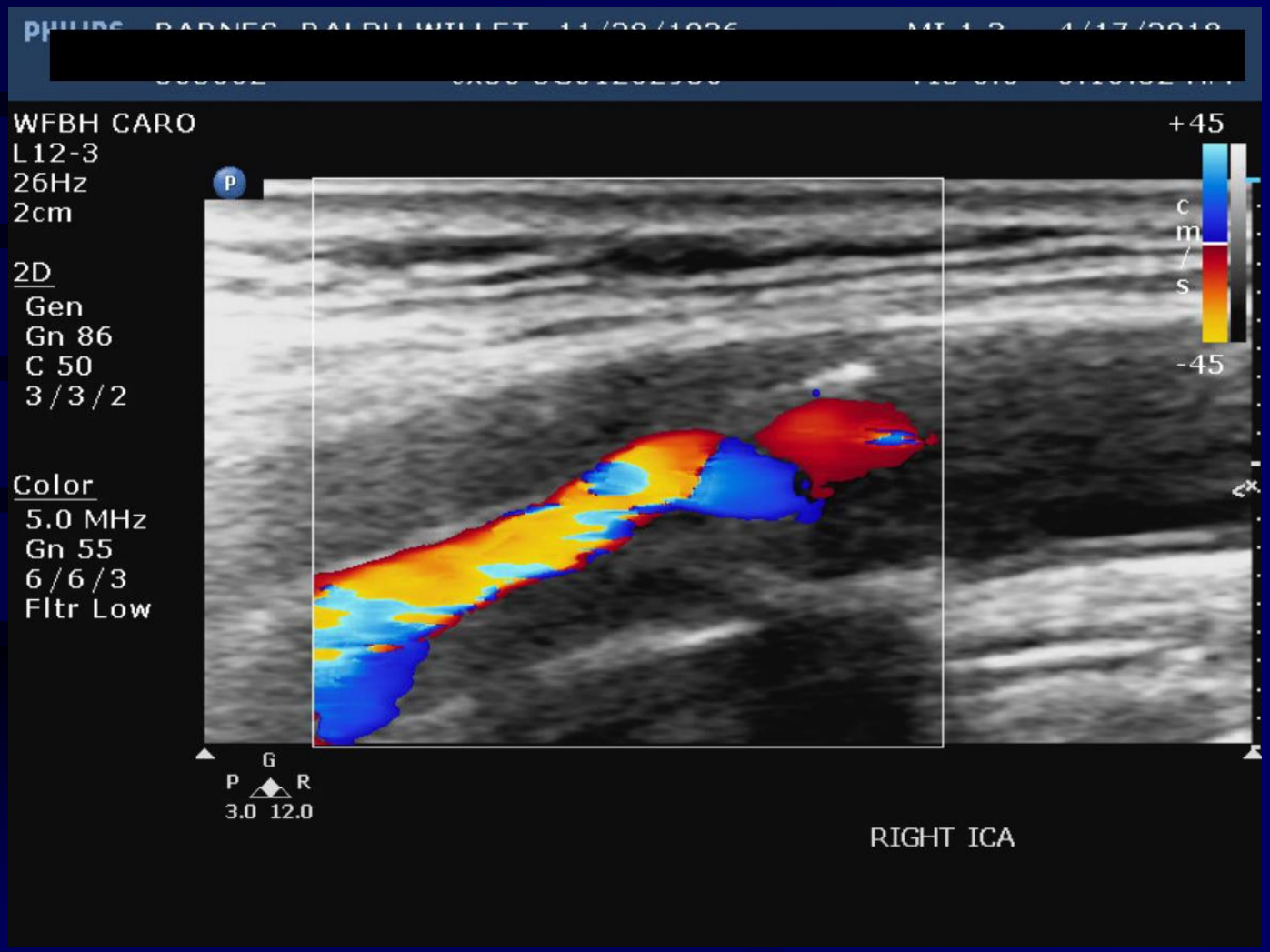

Color Blooming Power Doppler

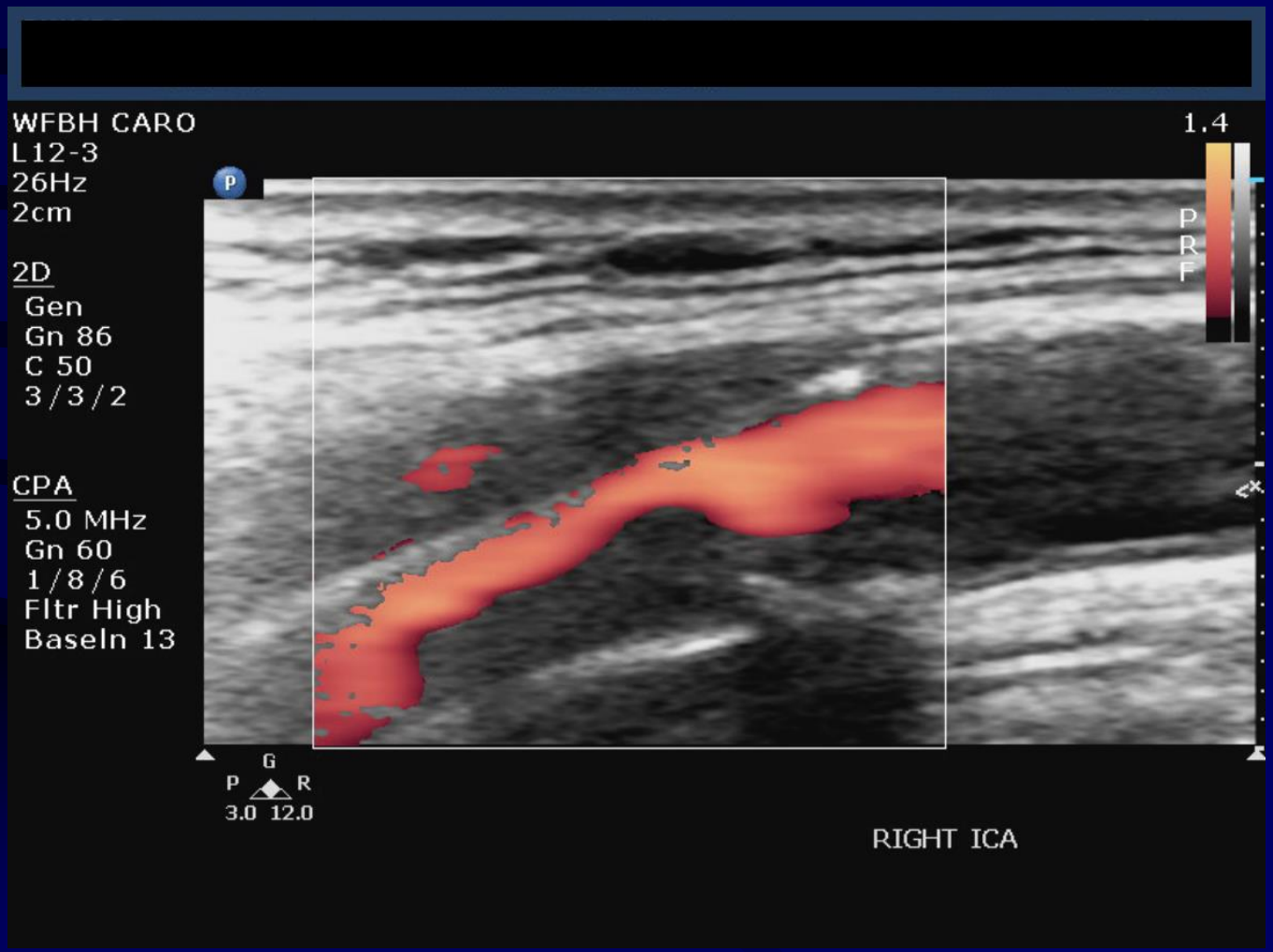

Normal Appearing Thyroid - Right

Thyroid – Increased Vascularity, Small Cyst

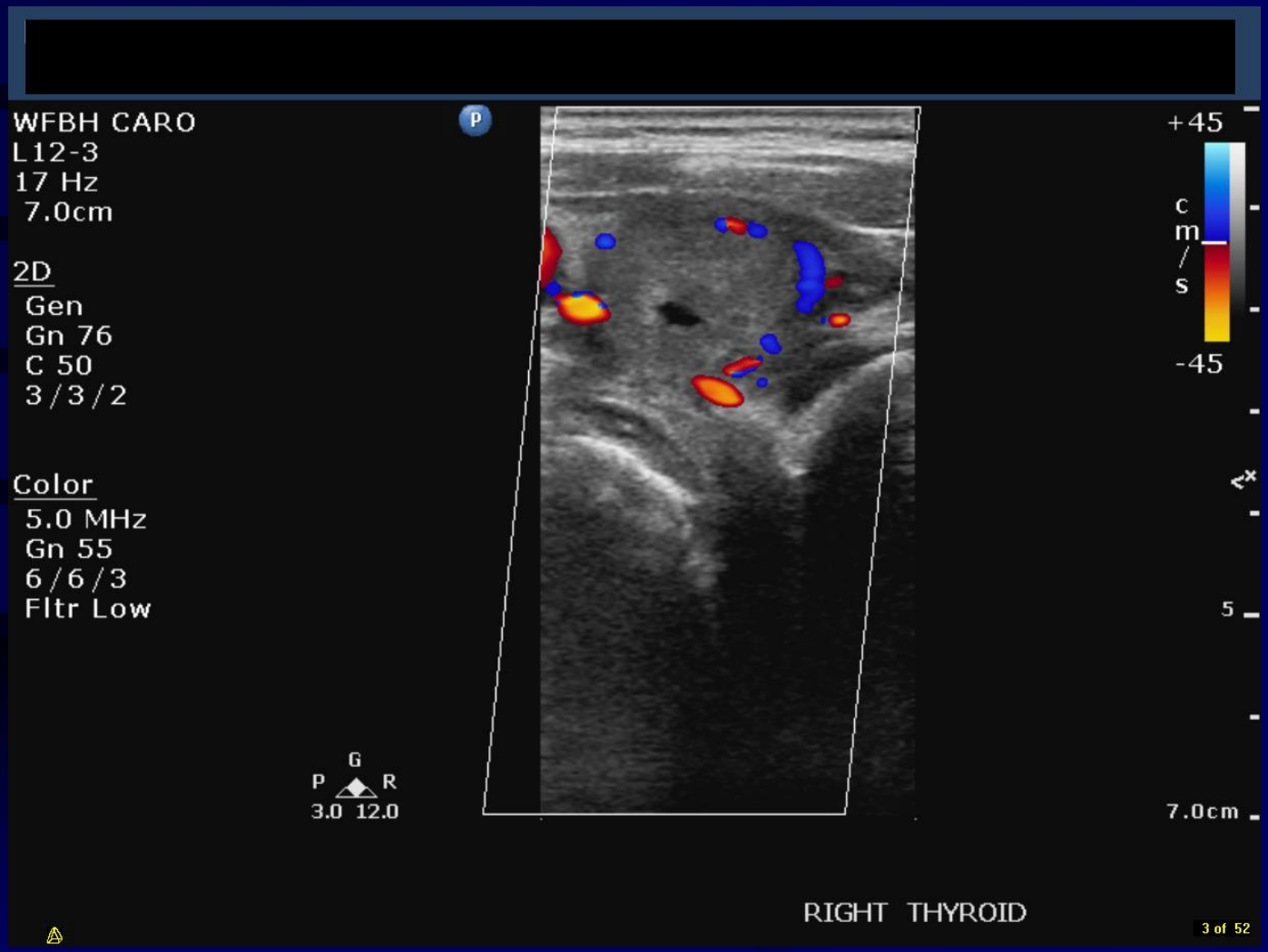

Multiple Small Thyroid Cysts

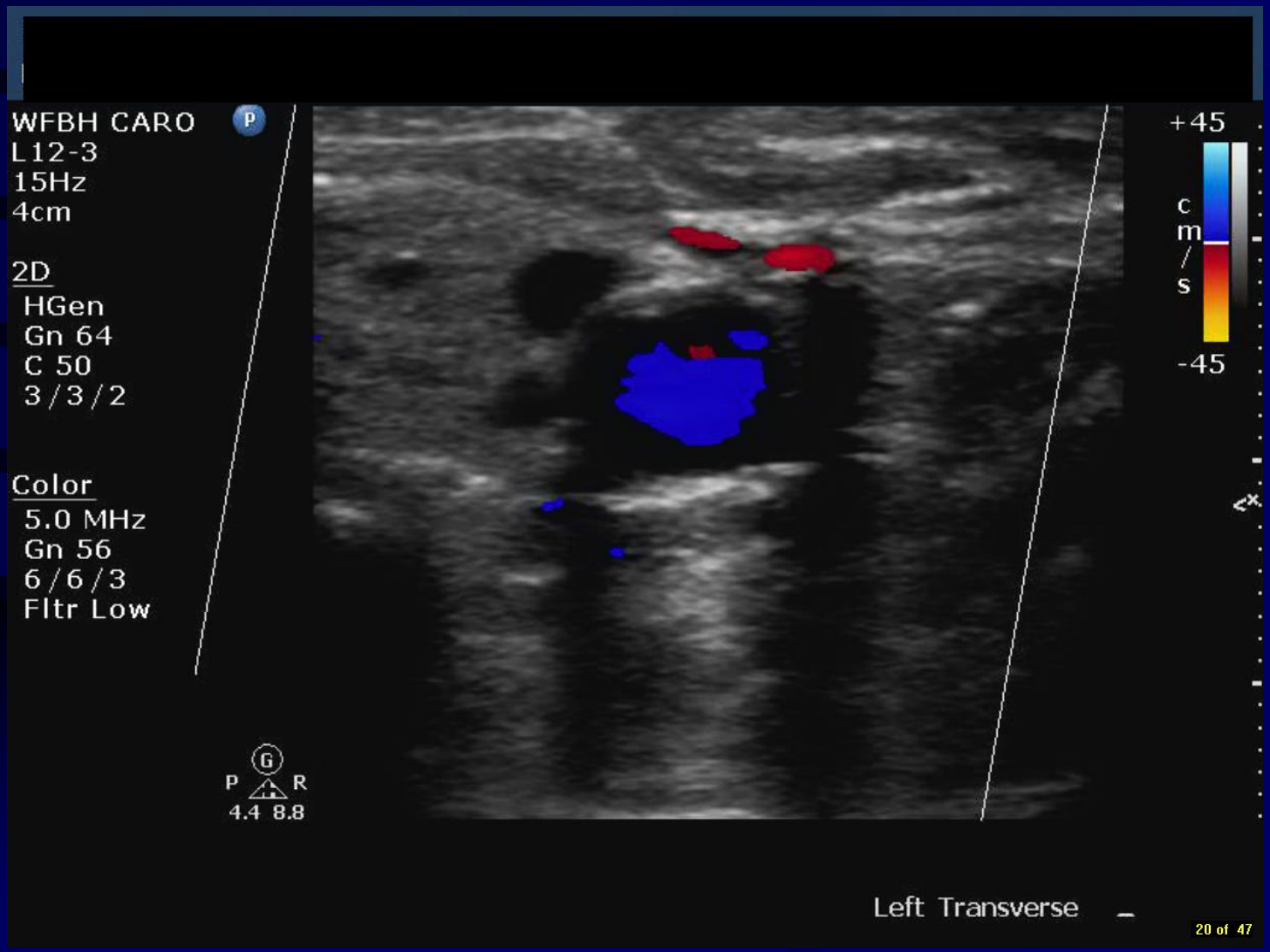

Cerebrovascular Anatomy

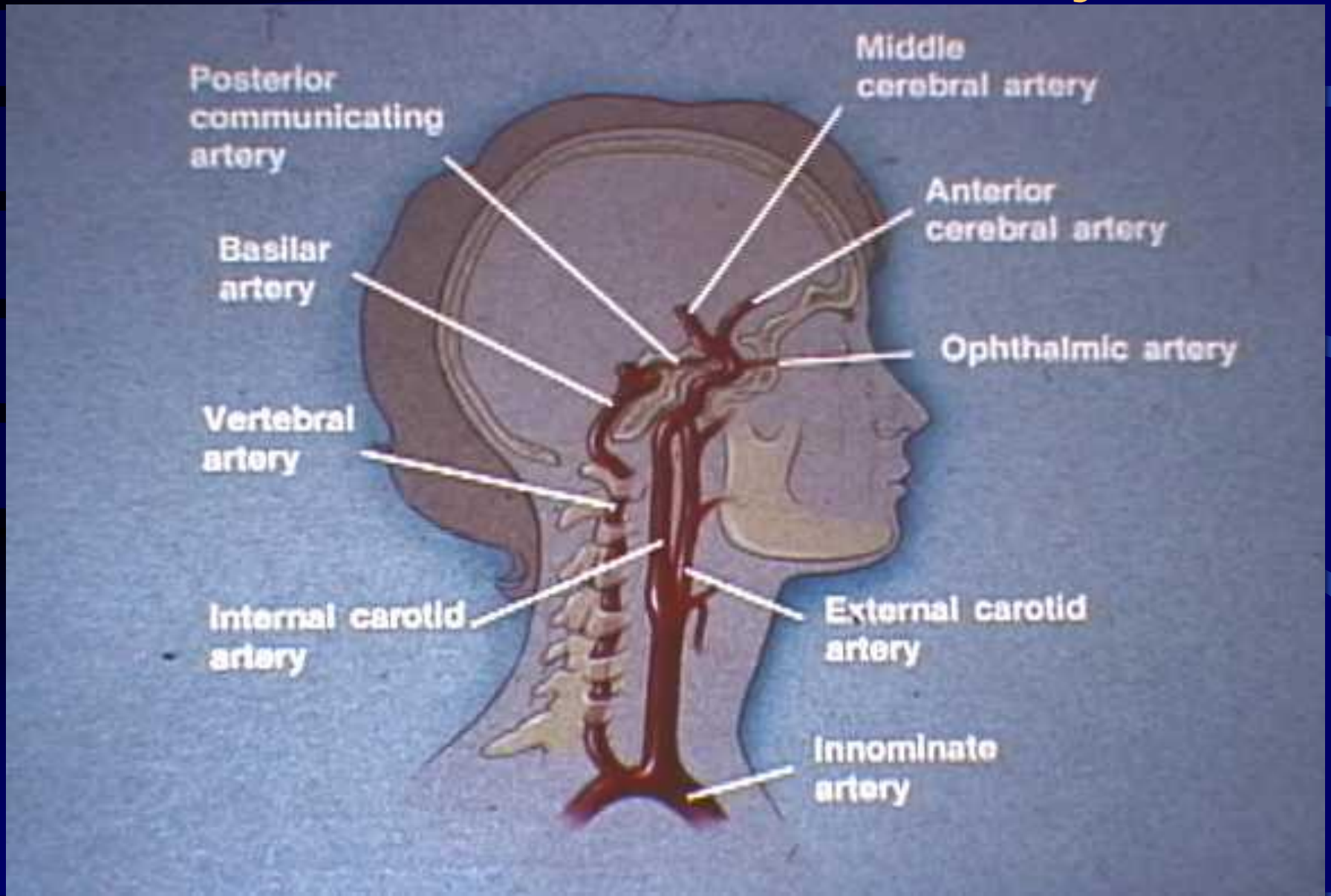

Color Flow Vertebral Origin

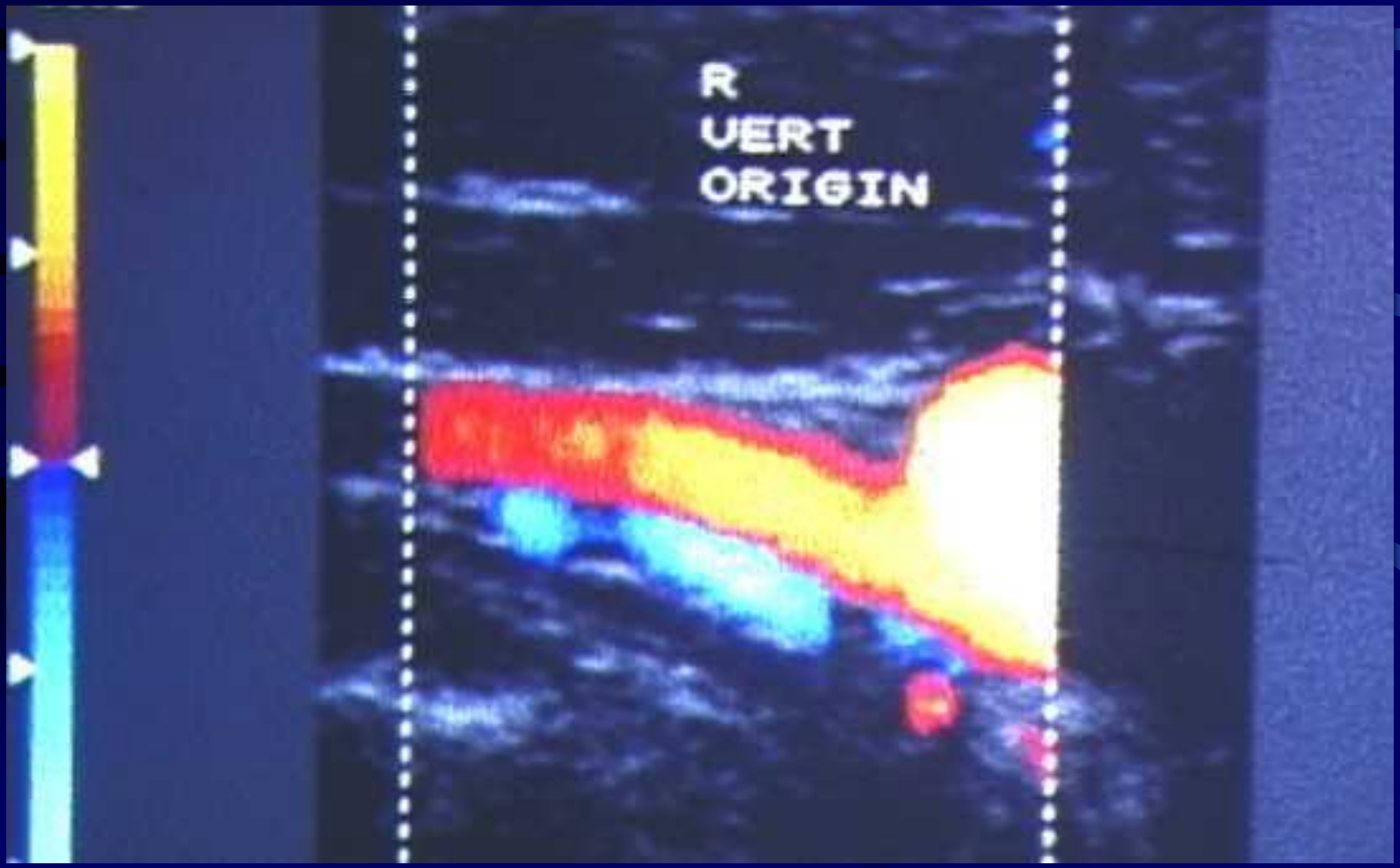

Duplex Interosseous Vertebral

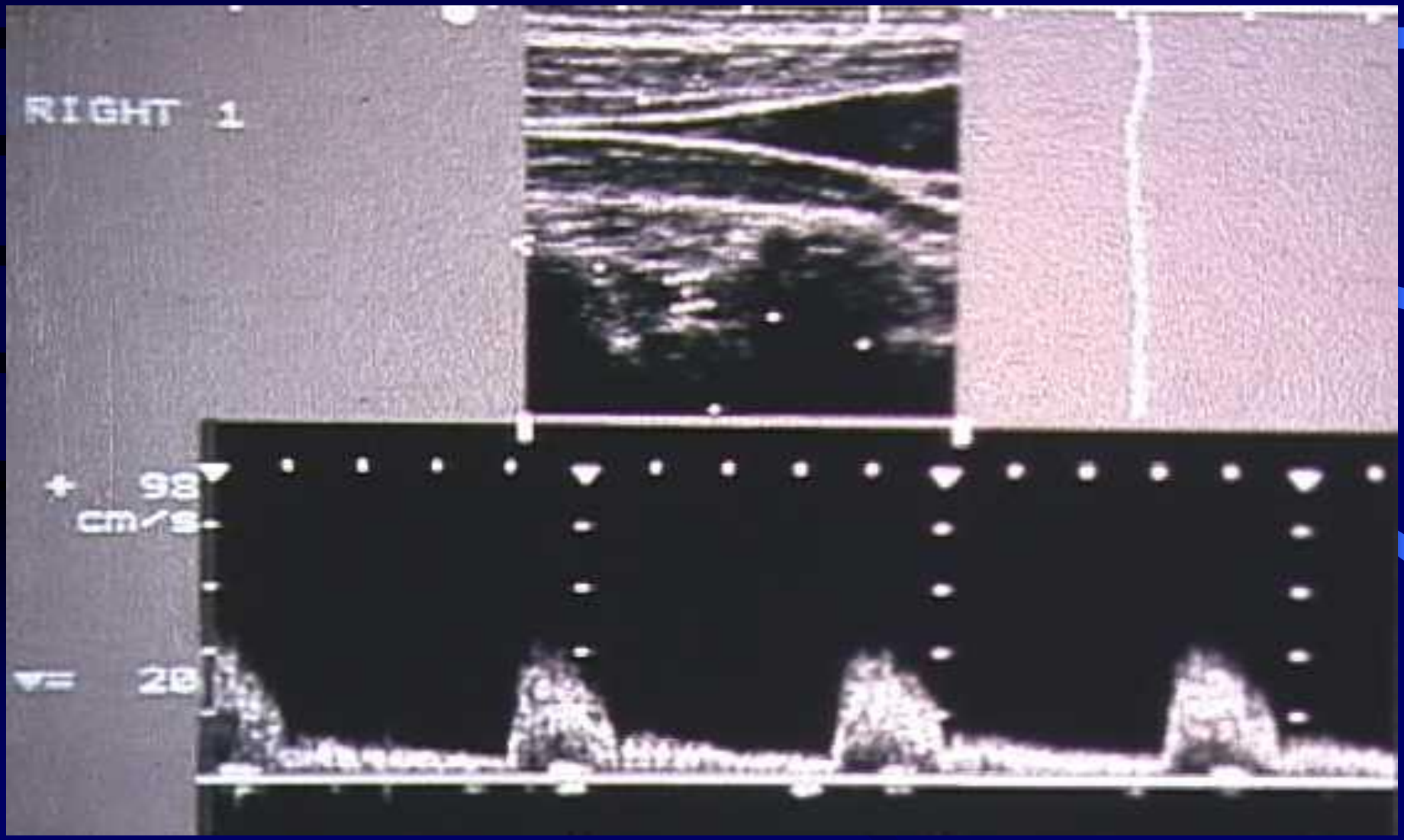

Vertebral/Subclavian Steal

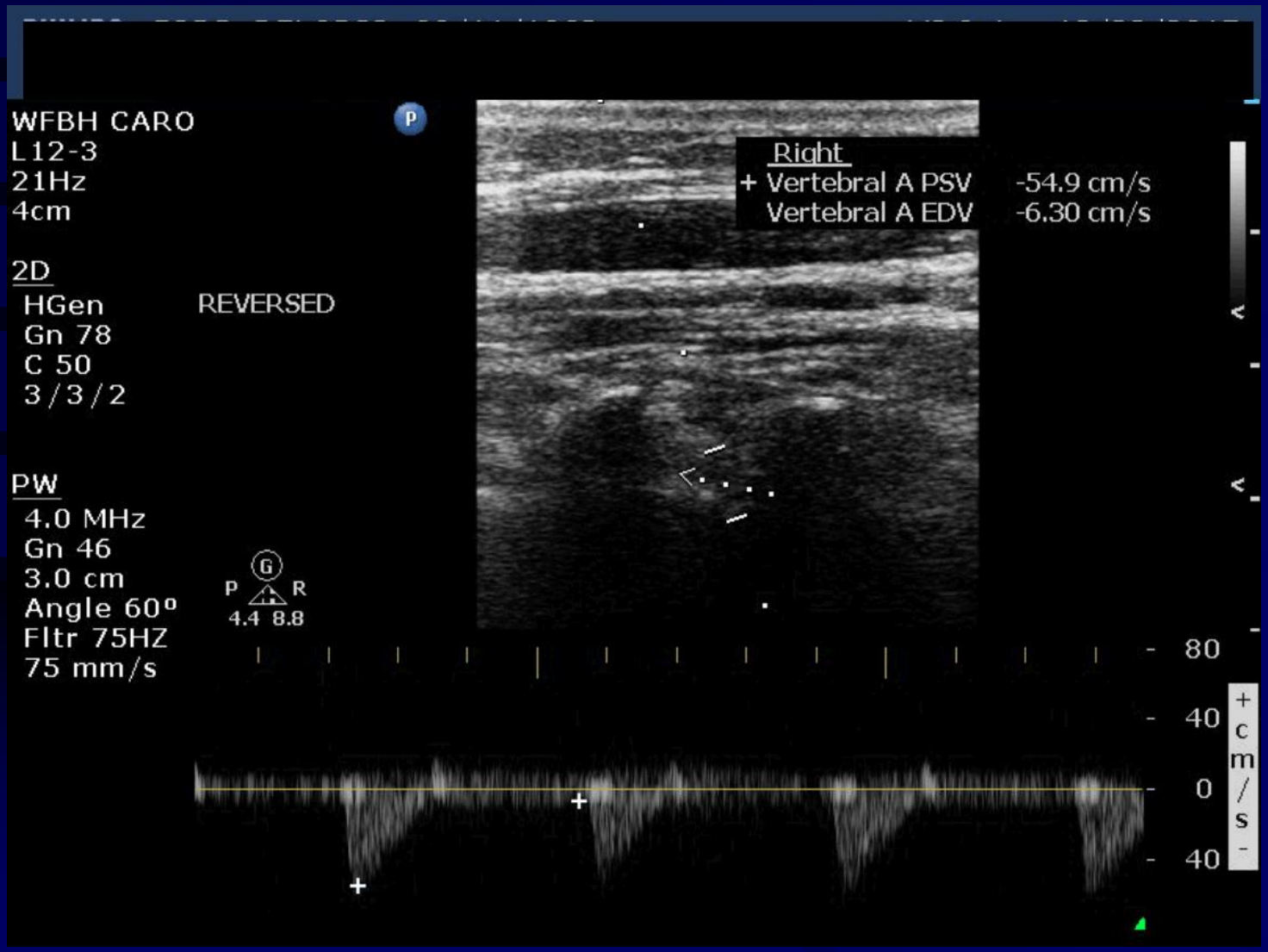

Put It All Together

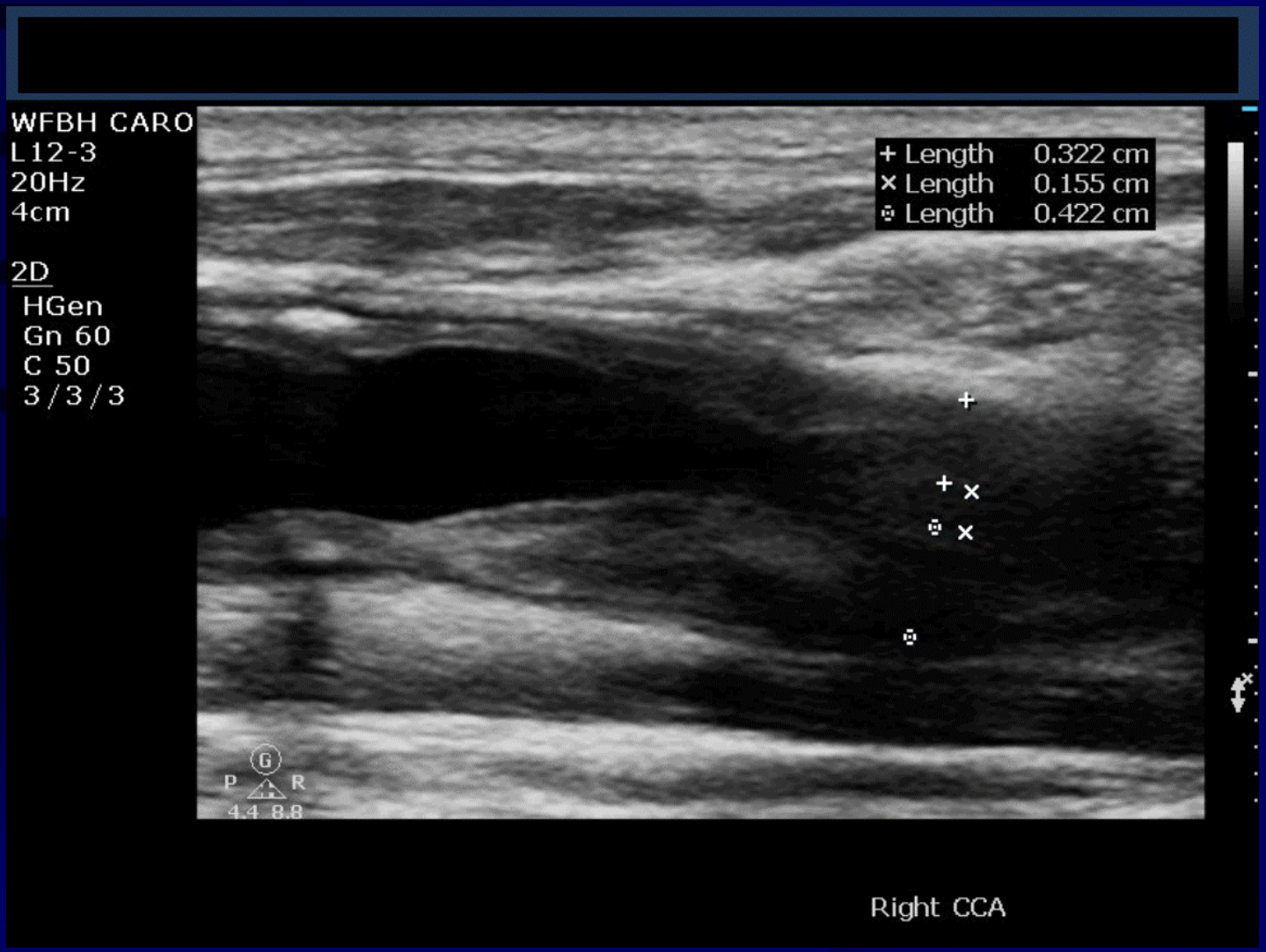

Put It All Together

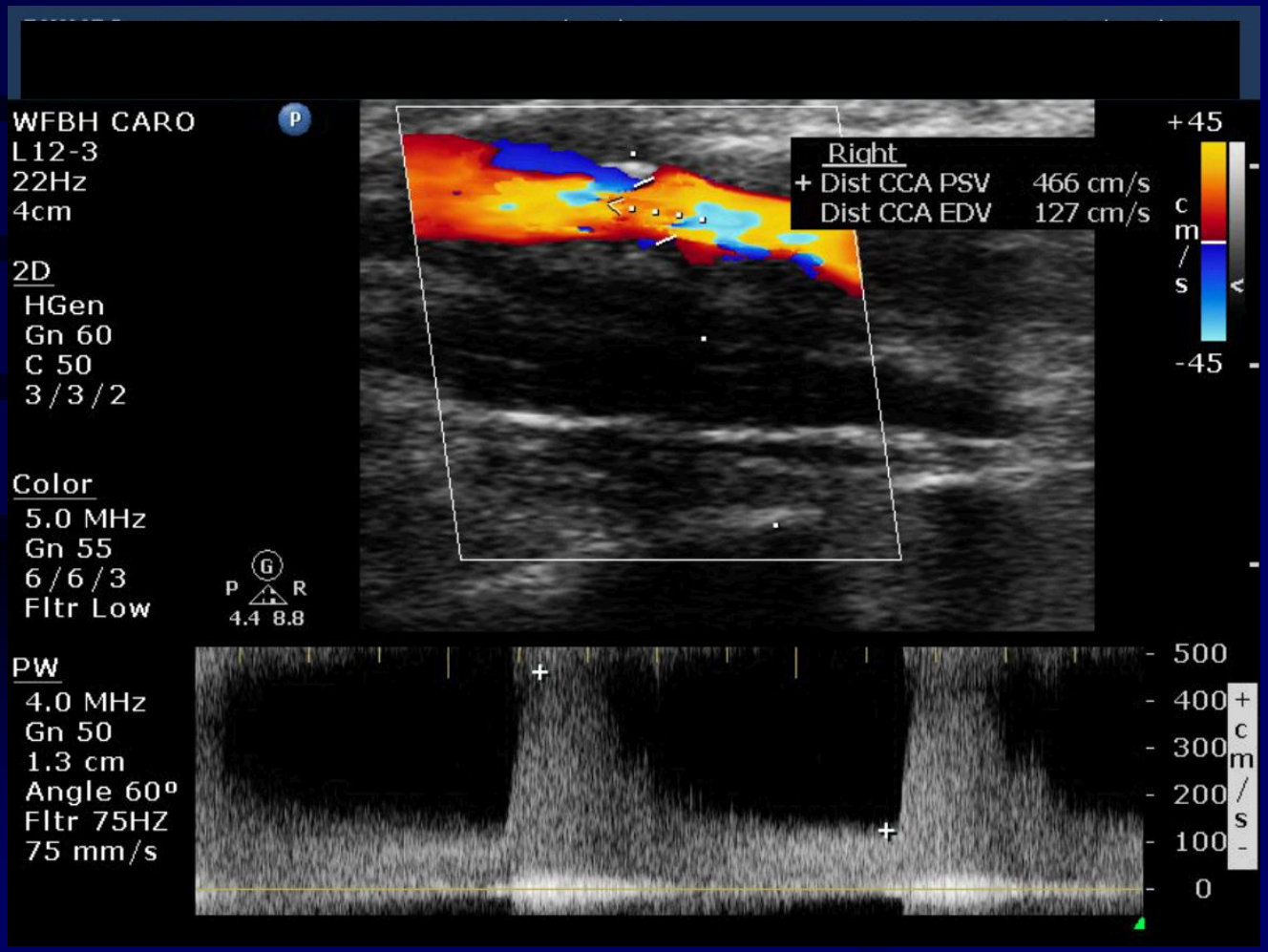

Put It All Together

Put It All Together

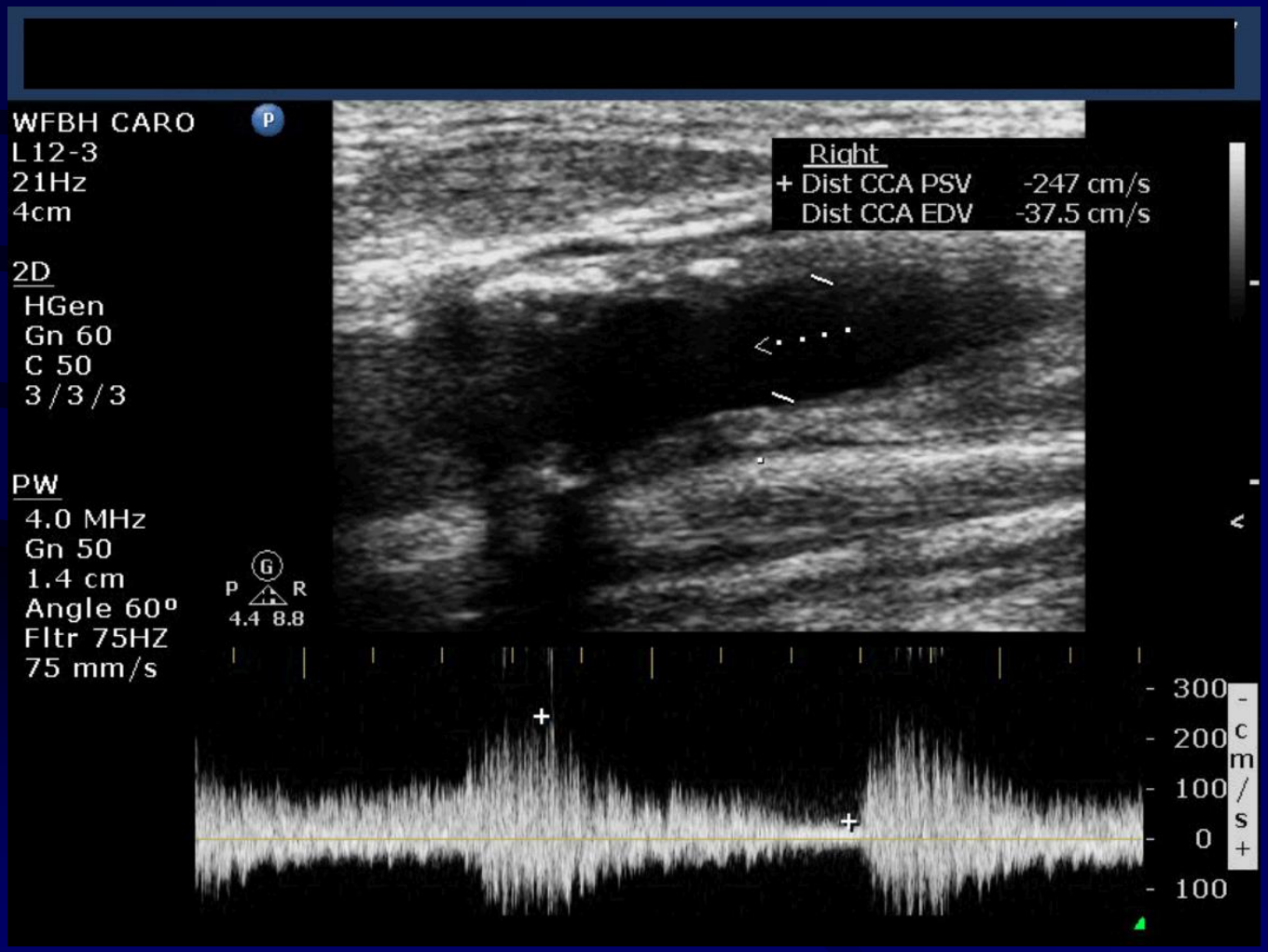

Put It All Together

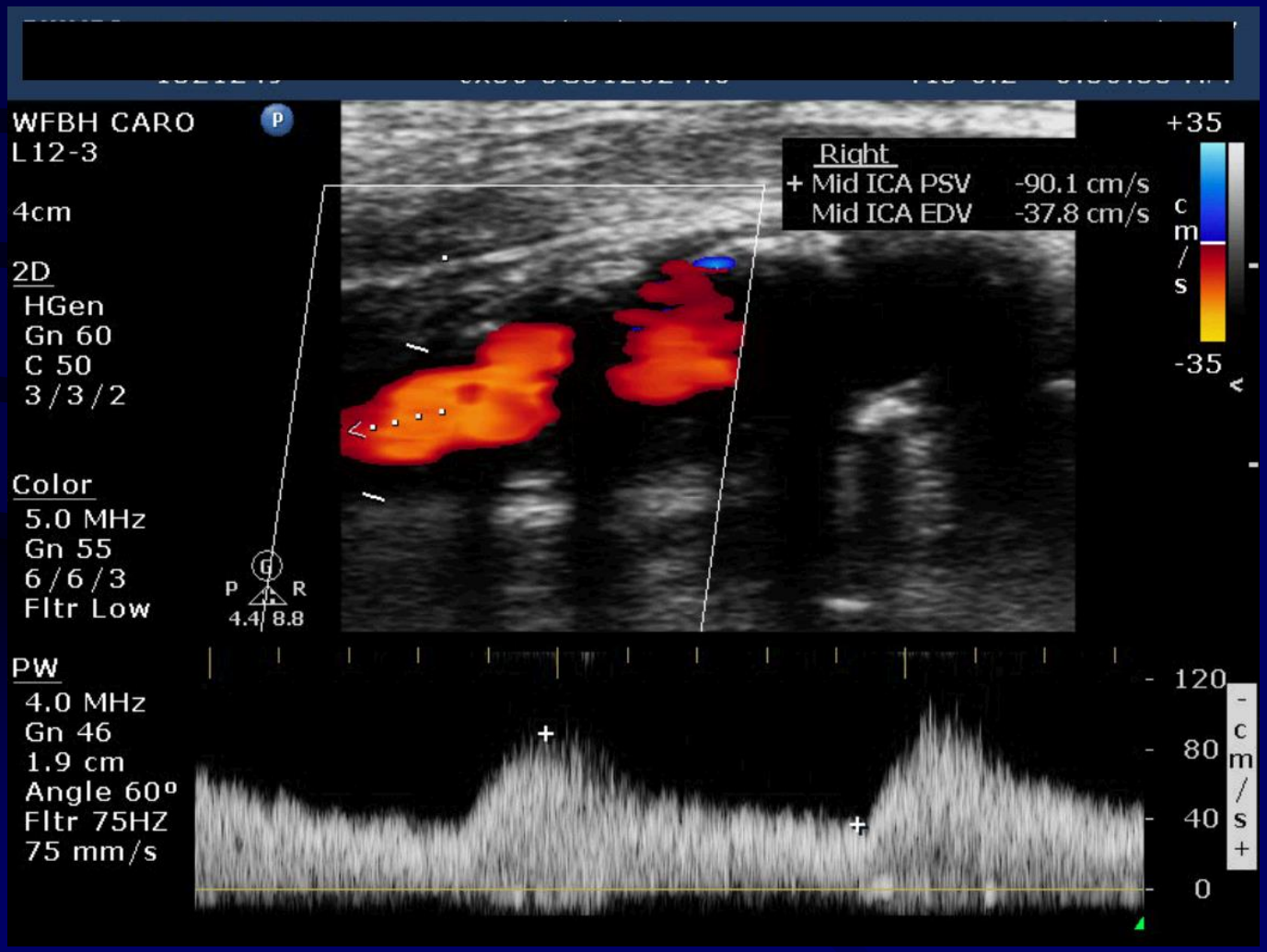

Put It All Together

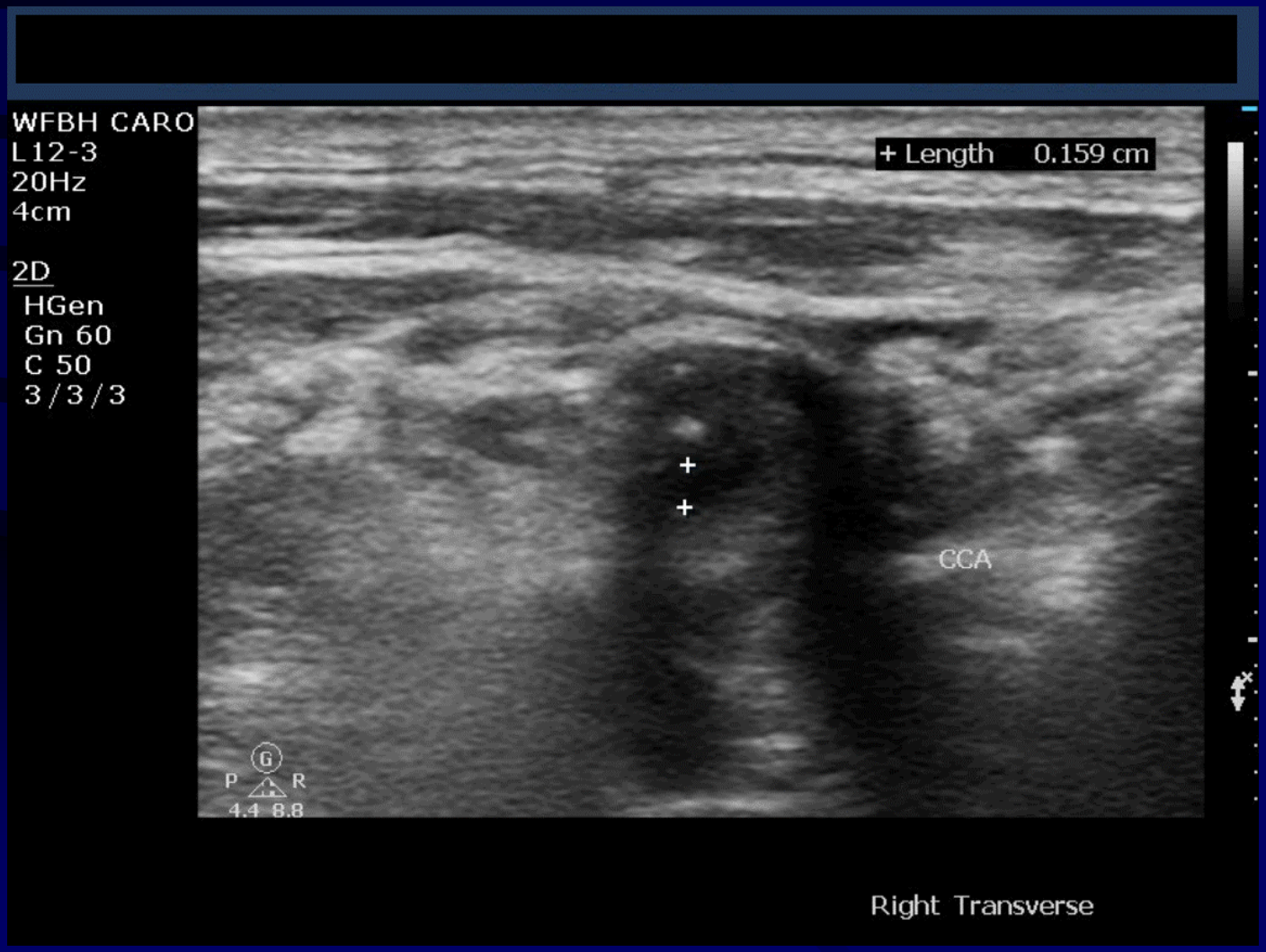

Put It All Together