


Cases

Marc Malkoff MD

Case1

- 72 yo man in good health
- Got dizzy and fell w/o LOC from standing position 6 hrs ago
- GCS 15 at OSF
- Ct scan acute subdural
- Drove 90 min to our ED and brought a disk with his images

Review of 1st CT

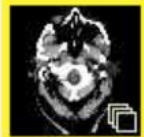

Warning



Virus alert!

OK



Series 1
40 Images



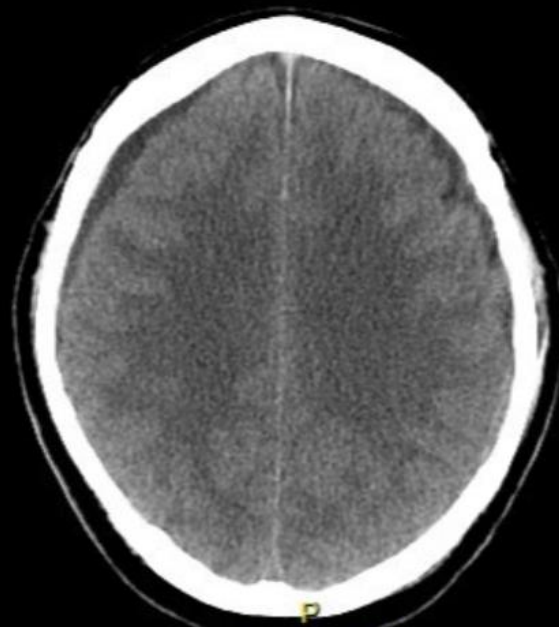
Series 2
1 Images



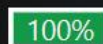Series 3
1 Images

R

A

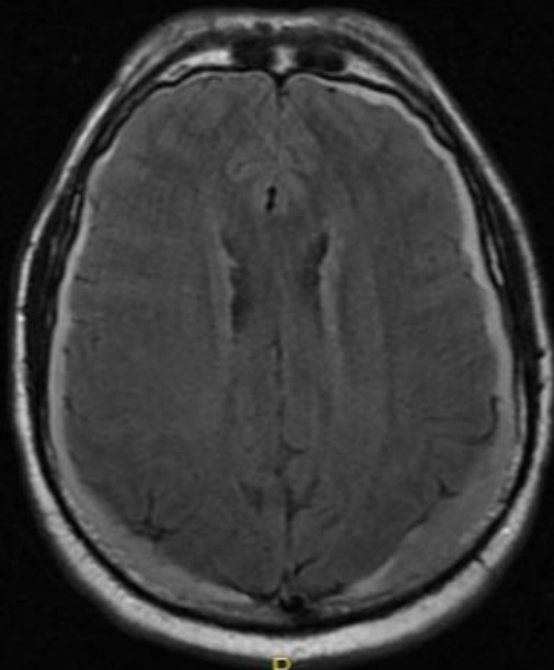


P
Lossless 1:1



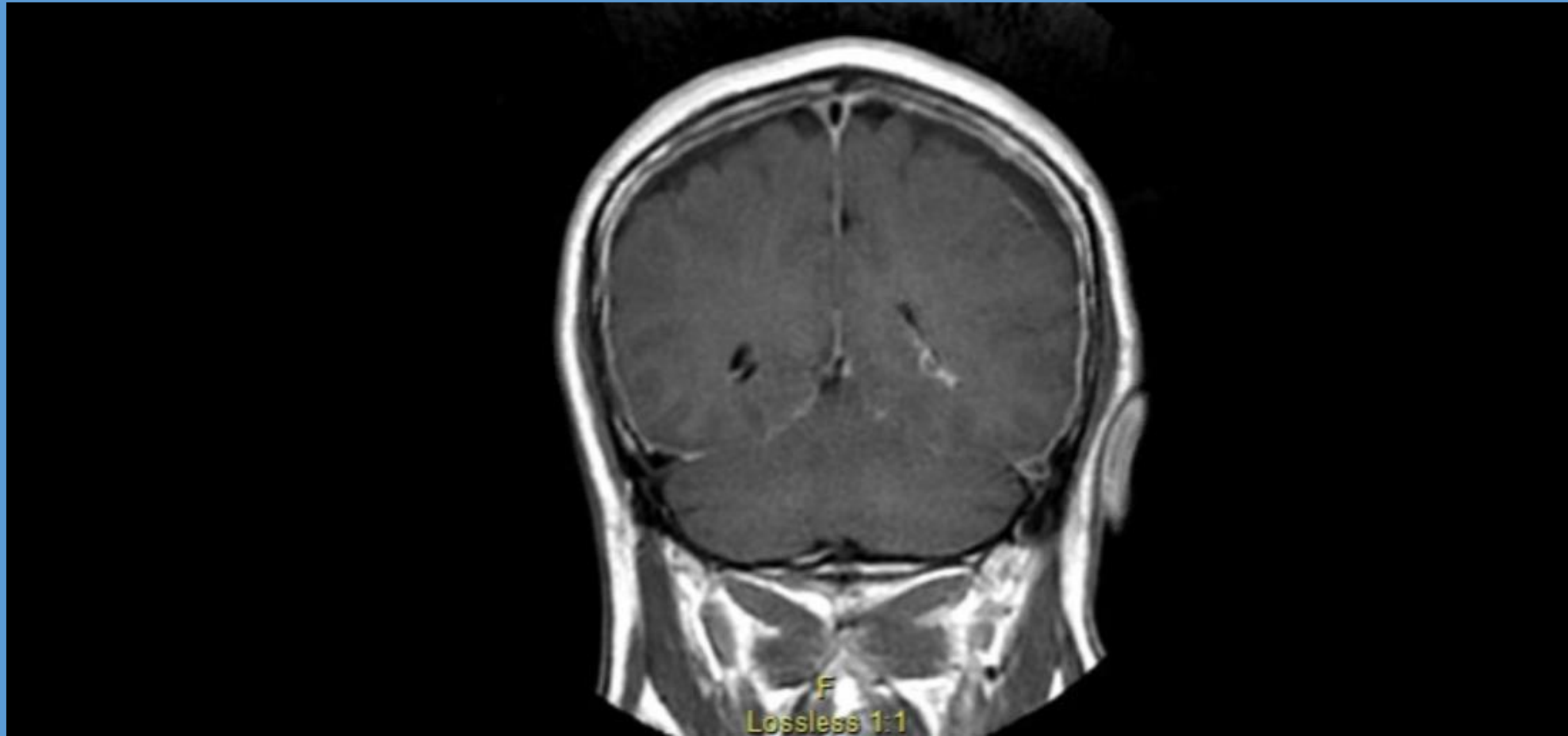
7
1/

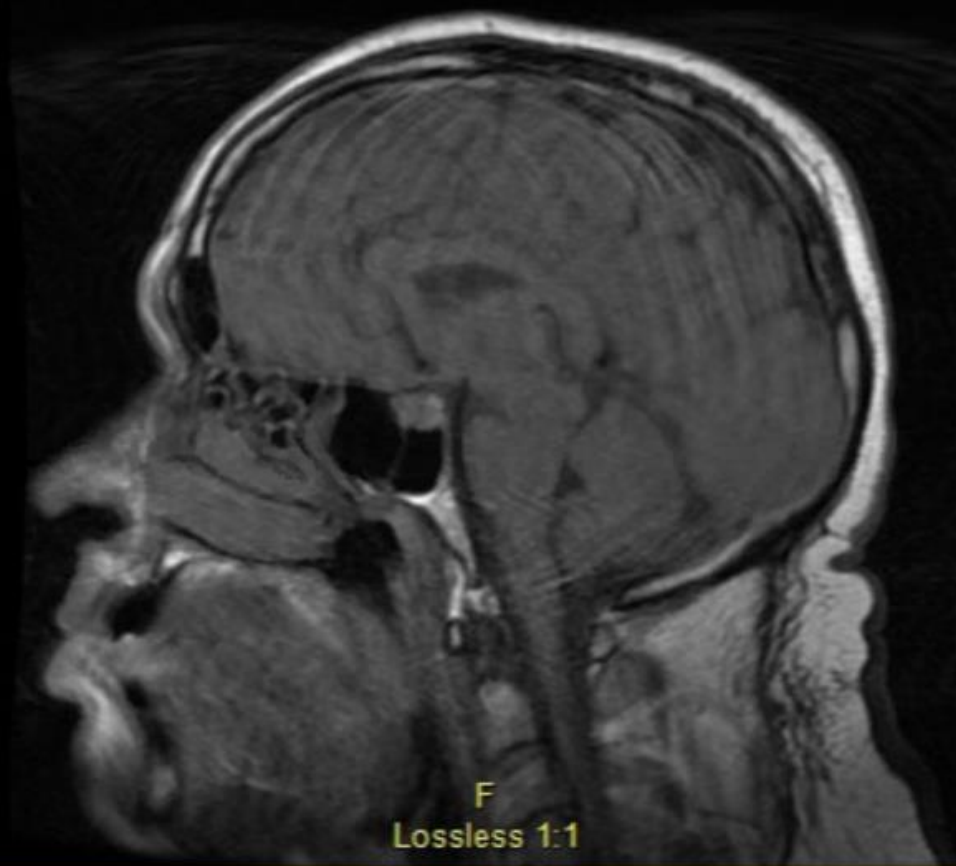A



P

Lossless 1:1





F
Lossless 1:1

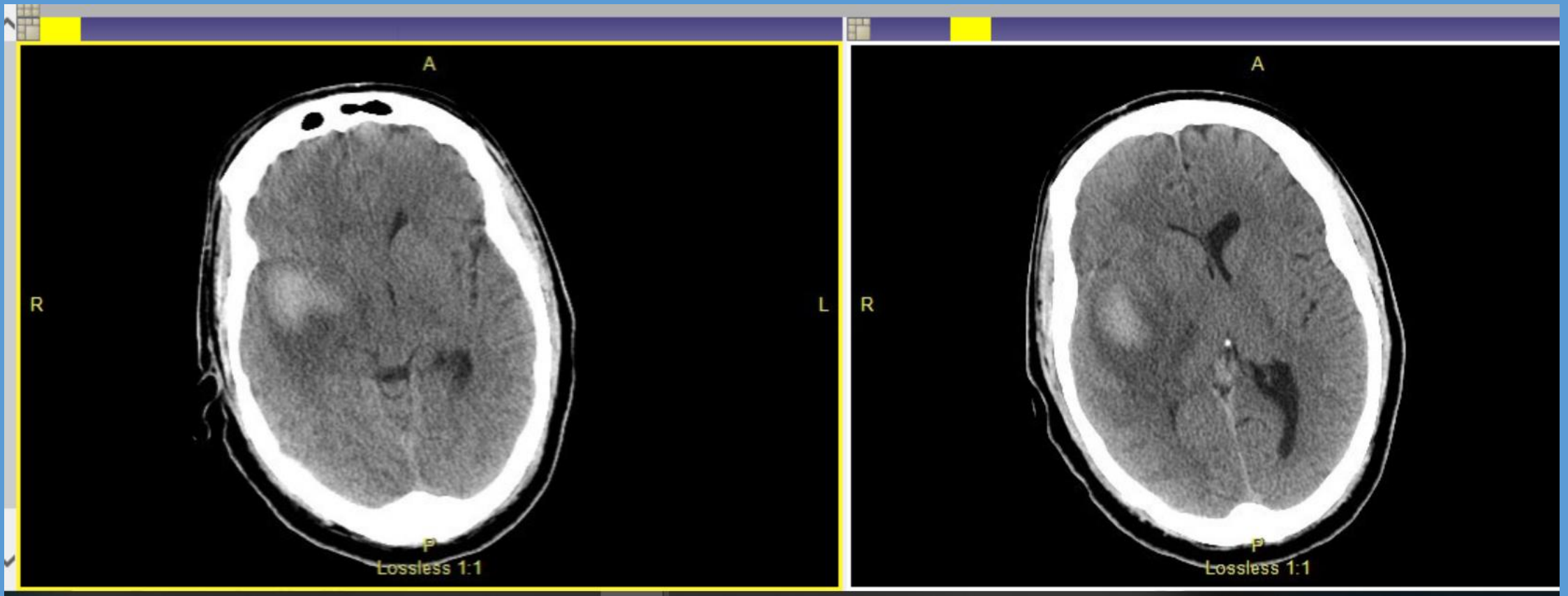
Case 2

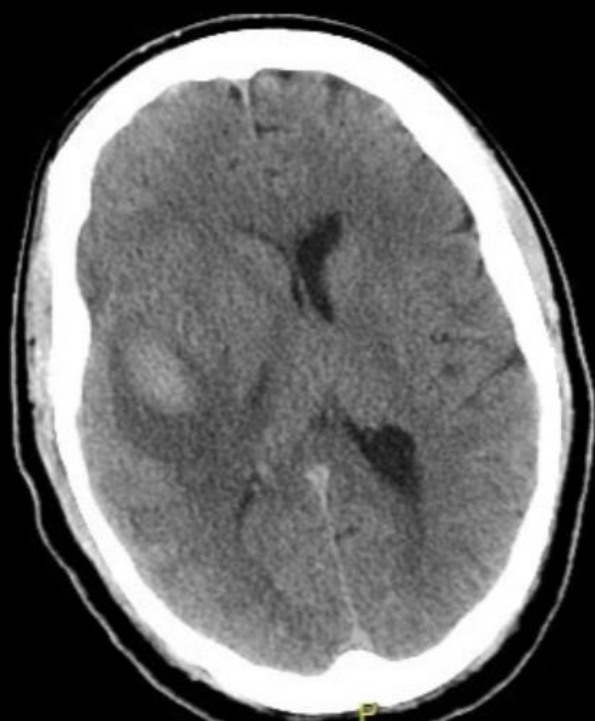- 38 yo man with 2-3 days of progressive confusion ? Maybe longer
- Loner with little health history
- UDS negative
- ? Undiagnosed schizophrenic

Exam

- L III palsy ? 6month old per his report
- Mild I hemiparesis and neglect

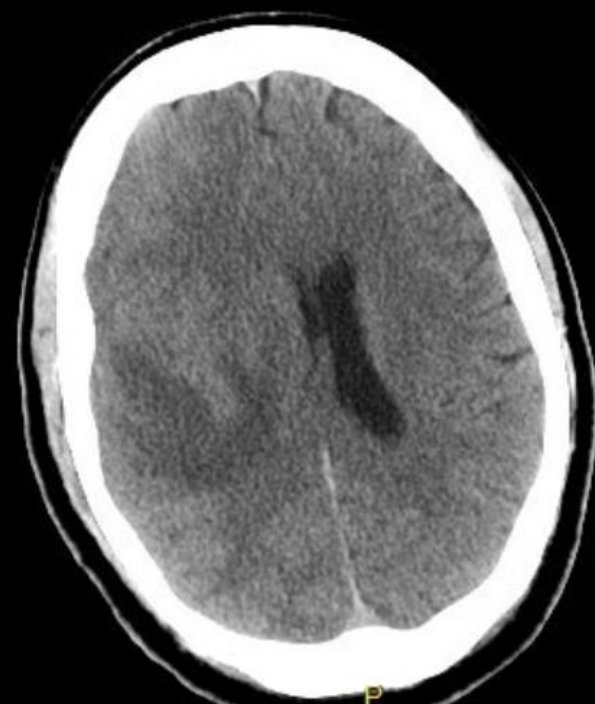Initial CT





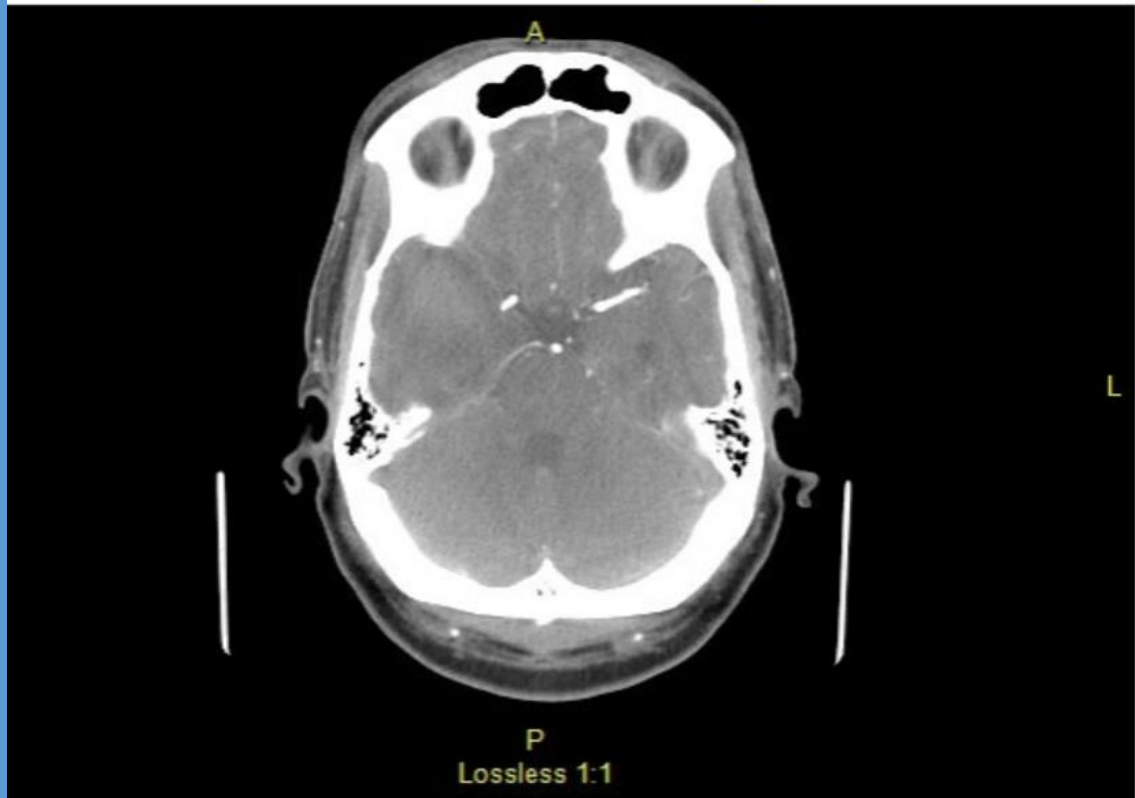
Lossless 1:1

L R



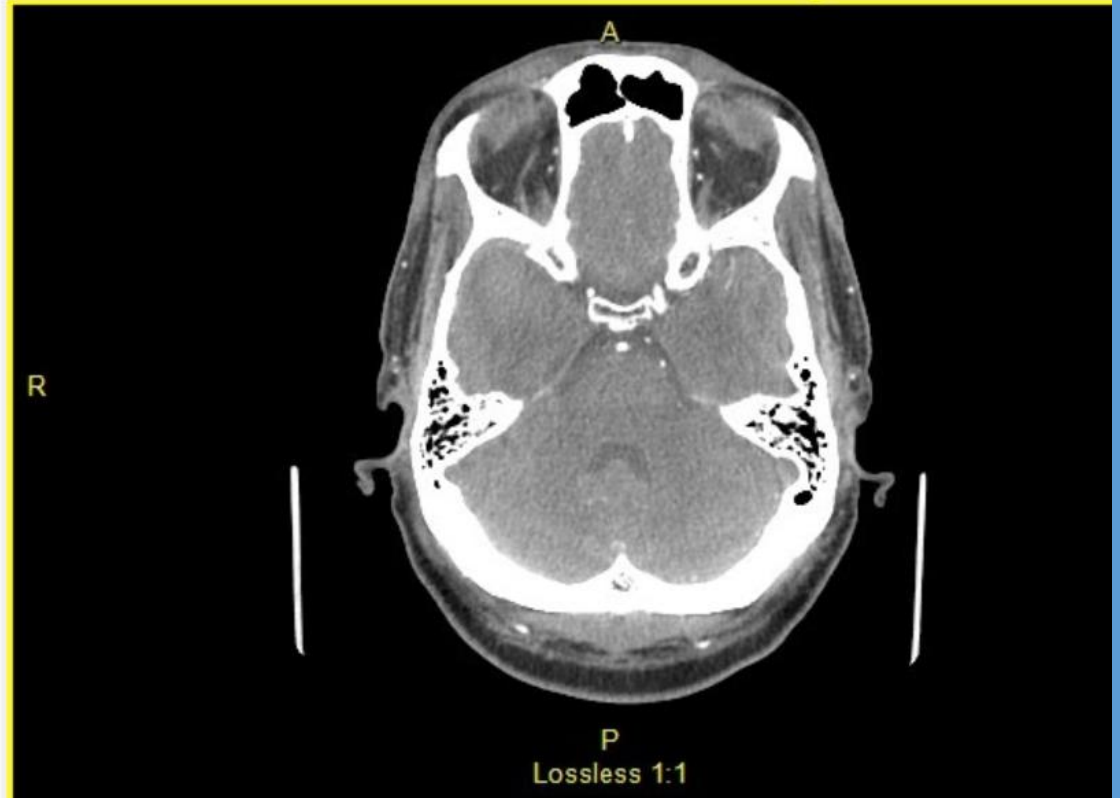Lossless 1:1

Differential?



L

R



Bilateral aneurysms

