Transcranial Doppler Protocol

Steven To, RVT, RDMS

FRIDAY - January 25, 2019

ASN 42ND ANNUAL MEETING
JANUARY 24-26, 2019

PUERTO RICO

HOUSTON
Methodist
DEBAKEY HEART &
VASCULAR CENTER

Disclosure

I, Steven To, do not have a financial interest/arrangement or affiliation with one or more organizations that could be perceived as a real or apparent conflict of interest in the context of the subject of this presentation.

Objectives

- Definition of Transcranial Doppler (TCD)
- Application
- Equipment
- Technique
- ***Protocol***
- Number values
  - Velocities/Mean flow velocities (MFV)
  - Pulsatility Index (PI)
  - Power
- Case Studies

History of TCD

HOUSTON Methodist DEBAKEY HEART & VASCULAR CENTER

- First introduced by Rune Aaslid in 1982
- Single gaited system.

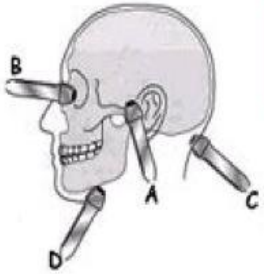

TCD Acustic "Windows"

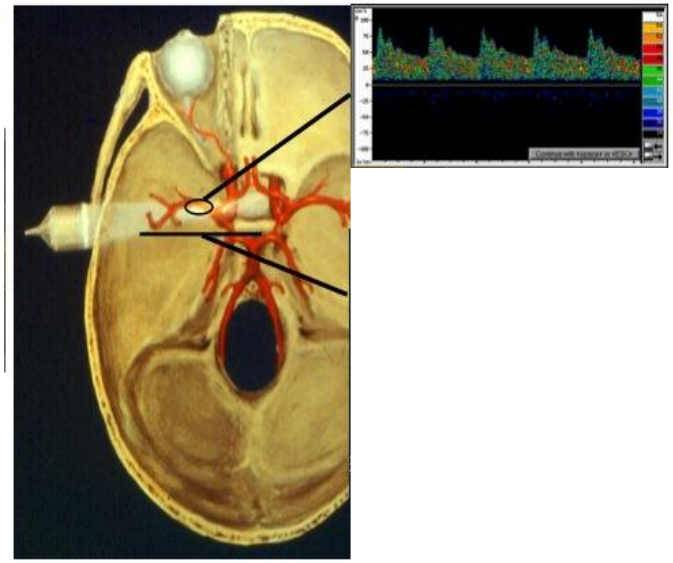

History of TCD

HOUSTON Methodist DEBAKEY HEART & VASCULAR CENTER

- Mark Moehring added power-motion mode Doppler (PMD) in 2002.
- 33 sampling gaits over 6 cm of intracranial space
- Displays flow intensity and direction

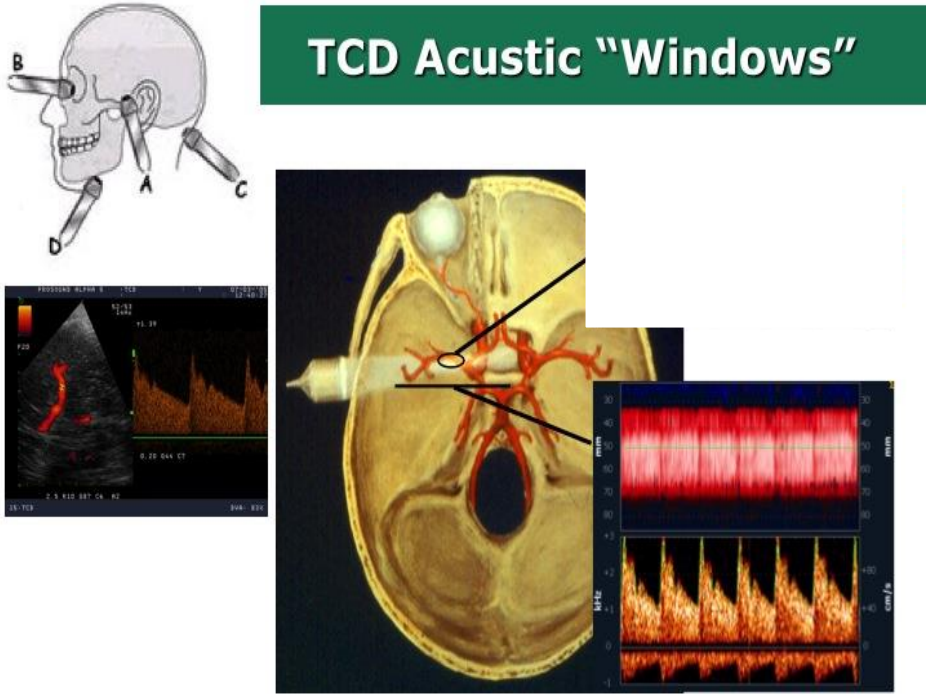

History of TCD

- This simplified and shortened testing time by making it significantly easier to find windows and waveforms.

Transcranial Doppler

- About TCD – a non-invasive, painless technique that uses ultrasound to measure the rate and direction of blood flow inside a vessel.

- TCD examines arteries part of the Circle of Willis.

Types of Doppler

What type of Doppler is TCD?

HOUSTON Methodist DEBAKEY HEART & VASCULAR CENTER

- Continuous-wave – display information representative of all moving targets in the ultrasound beam.

- Pulsed-wave – uses short bursts of ultrasound with "range gating" to facilitate signal analysis from a small area at a specified depth from the transducer.
  - TCD uses Pulsed-Wave Doppler

Applications

What can TCD be used for?

- TCD can be used to help diagnose a wide range of conditions affecting the brain, which include:
  - Cerebrovascular Accidents (CVA)
  - Transient Ischemic Attacks (TIA)
  - Embolisms
  - Circulatory Arrest
  - Subarachnoid Hemorrhage (SAH)

Applications

What can TCD be used for?

- Other applications include:
  - Vertebrobasilar Insufficiency
  - Steal phenomena in posterior circulation
  - Sickle Cell Anemia
  - Patent Foramen Ovale (PFO)
  - Cerebral vasomotor reactivity (VMR—breath holding)
  - Intraoperative monitoring

Applications

Advantages/Disadvantages

HOUSTON Methodist DEBAKEY HEART & VASCULAR CENTER

Advantages

- Non-invasive
- The only modality that can be utilized for asymptomatic microemboli /serial monitoring
- Can detect collateral circulation with carotid stenosis
- Not limited by constant patient movement

Disadvantages

- Operator dependent
- Limited by suboptimal windows



Applications

Other disadvantages

- Angle of insonation is presumed to be zero degrees.
- The skull attenuates about 80-90% of ultrasound waves
- Demographics play a role in the success of TCD
  - The elderly, females, and some ethnic origins tend to have thicker bone windows.

Billing Codes

HOUSTON Methodist DEBAKEY HEART & VASCULAR CENTER

CPT	STUDY
93886 93888	TCD complete TCD limited
93890	Vasoreactivity study
93892	Emboli detection
93893	PFO

Equipment

HOUSTON Methodist DEBAKEY HEART & VASCULAR CENTER

- Machine & wired remote
- 2 MHz transducer (hand-held)
  - Lower frequency
  - Allows for better penetration

Equipment

HOUSTON Methodist DEBAKEY HEART & VASCULAR CENTER

- Head frame & Monitoring Transducer

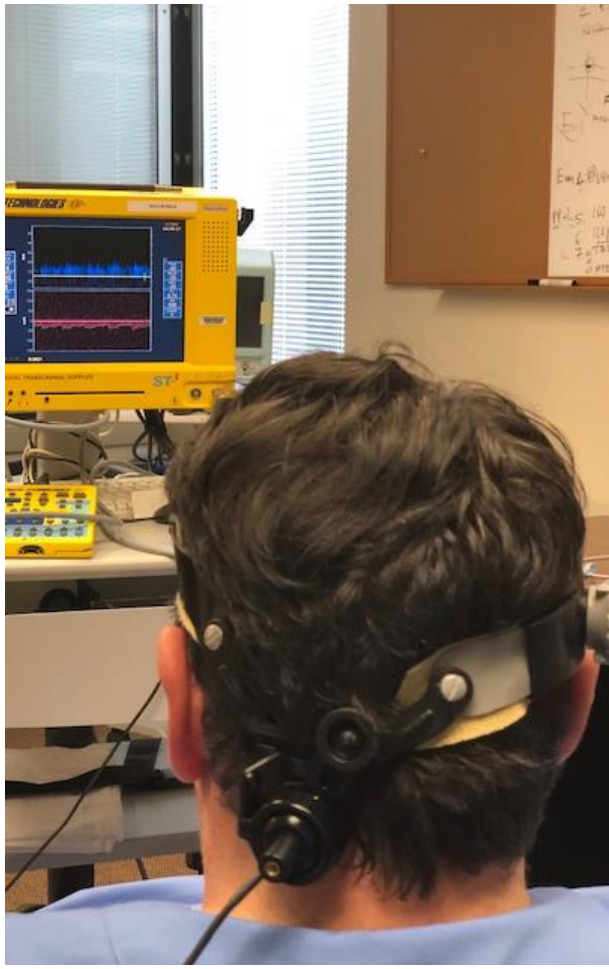

Cerebrovascular Anatomy

HOUSTON Methodist DEBAKEY HEART & VASCULAR CENTER

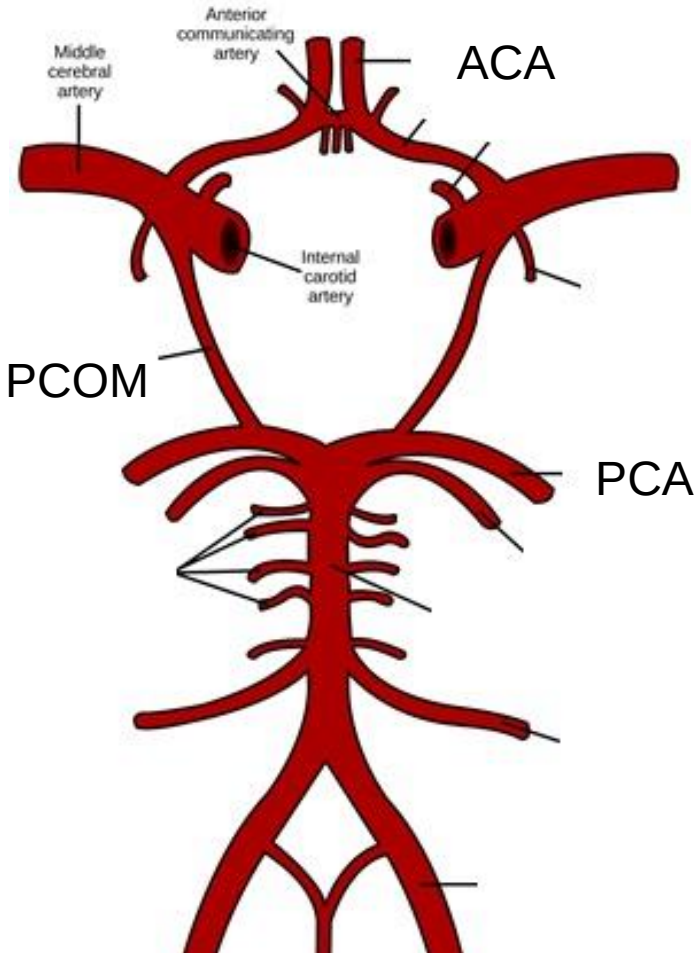

Normal Flow

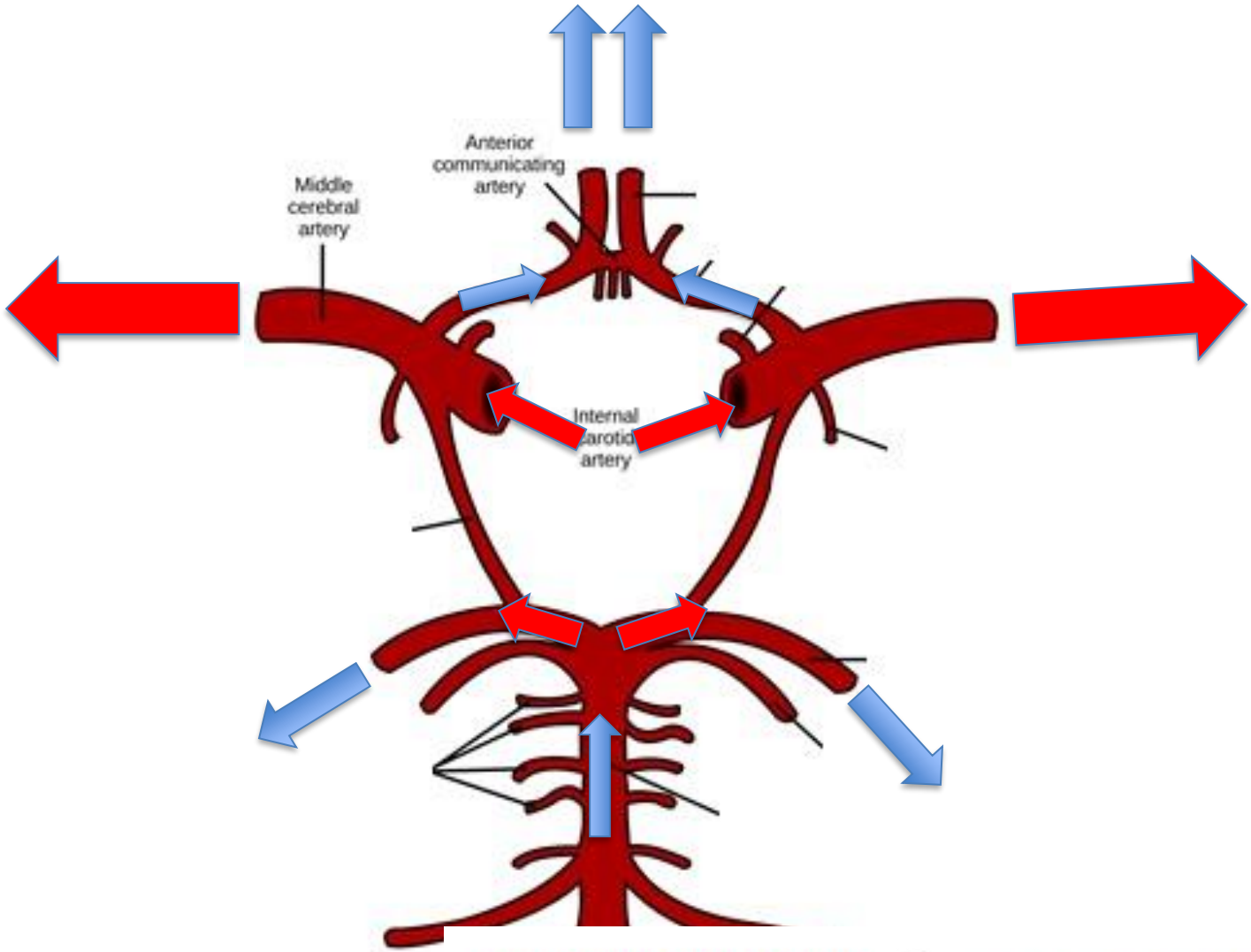
Anterior communicating artery
Middle cerebral artery
Internal carotid artery

TCD Windows

HOUSTON Methodist DEBAKEY HEART & VASCULAR CENTER

- Orbital (1)
  - Ophthalmic Artery
  - ICA Siphon
- Temporal (4)
  - MCA
  - ACA
  - PCA
  - Terminal ICA
- Foraminal/Suboccipital (3)
  - Vertebral
  - Basilar
- Submandibular (2)
  - ICA

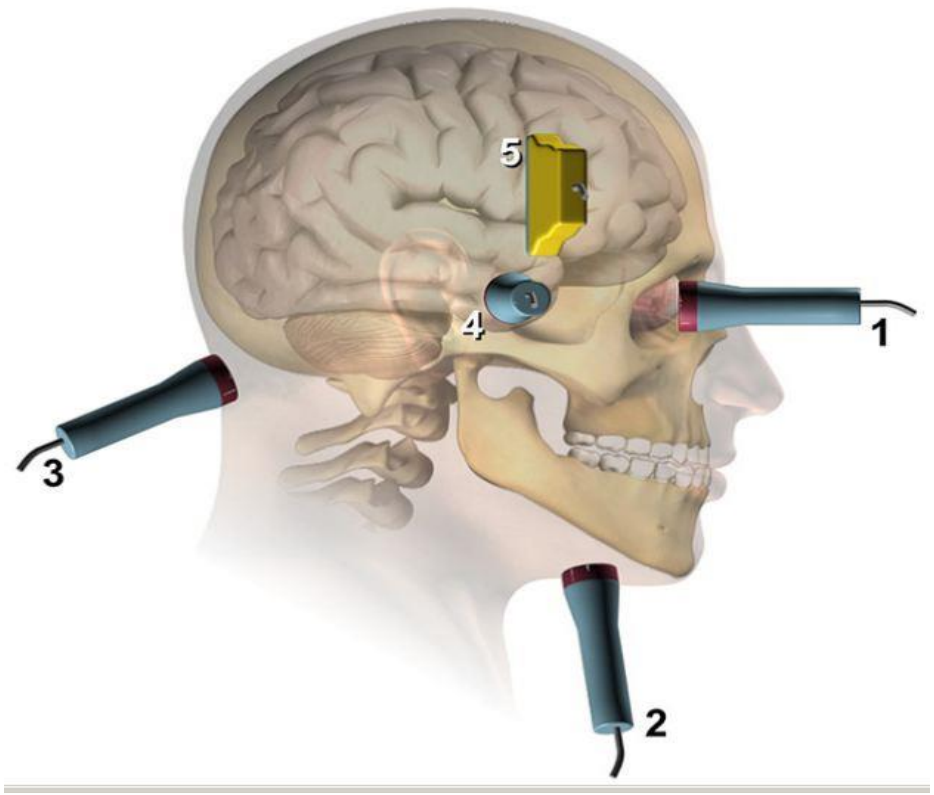

What is on the screen?

HOUSTON Methodist DEBAKEY HEART & VASCULAR CENTER

- Power M-mode
  - X-axis: Time (s)
  - Y-Axis: Depth

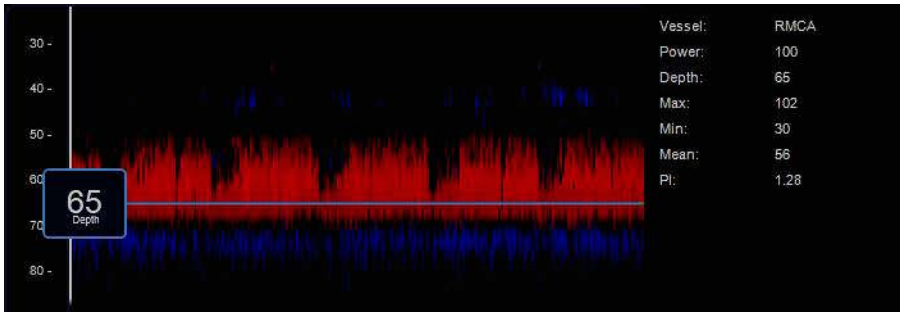

- Doppler
  - X-axis: Time (s)
  - Y-axis: Velocities (cm/s)

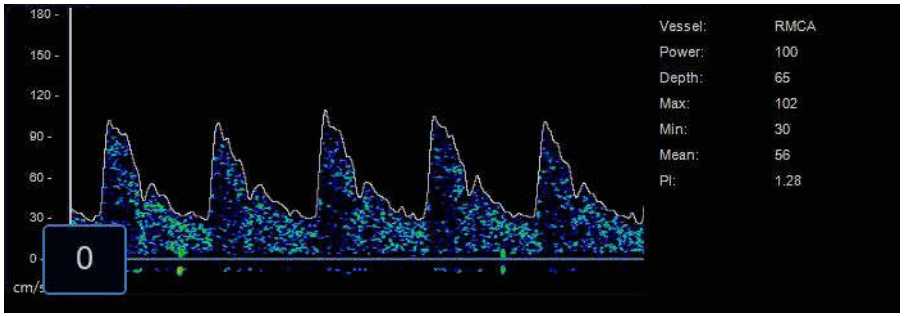

Moving the Depth/Sample

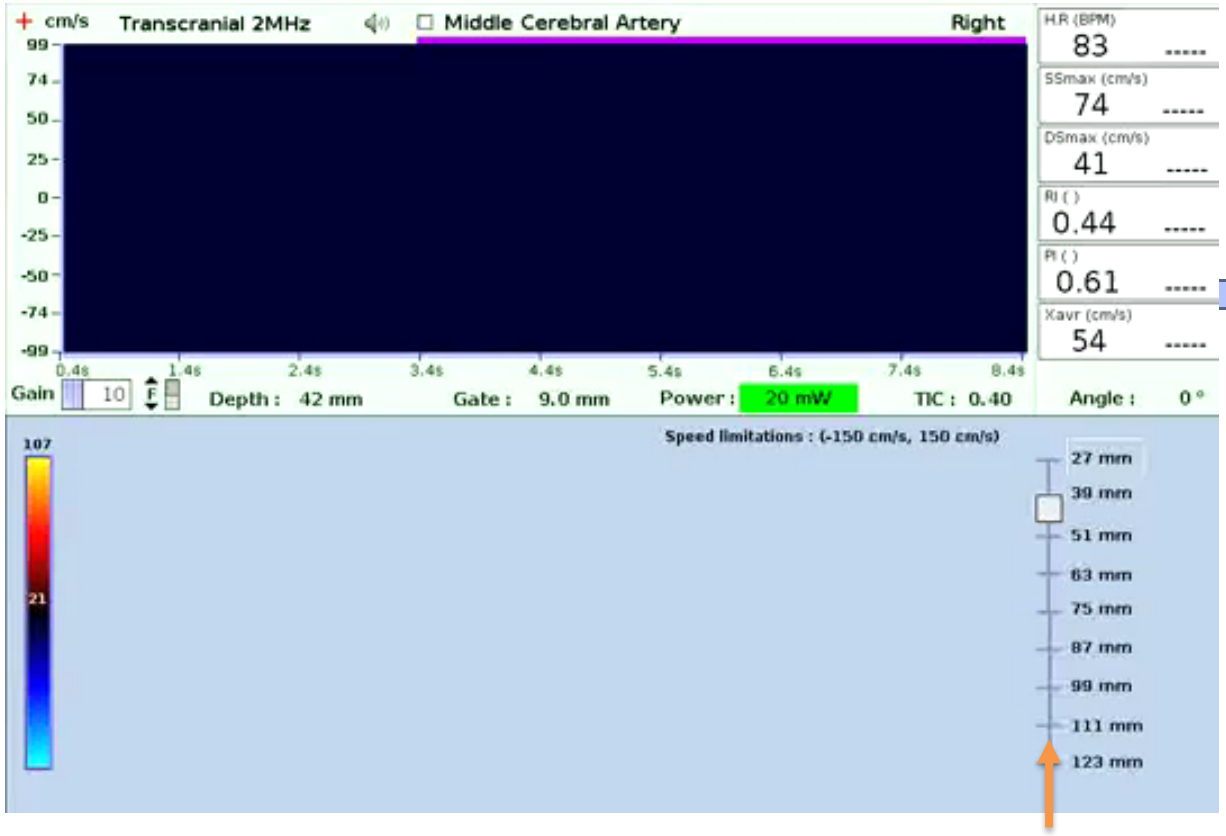

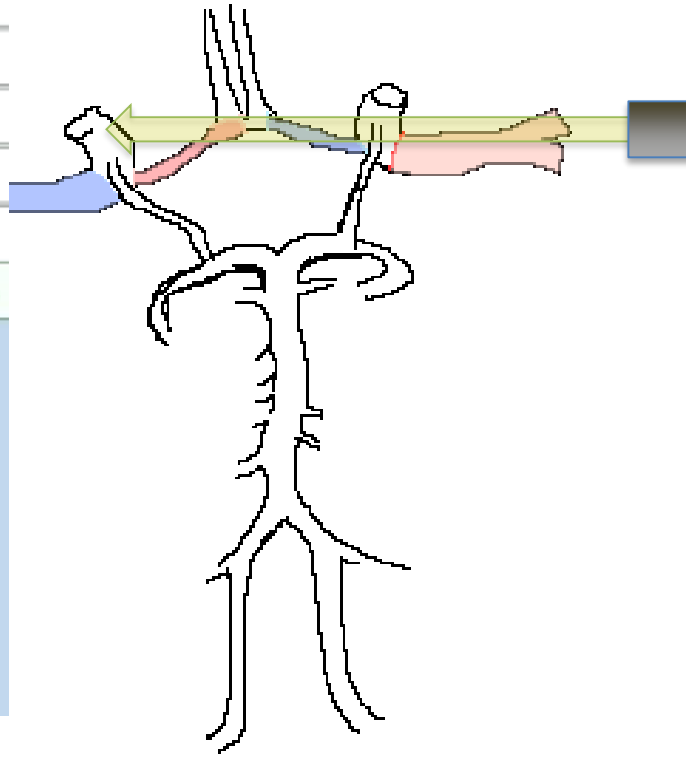

Gate Depth

Identifying Vessels

HOUSTON Methodist DEBAKEY HEART & VASCULAR CENTER

Presence

Depth

Direction

Resistance

Speed

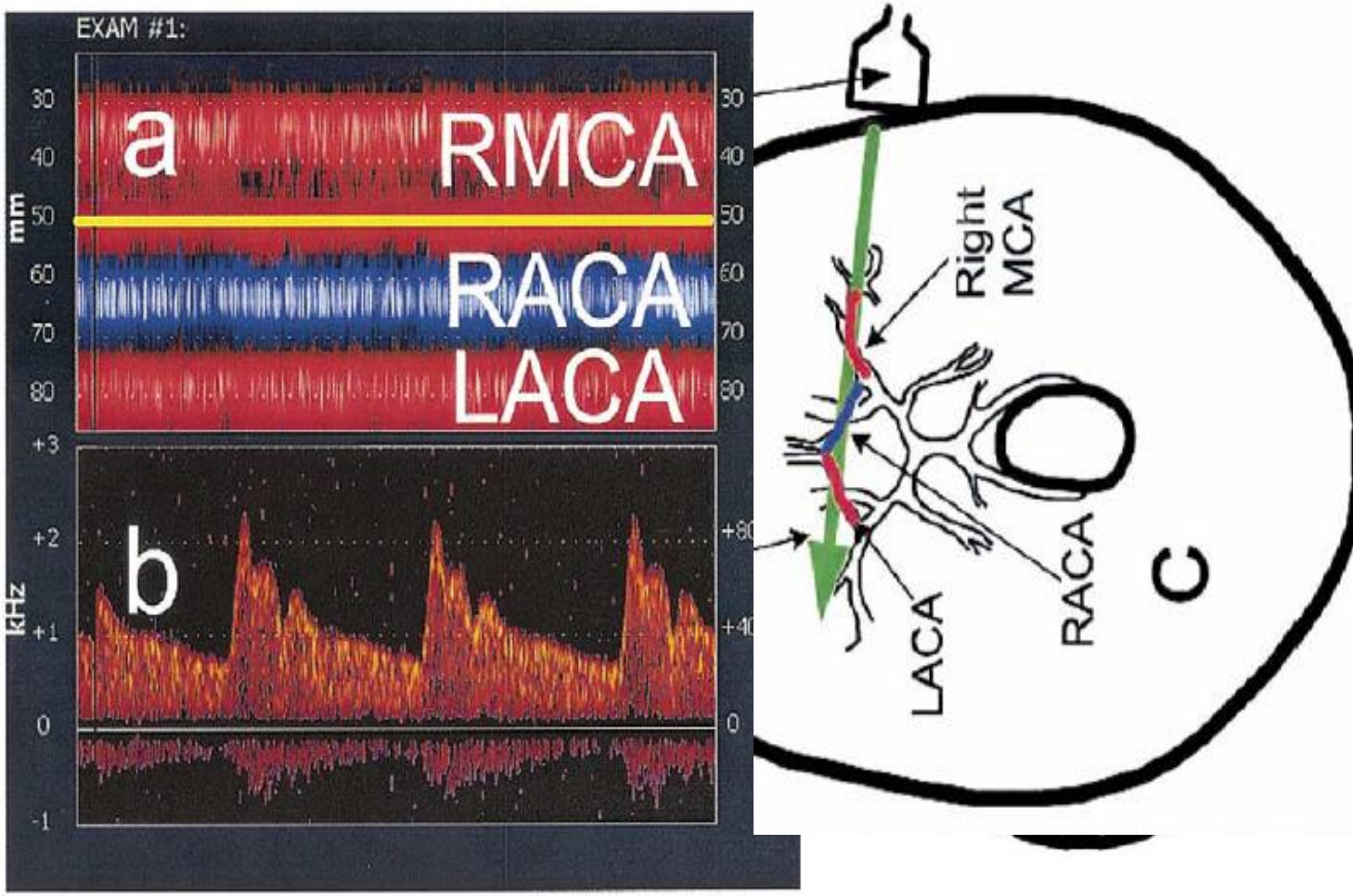

Identifying Vessels

- Window used
- Orientation of the probe
- Relationship to surrounding vessels
- Response to extrinsic occlusion

- Depth of the sample volume
- Direction of blood flow
- Velocities

Velocities

HOUSTON Methodist DEBAKEY HEART & VASCULAR CENTER

- Peak-systolic Velocity (PSV) – First peak on TCD waveform from each cardiac cycle.
  - Rapid upstroke suggests absence of severe stenotic lesion proximally

- End-diastolic Velocity (EDV) – should fall within 20-50% of the PSV; this indicates a low resistant artery, which is normal.

- Mean Flow Velocity (MFV) – A value derived from a combination of the PSV and EDV.

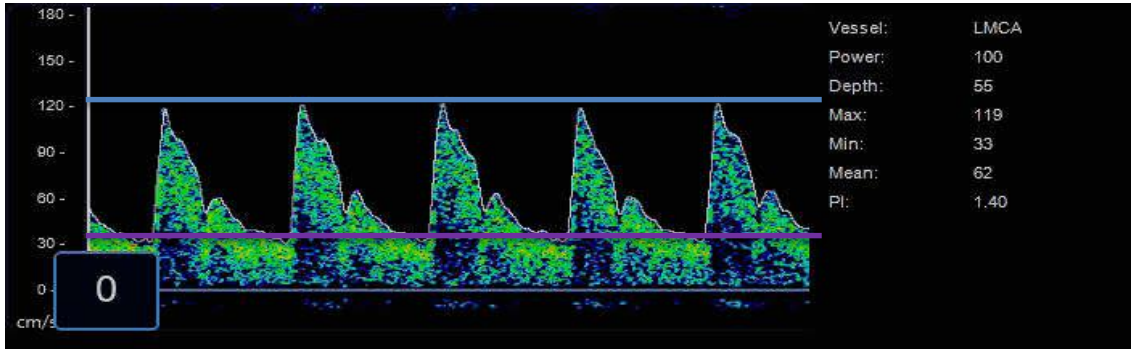

Mean Flow Velocities (MFV)

- Preferred way in reporting velocities, as it takes in consideration both PSV and EDV.

(PSV + (2)EDV) / 3

Normal Velocities

Depth, Direction, Flow

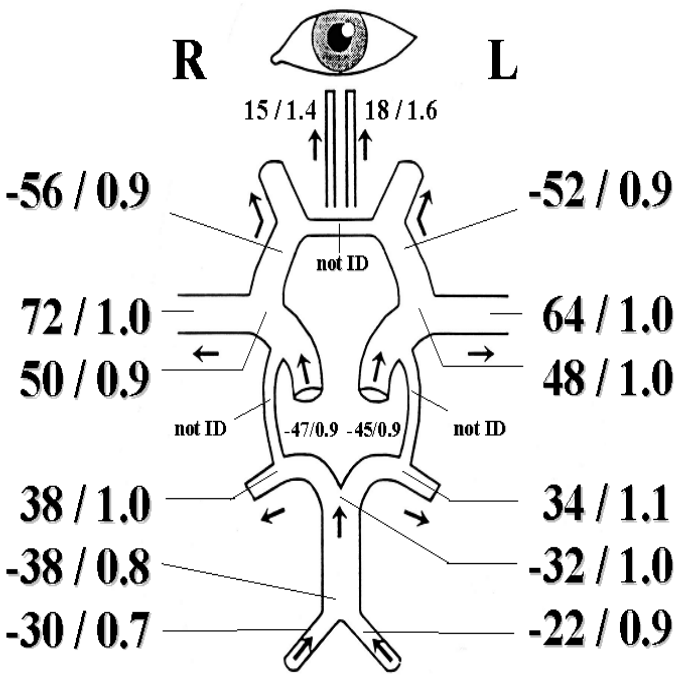

MFV MCA>ACA>Siphon>PCA>BA>VA

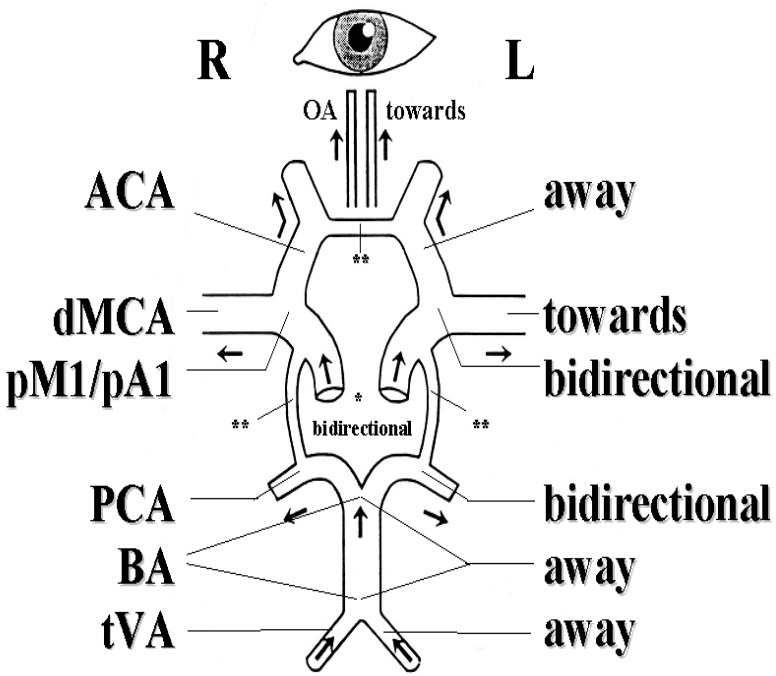

*ICA siphons have bidirectional flow signals

** AcomA and PcomA flow direction depends on collateralization

Pulsatility Index (PI)

- This is the most frequently used TCD parameter to determine the flow resistance.

(PSV – EDV) / MFV

- An index above 1.2 represents high resistant blood flow.

Pulsatility Index

HOUSTON Methodist DEBAKEY HEART & VASCULAR CENTER

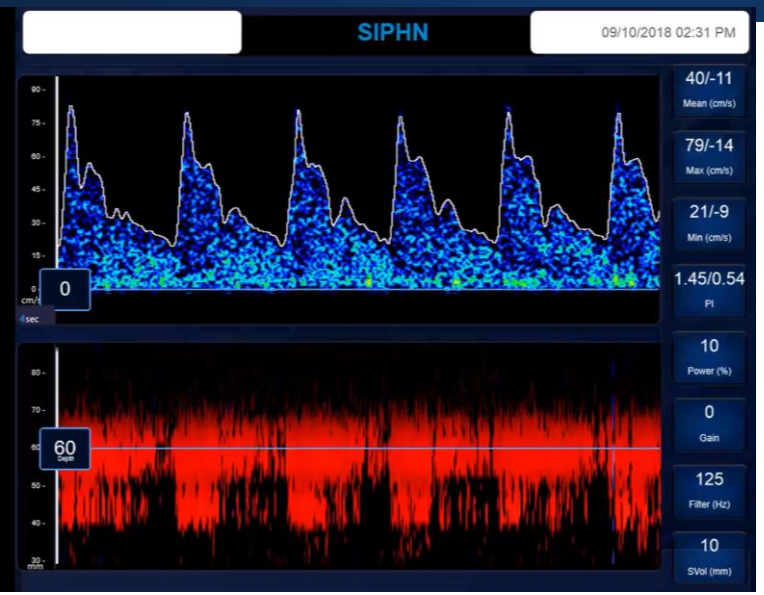

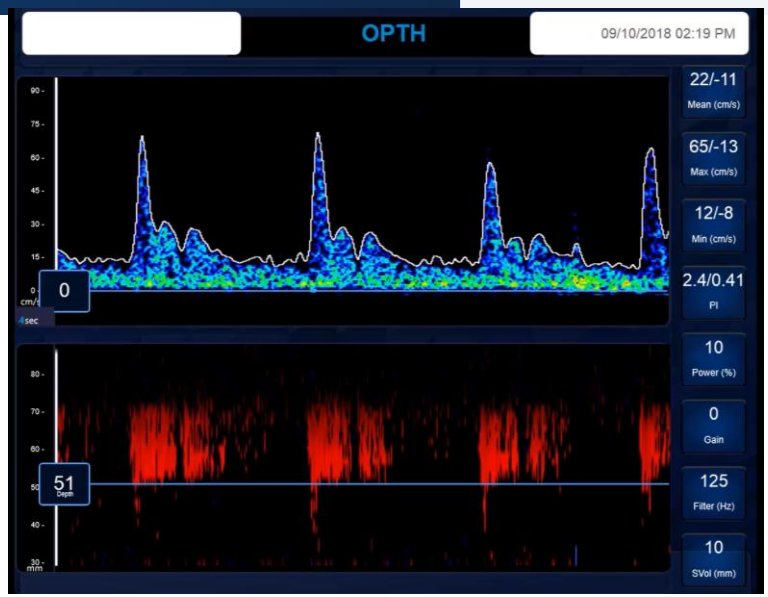

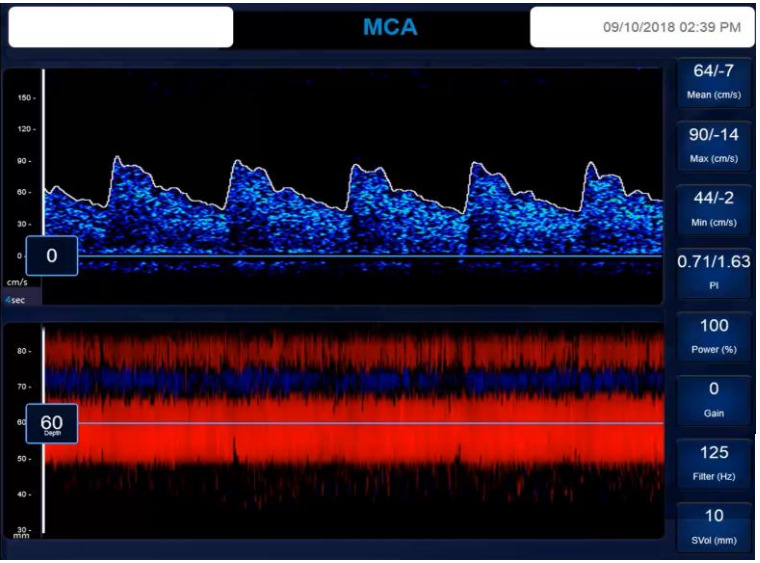

< 0.6	0.6-1.1	1.2-1.6	1.7-1.9	≥ 2.0
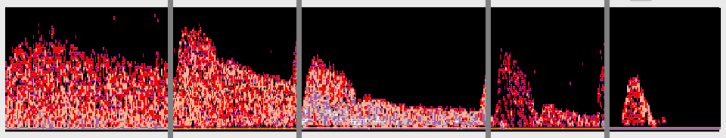				
PI = 0.3	0.7	1.2	1.7	N/A
EDV > 50%	50 - 25%	< 25%	≤ 20%	0 - 10%

Scanning/Technique

Patient Positioning

- Pt Supine
- Operator behind patient's head
- Head straight and facing up for
- OA/Siphon (10% power)

Head slightly turned to left/right

- for MCA, ACA, PCA (**100**% power)

Head turned to left/right, chin down for vertebral/basilar artery

HOUSTON Methodist DEBAKEY HEART & VASCULAR CENTER

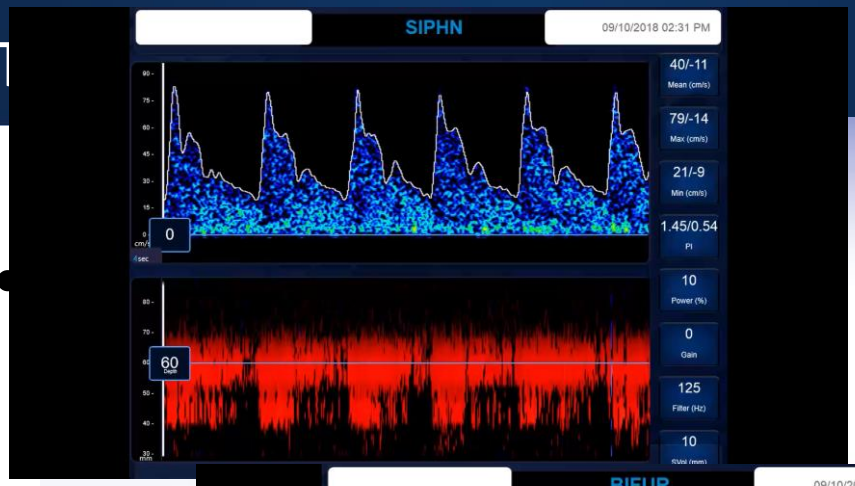

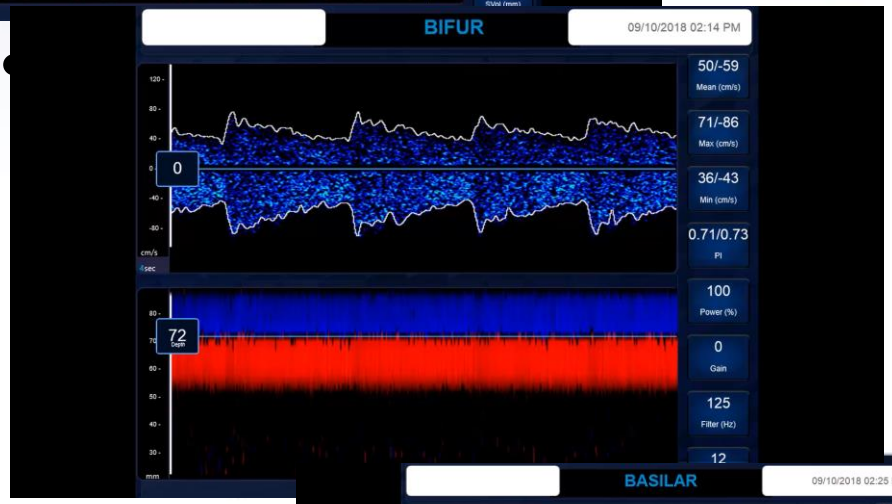

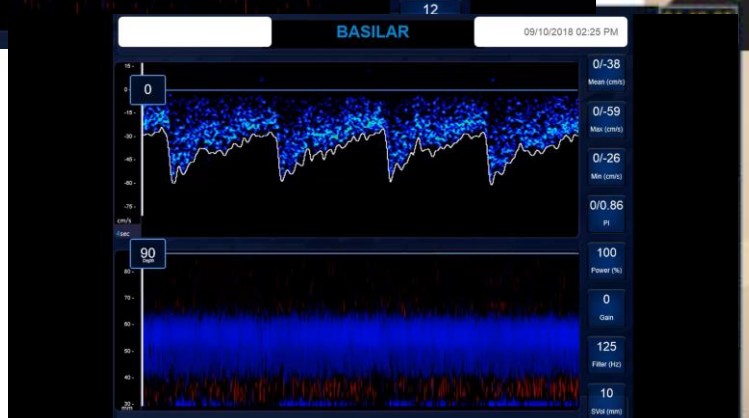

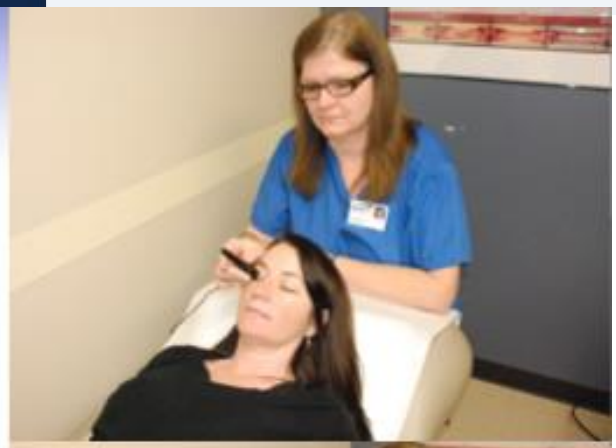

Power Settings

Safety/ALARA

HOUSTON Methodist DEBAKEY HEART & VASCULAR CENTER

- ALARA – "As Low As Reasonably Achievable"

- Be conscious of how much power you use.
  - Do not exceed 10% maximum emitted power or 17 mW per cm^2 while working in the ophthalmic window.
  - New standards suggest using 80% power while working on other windows.

Gain Settings

HOUSTON Methodist DEBAKEY HEART & VASCULAR CENTER

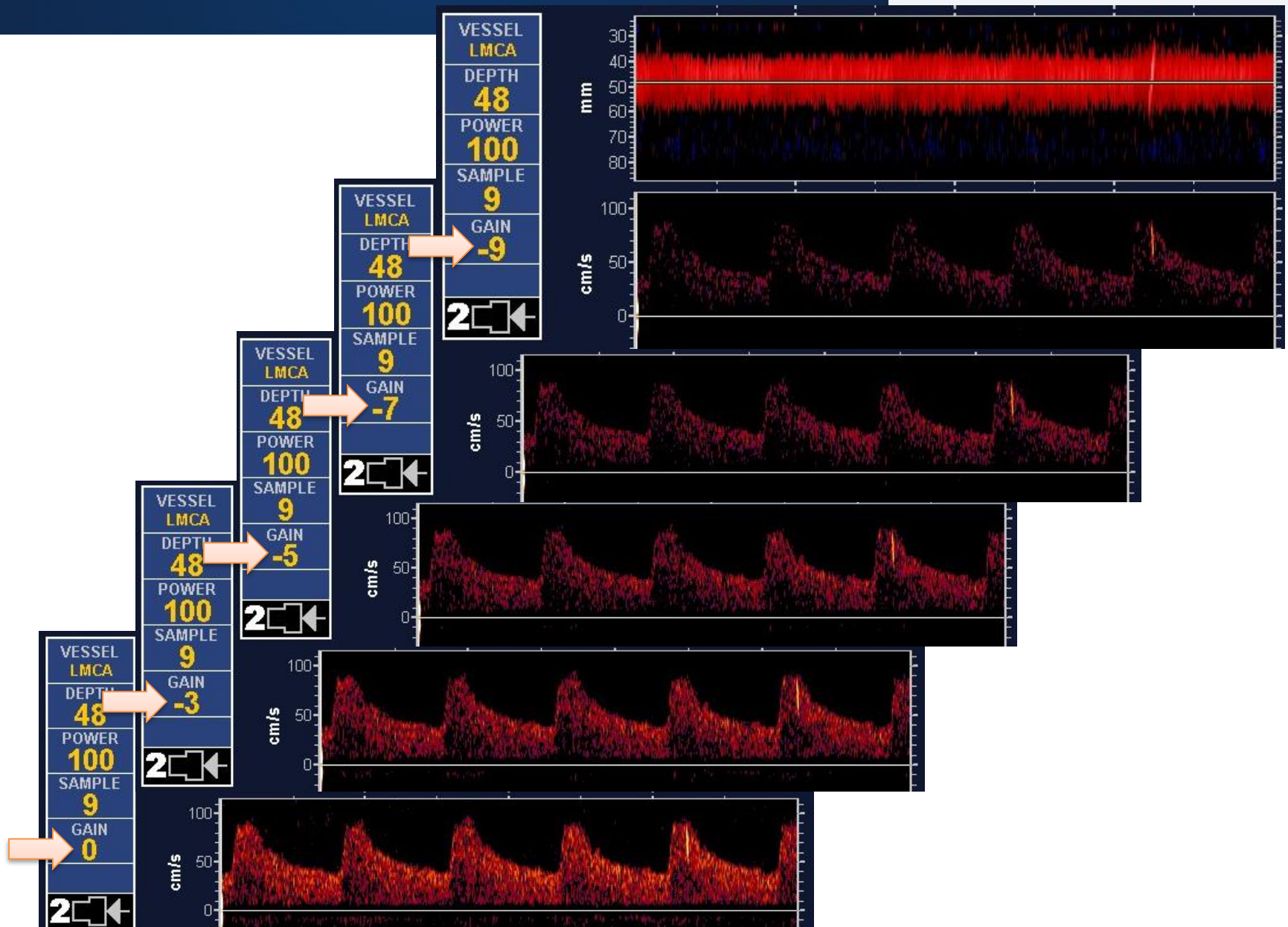

Protocol

Complete TCD Protocol

ASN 42ND ANNUAL MEETING
JANUARY 24-26, 2019

PUERTO RICO

HOUSTON
Methodist
DEBAKEY HEART &
VASCULAR CENTER

Protocol

HOUSTON Methodist DEBAKEY HEART & VASCULAR CENTER

- Ophthalmic Window
  - 1.) Rt Ophthalmic Artery
  - 2.) Rt Siphon
  - 3 & 4.) Repeat on Lt

- Temporal Window
  - 5.) Rt MCA
  - 6.) Rt ACA
  - 7.) Rt PCA
  - 8.) Rt Terminal ICA
  - 9 to 12.) Repeat on Lt

- Suboccipital Window
  - 13.) Rt Vert
  - 14.) Basilar A
  - 15.) Lt Vert

- If Necessary,
  - 16 & 17.) Submandibular ICA (for SAH).

Vessel Identification

HOUSTON Methodist DEBAKEY HEART & VASCULAR CENTER

Vessel	Depth (mm)	Flow orientation to Probe
Opthalmic Artery	50	Toward (High Res)
ICA Siphon	**65**	Bidirectional
MCA (M1)	45 to **65**	Toward
ACA	**65** to 70	Away
P2	60 to **65**	Away
Vertebral	60 to **65**	Away
Basilar	80 to 100	Away

Ophthalmic Artery (50 mm)

HOUSTON Methodist DEBAKEY HEART & VASCULAR CENTER

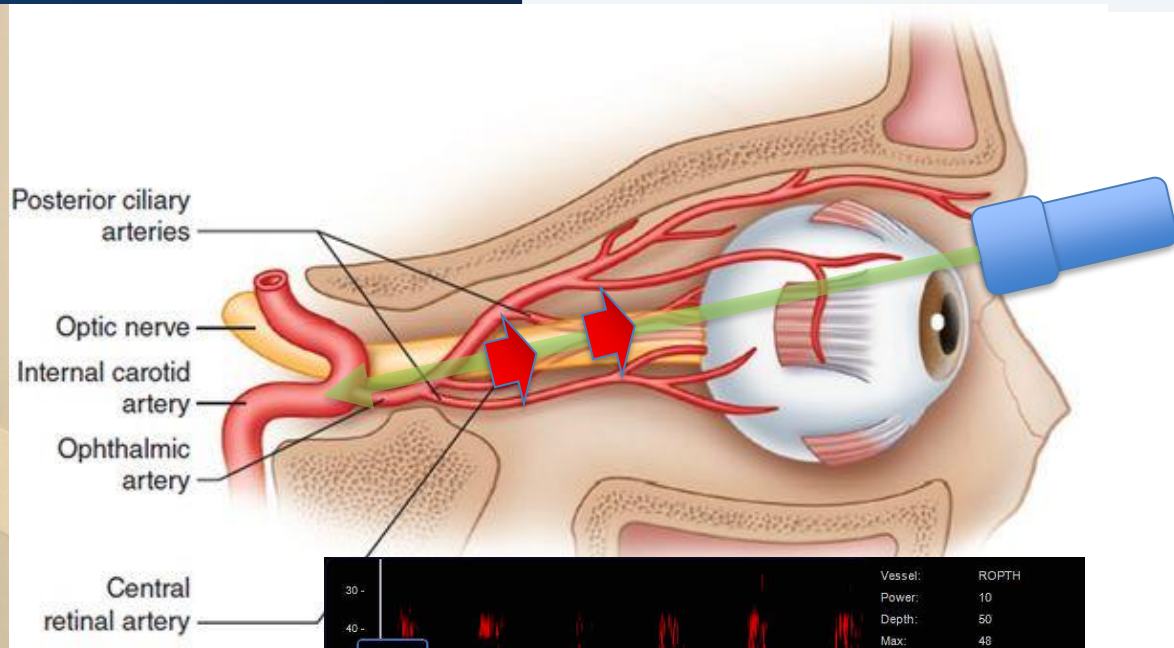

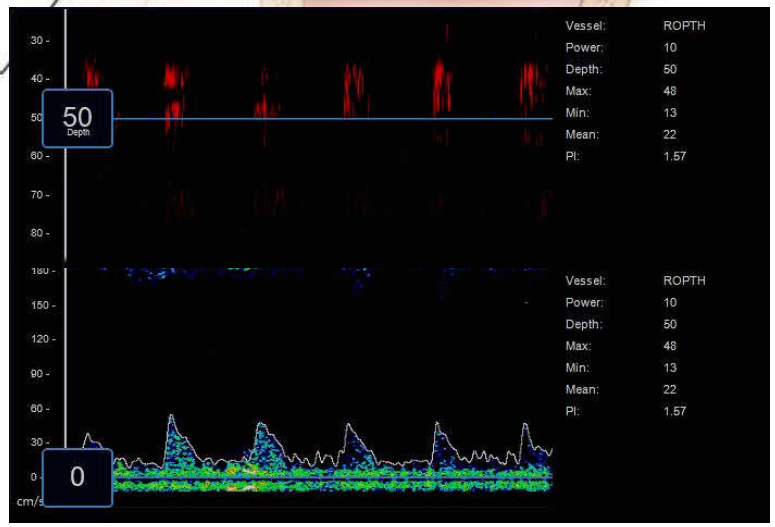

Siphon (65 mm)

HOUSTON Methodist DEBAKEY HEART & VASCULAR CENTER

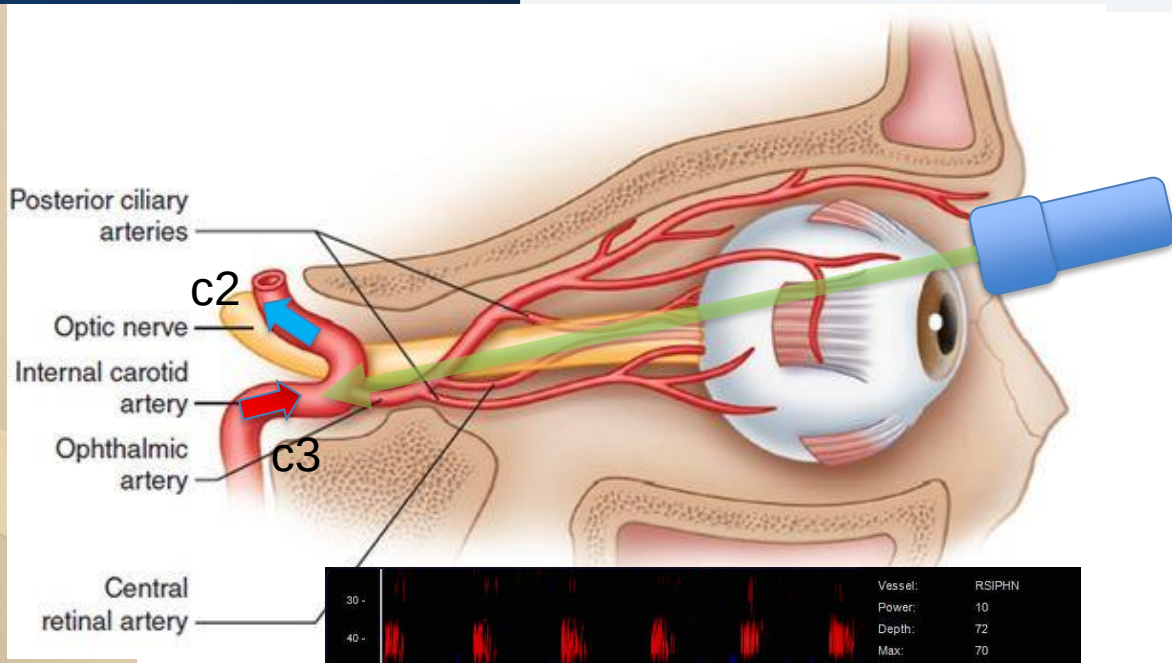

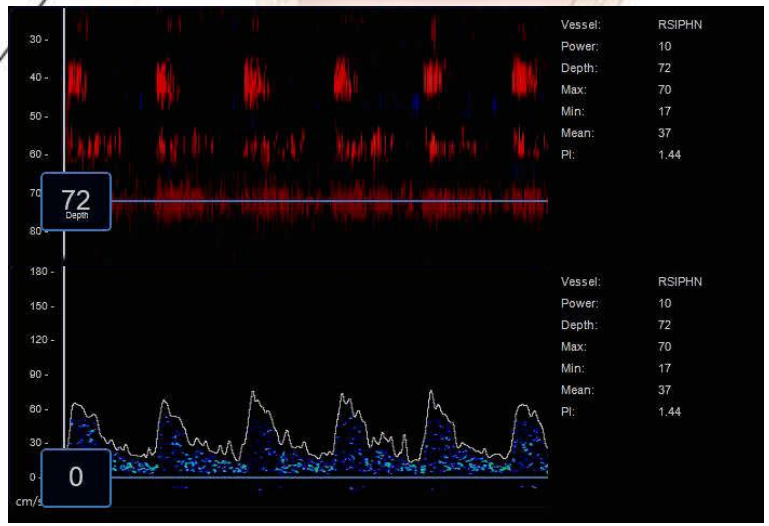

MCA (45–65 mm)

HOUSTON Methodist DEBAKEY HEART & VASCULAR CENTER

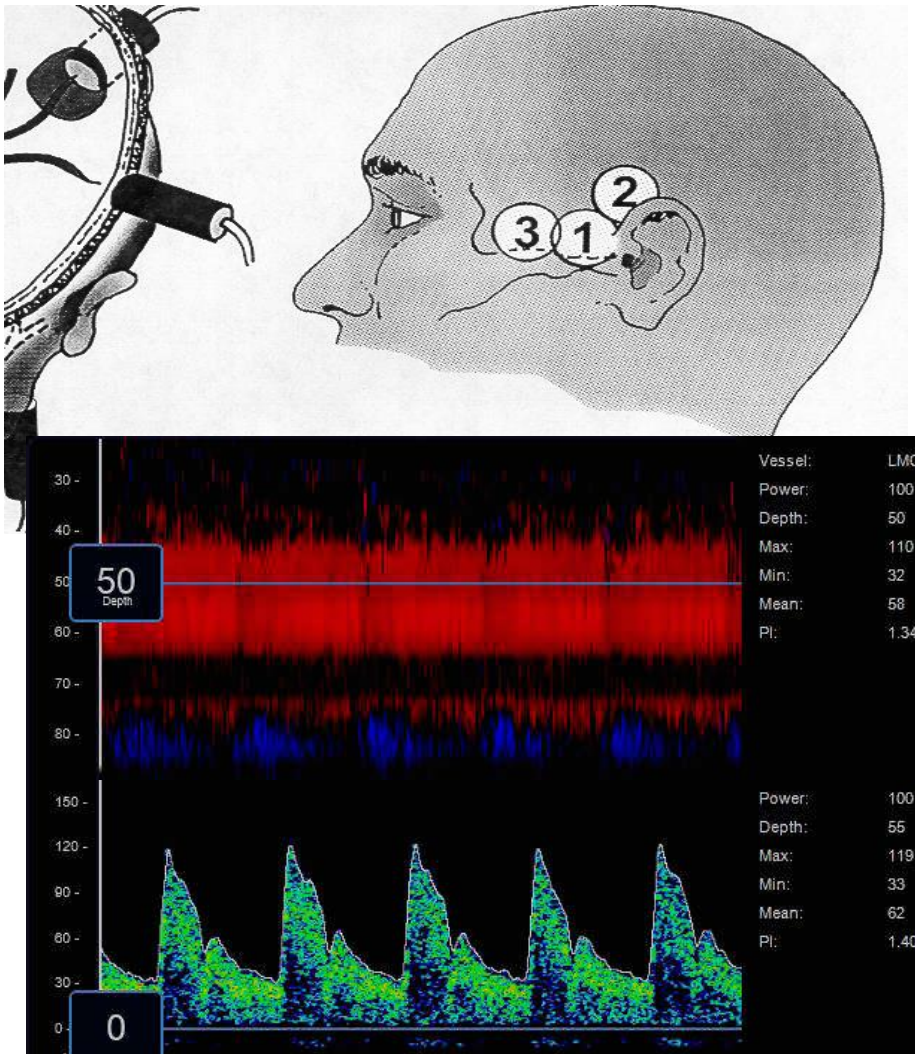

ACA (65–70 mm)

HOUSTON Methodist DEBAKEY HEART & VASCULAR CENTER

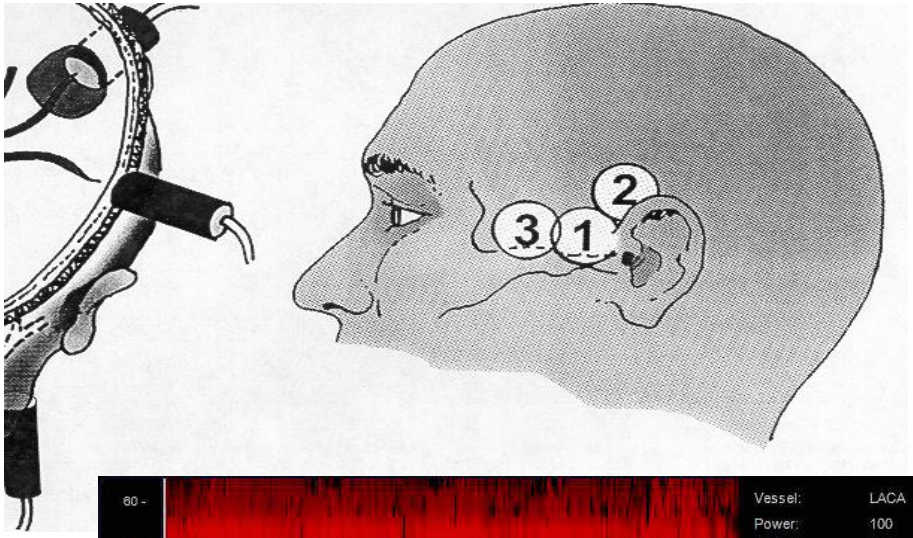

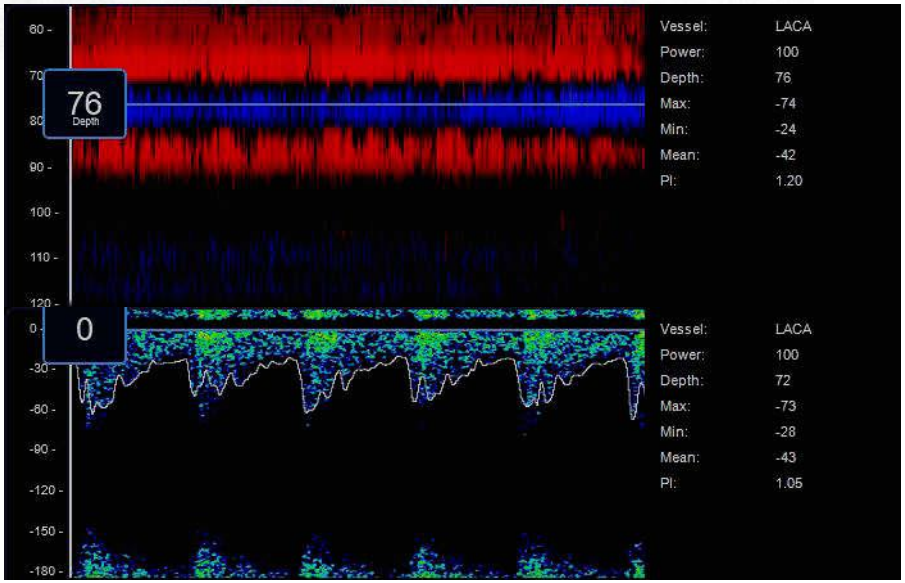

PCA (60-65 mm)

HOUSTON Methodist DEBAKEY HEART & VASCULAR CENTER

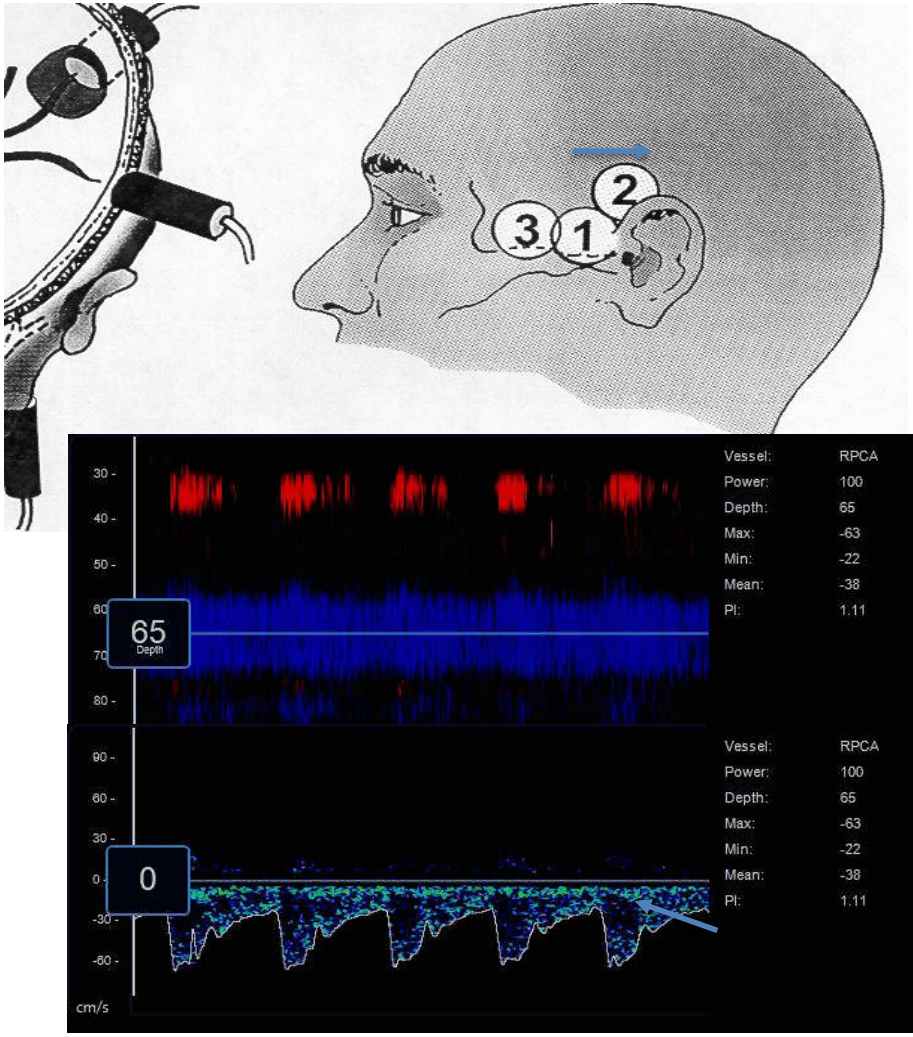

Vertebral (65 mm)

HOUSTON Methodist DEBAKEY HEART & VASCULAR CENTER

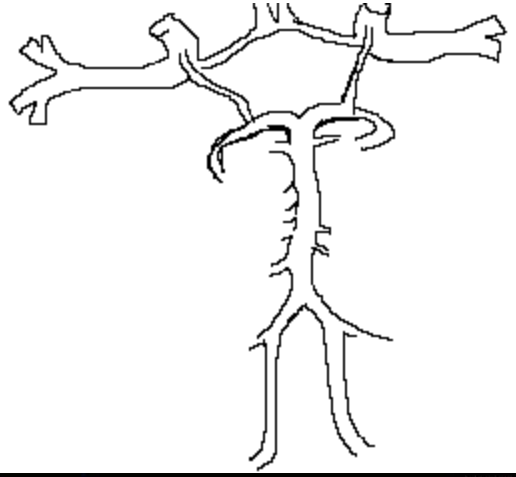

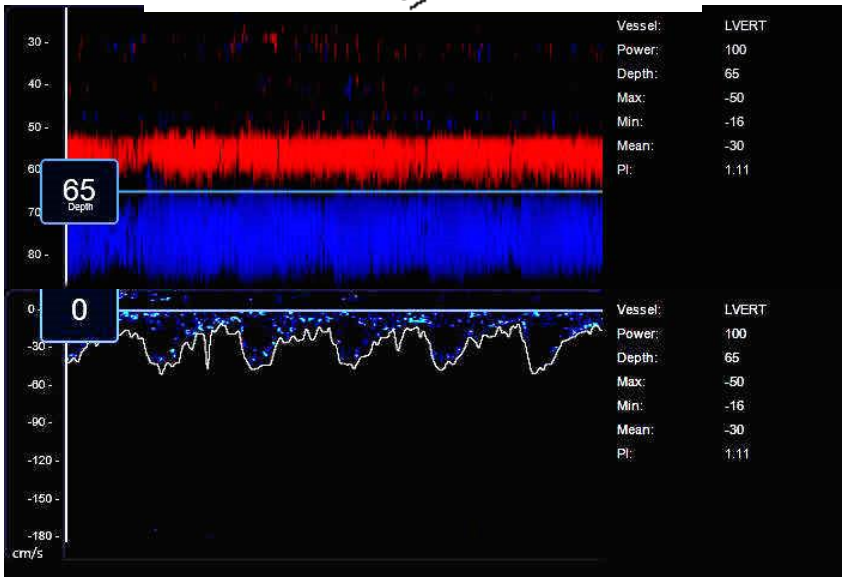

Basilar (80-100 mm)

HOUSTON Methodist DEBAKEY HEART & VASCULAR CENTER

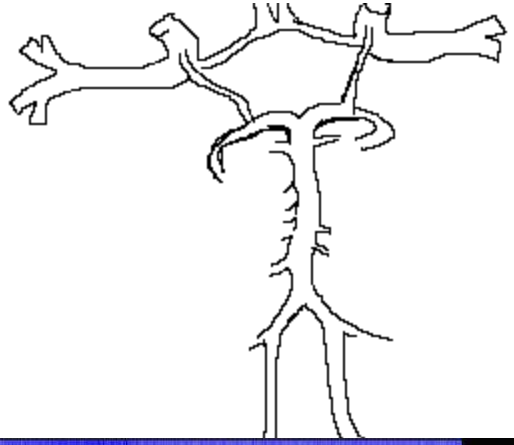

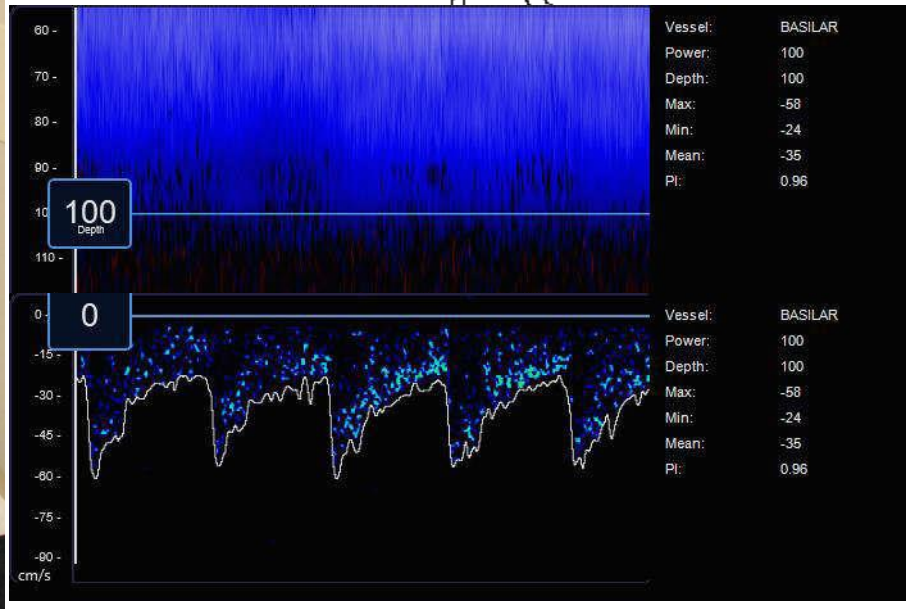

Submandibular ICA

HOUSTON Methodist DEBAKEY HEART & VASCULAR CENTER

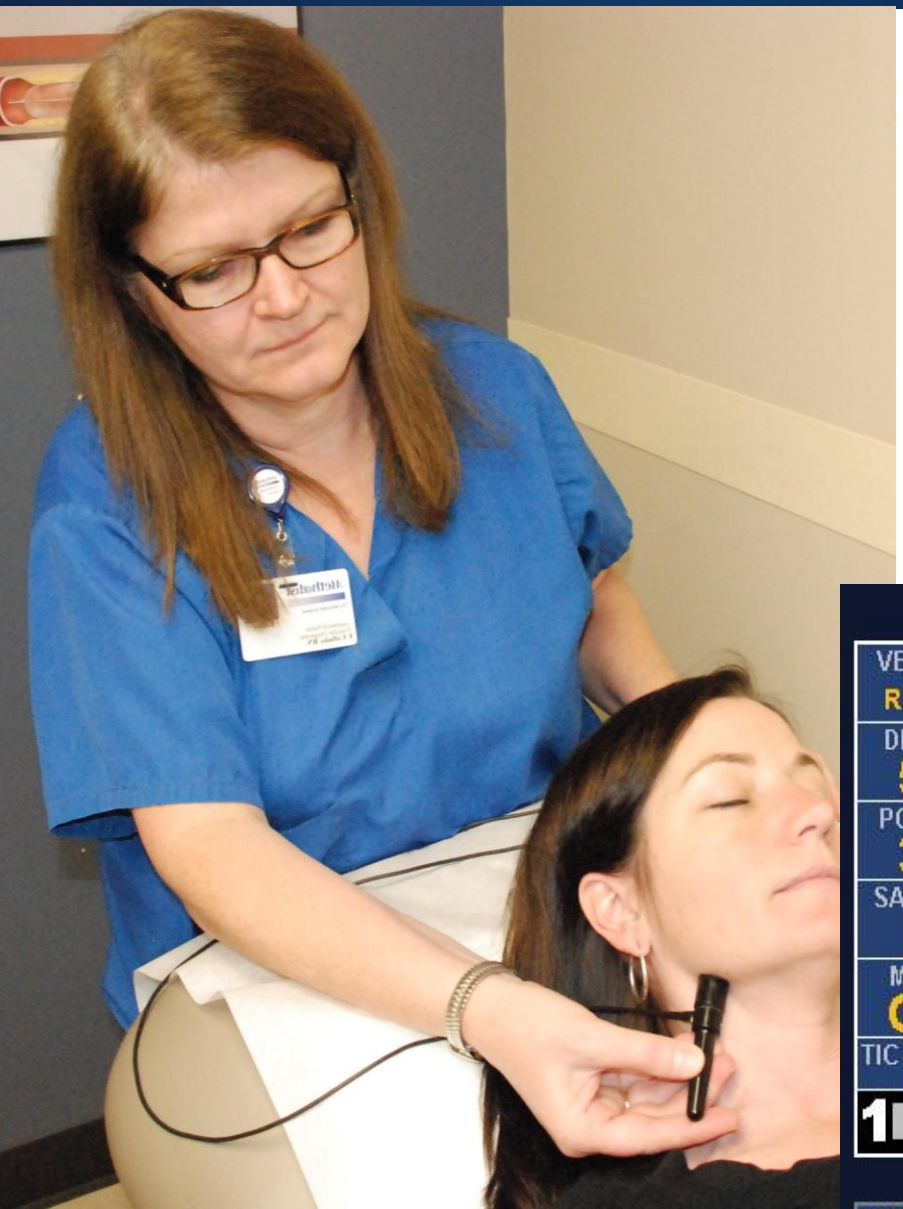

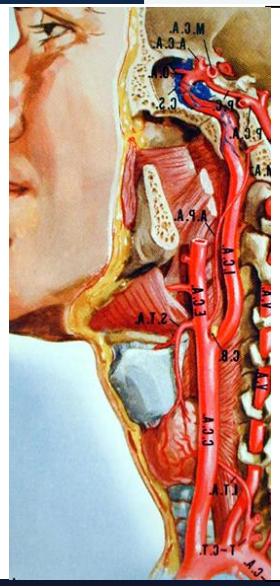

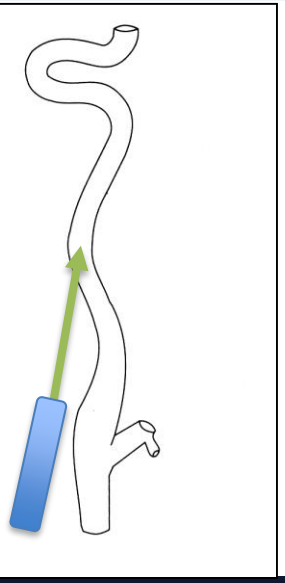

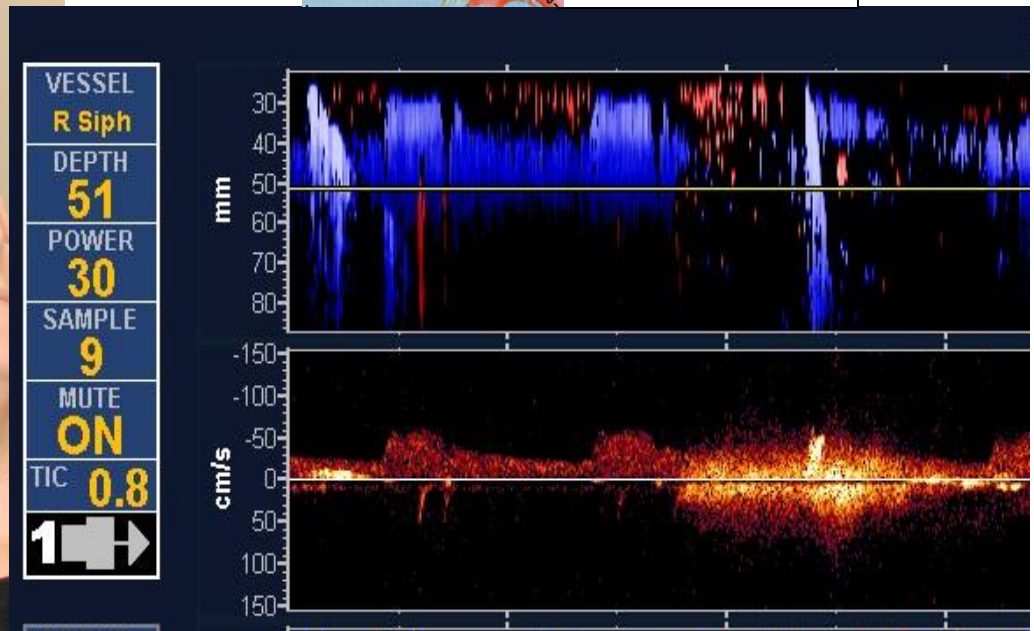

Suboptimal Temporal Window

HOUSTON Methodist DEBAKEY HEART & VASCULAR CENTER

- In the event you have unilateral optimal temporal window, it's possible to shoot through the good window to get the signals on the other side of the head.

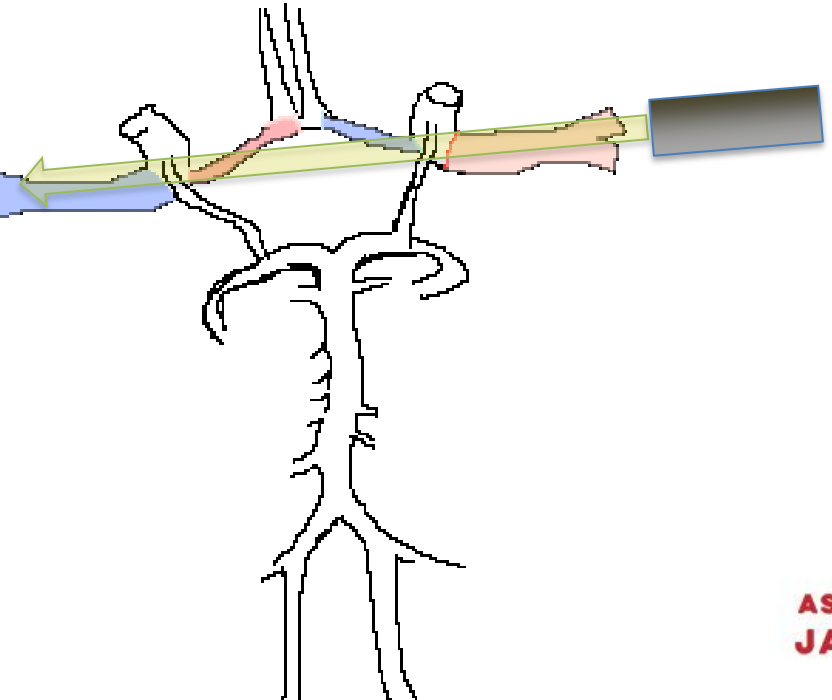

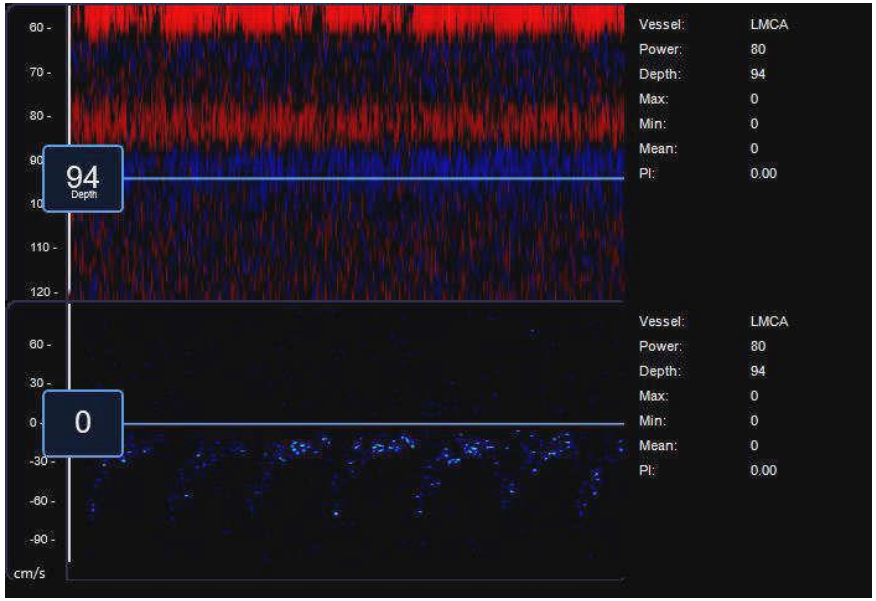

Case Studies

Pathology & What to Expect

ASN 42ND ANNUAL MEETING
JANUARY 24-26, 2019

PUERTO RICO

HOUSTON
Methodist
DEBAKEY HEART &
VASCULAR CENTER

High grade carotid stenosis or occlusion

- Carotid occlusive disease cuts off efficient flow to the ipsilateral MCA.

- Bloodflow is redirected to the affected MCA via available collaterals:
  - Anterior communicating artery
  - Posterior communicating artery

- Higher velocities in compensating arteries
- Usually retrograde flow in ipsilateral ACA
- Blunted/Abnormal signals in affected MCA

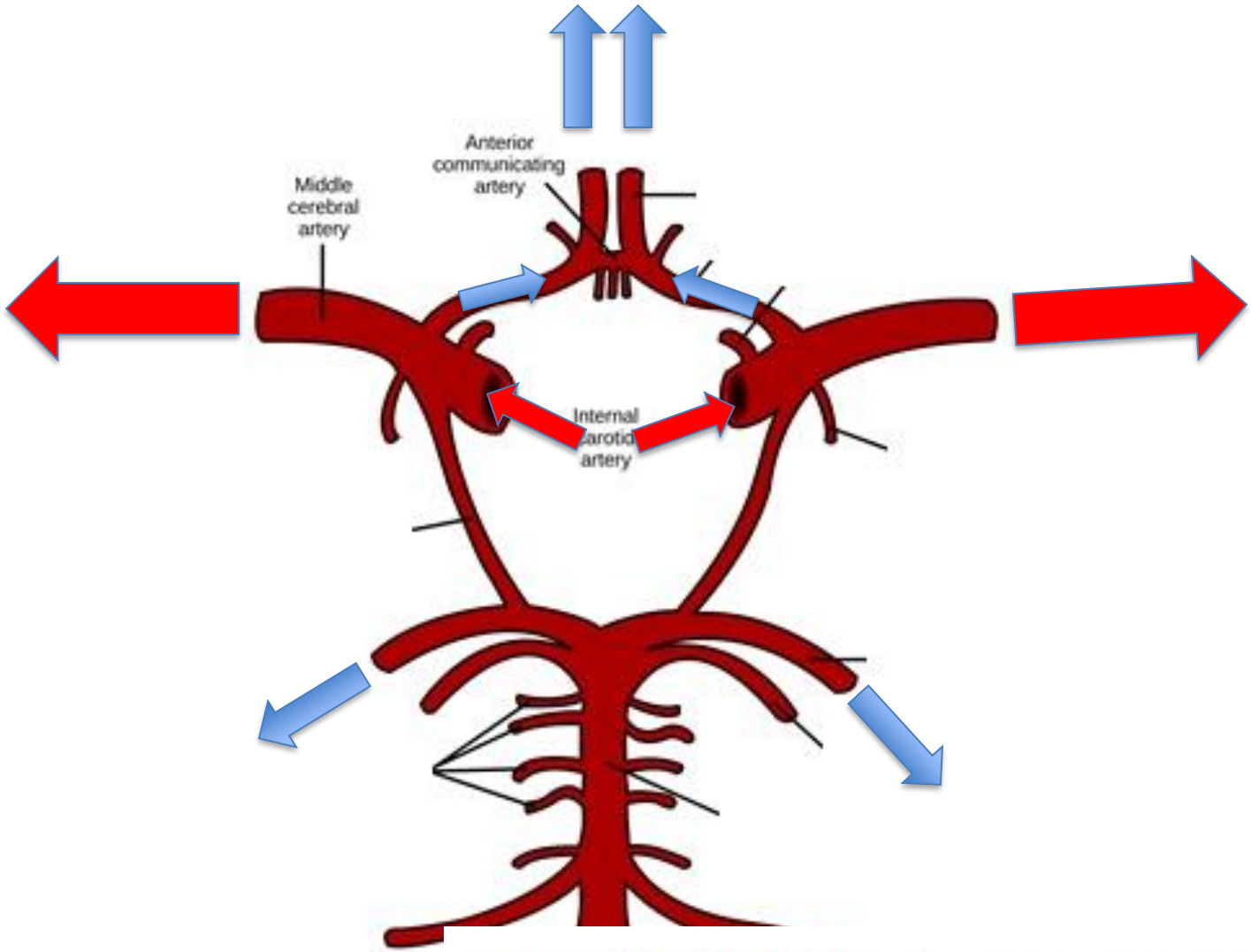
Anterior communicating artery
Middle cerebral artery
Internal carotid artery

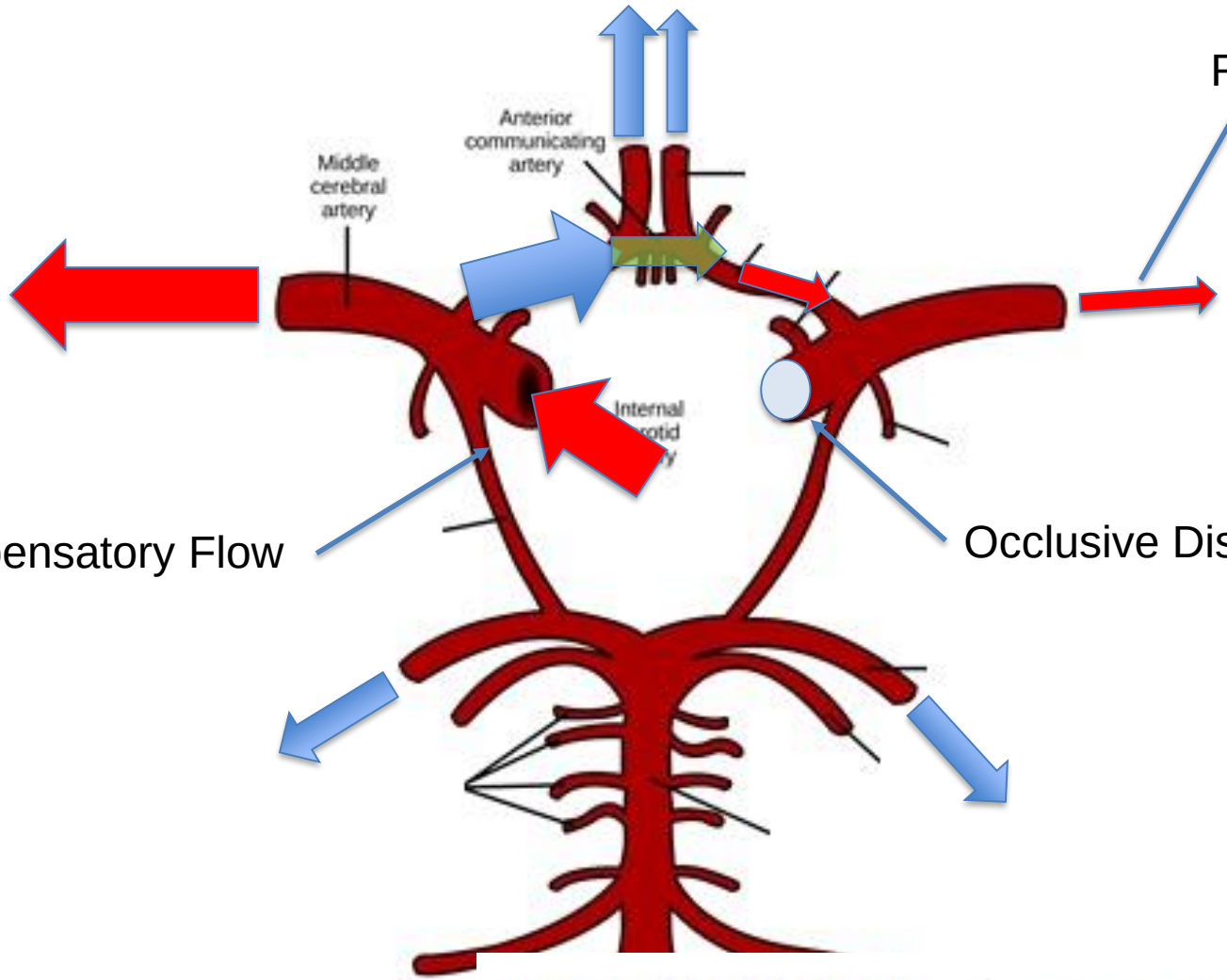
Reduced Flow
Anterior communicating artery
Middle cerebral artery
Internal
Compensatory Flow
Occlusive Disease

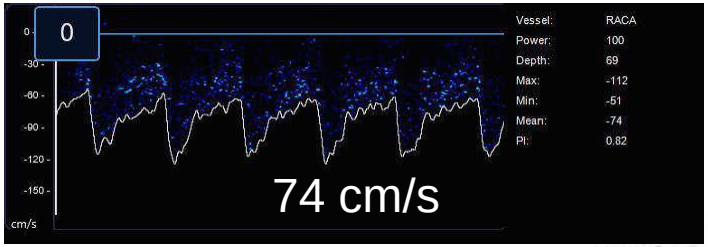
0
74 cm/s
Vessel: RACA
Power: 100
Depth: 69
Max: -112
Min: -51
Mean: -74
PI: 0.82
cm/s

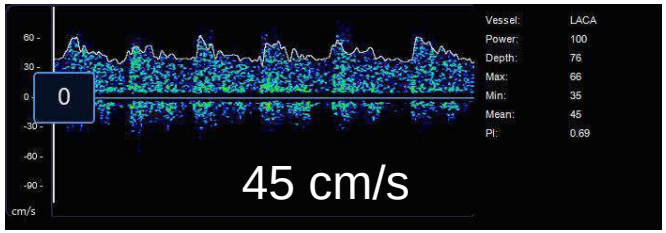
0
45 cm/s
Vessel: LACA
Power: 100
Depth: 76
Max: 66
Min: 35
Mean: 45
PI: 0.69
cm/s

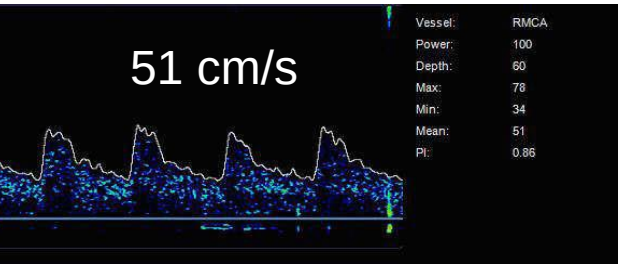
51 cm/s
Vessel: RMCA
Power: 100
Depth: 60
Max: 78
Min: 34
Mean: 51
PI: 0.86

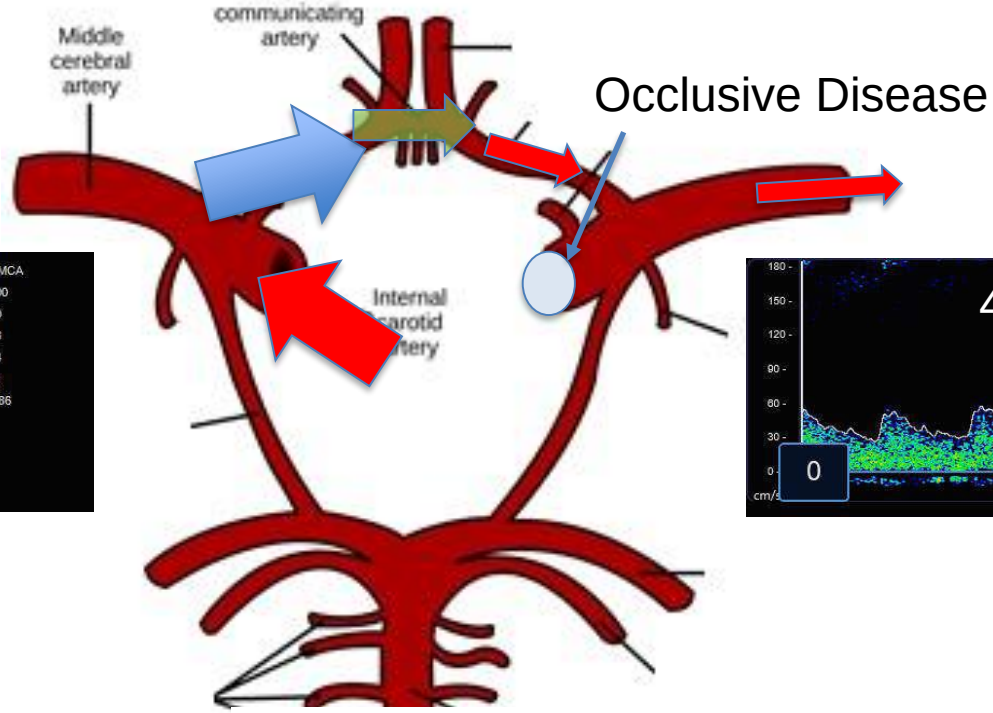
Middle cerebral artery
communicating artery
Occlusive Disease
Internal carotid artery

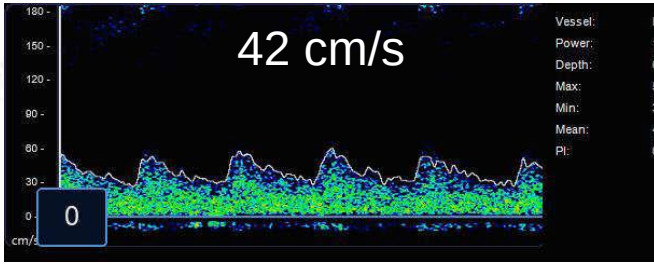
42 cm/s
0
Vessel:
Power:
Depth:
Max:
Min:
Mean:
PI:

Intra-aortic balloon pump (IABP)

- IABPs are balloon catheters that are inserted within the aorta and inflate when the heart relaxes with the intention of pushing more flow towards the coronary arteries.

- Creates an unique Doppler signal
  - Doppler signals change with different settings (delay/pump)
  - Ideally, flow should always be moving unidirectionally

IABP Waveform

HOUSTON Methodist DEBAKEY HEART & VASCULAR CENTER

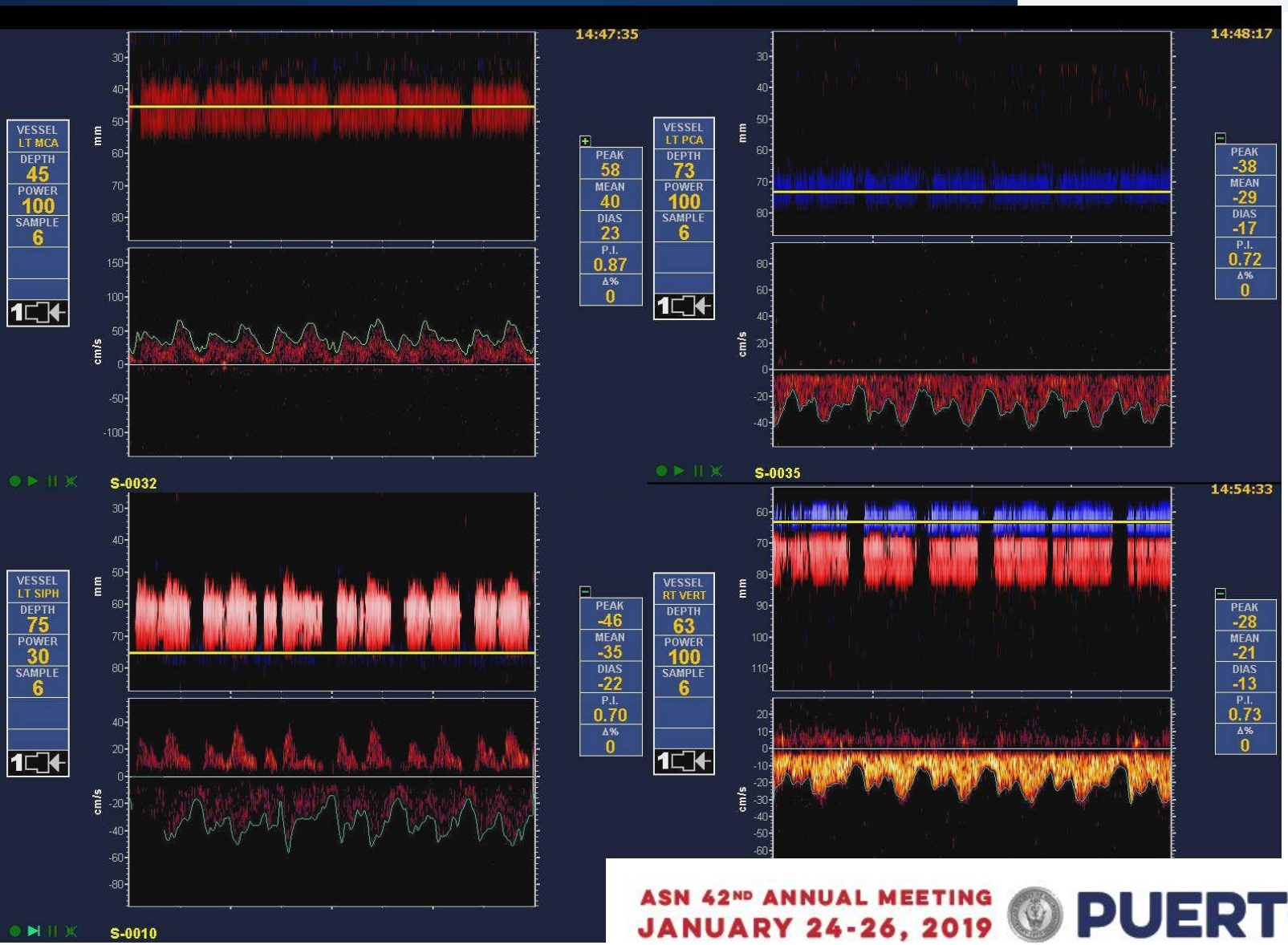

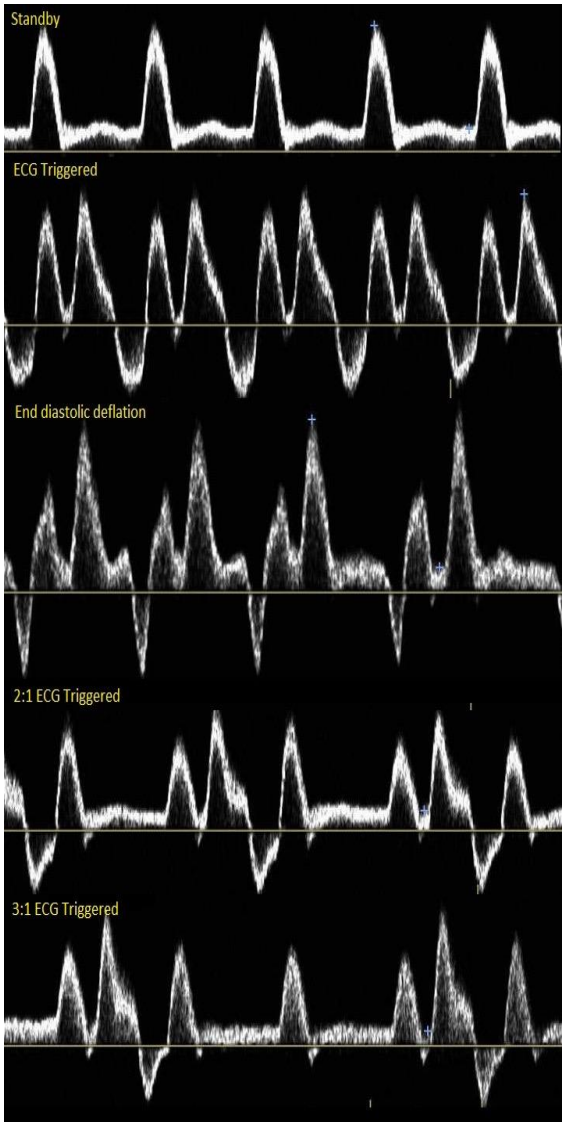

IABP

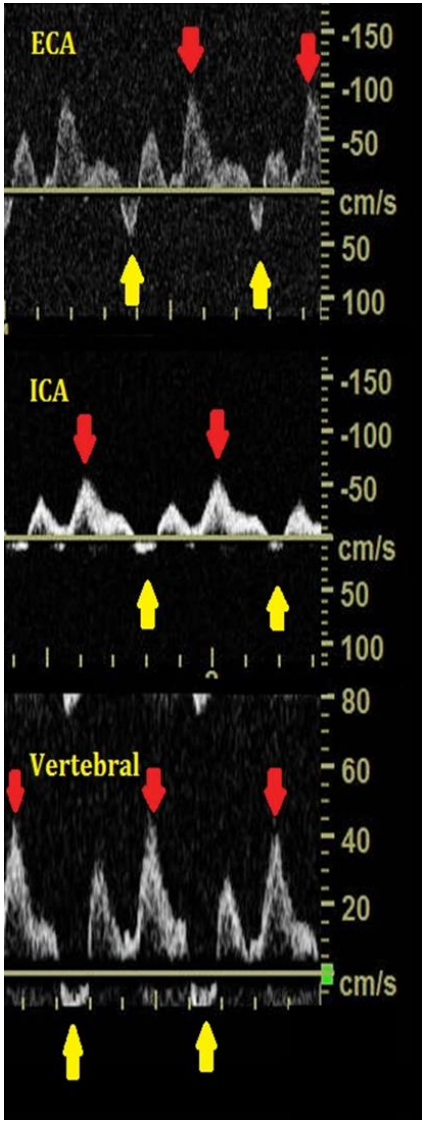

Deflation Timing Influences Intra-Aortic Balloon Pump-Mediated Carotid Blood Flow Reversal:
A Case Report.
Schutt RC, Bhimiraj A, Estep JD, Guha A, Trachtenberg BH, Garami Z. Circ Heart Fail. 2016 Sep;9(9).

Chronic Hypertension

HOUSTON Methodist DEBAKEY HEART & VASCULAR CENTER

- Results in higher resistance/pulsatility index

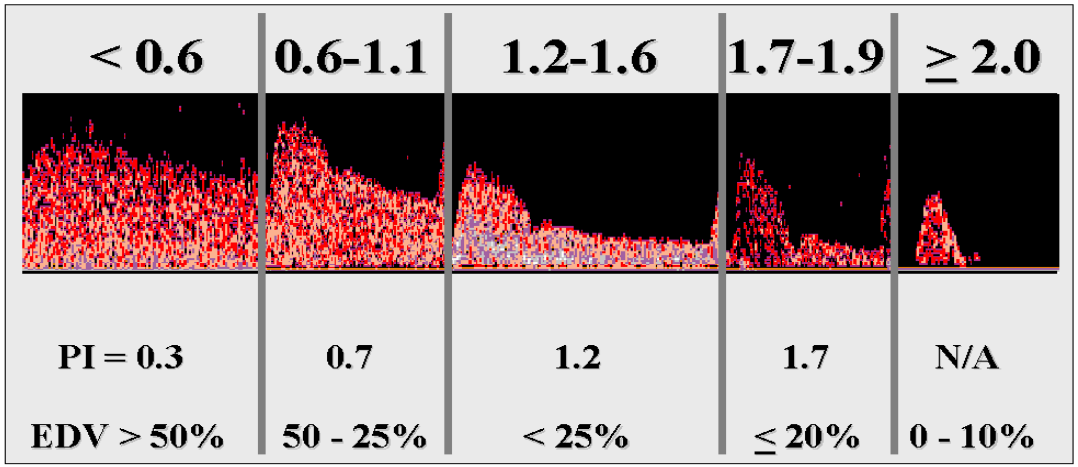

Chronic Hypertension

HOUSTON Methodist DEBAKEY HEART & VASCULAR CENTER

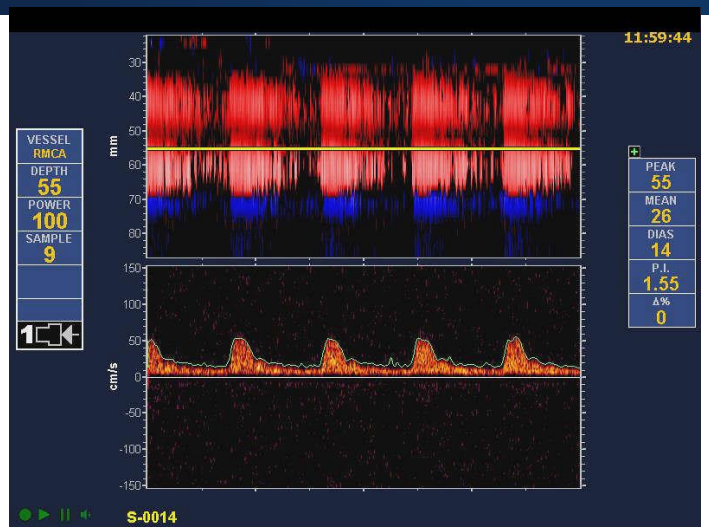

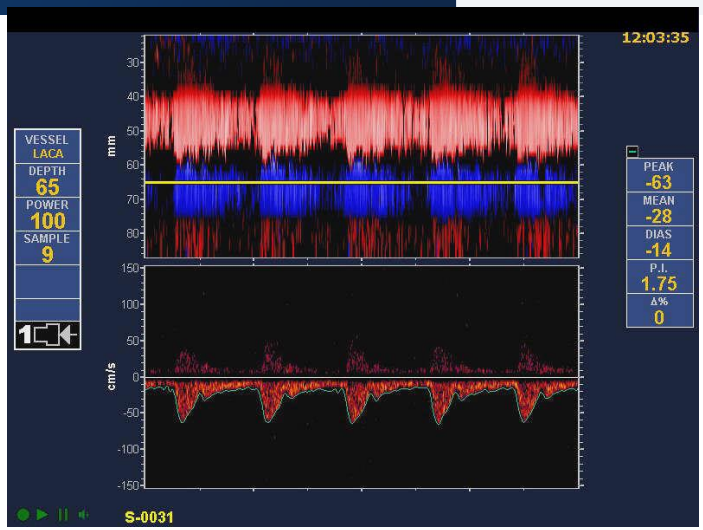

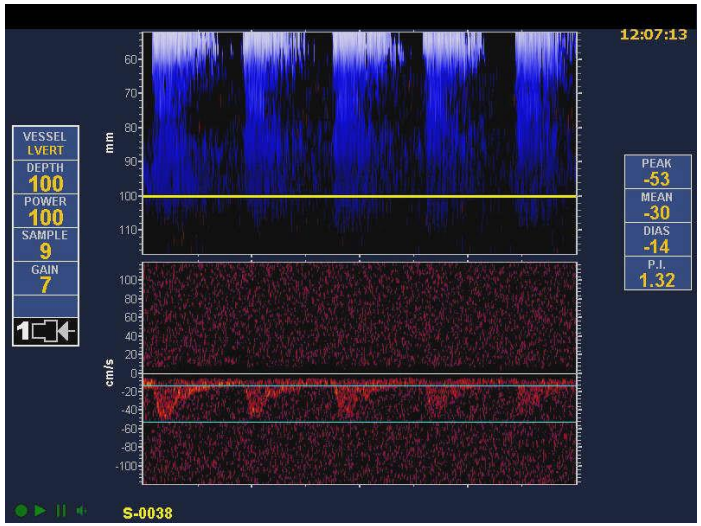

Embolic Activity

- Demonstrated by a signal that presents as a slash on Power M-mode.
- Bright echo in the Doppler signal cannot cross the baseline and must move a certain velocity.
- Creates an audible chirp.

EMBOLUS TRACK ON POWER M MODE DOPPLER

Methodist DeBakey Heart & Vascular Center

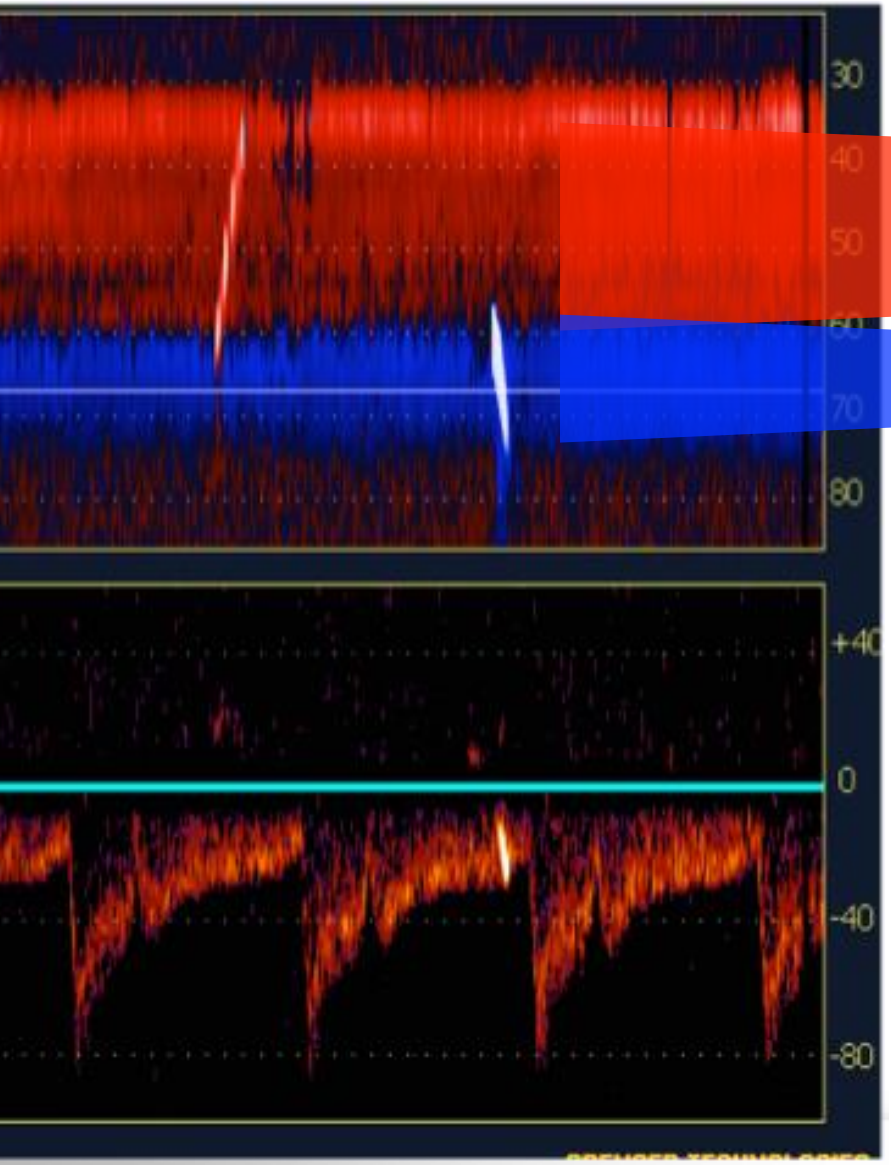

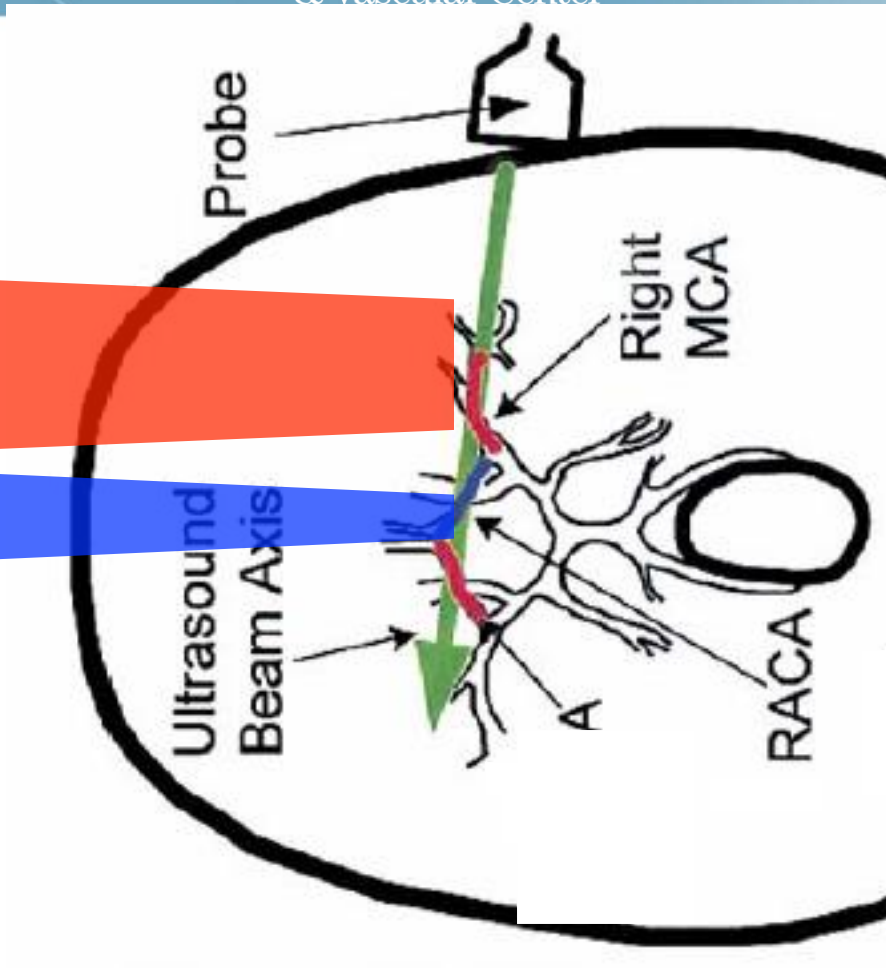

Title Text

HOUSTON Methodist DEBAKEY HEART & VASCULAR CENTER

Methodist DeBakey Heart & Vascular Center

Left Ventricular Assist Device (LVAD)

- Patients with DeBakey LVADs have pulseless arterial flow
- High-intensity transient signals (HITS) are commonly seen, but deficits are rare.

LVAD

HOUSTON Methodist DEBAKEY HEART & VASCULAR CENTER

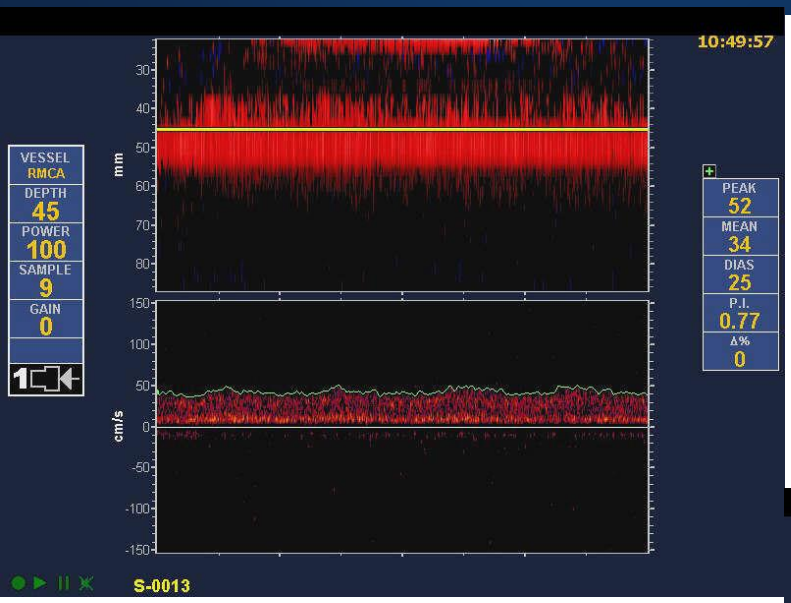

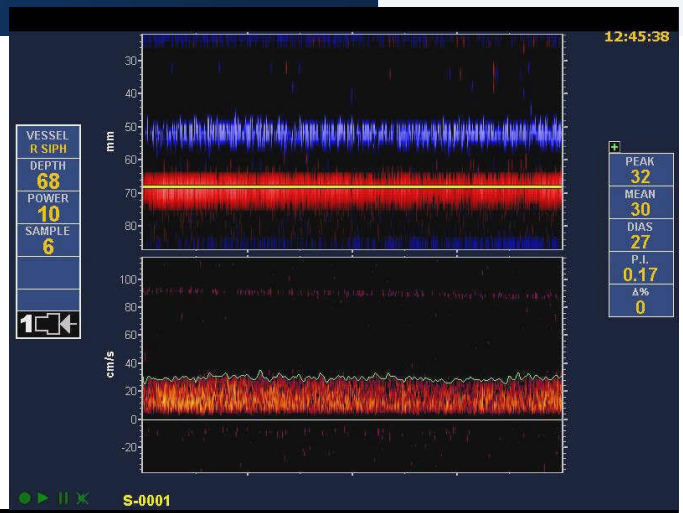

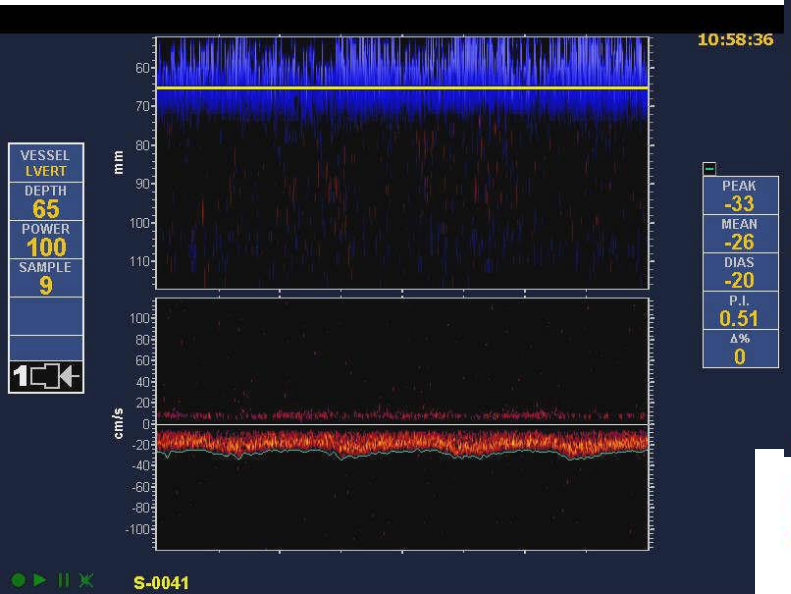

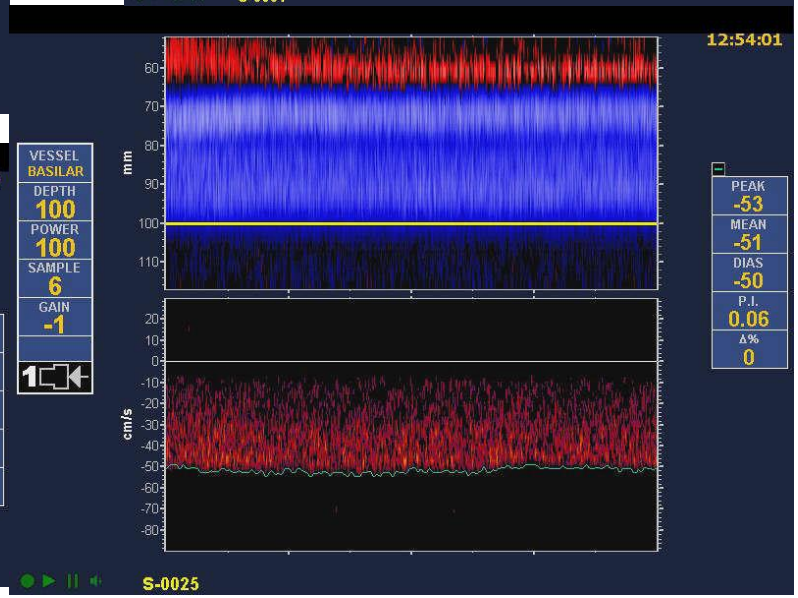

LVAD

HOUSTON Methodist DEBAKEY HEART & VASCULAR CENTER

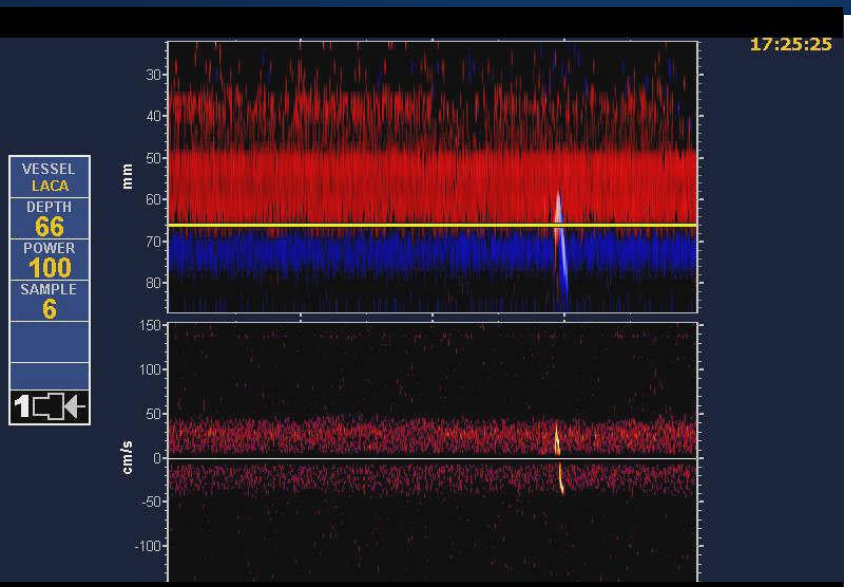

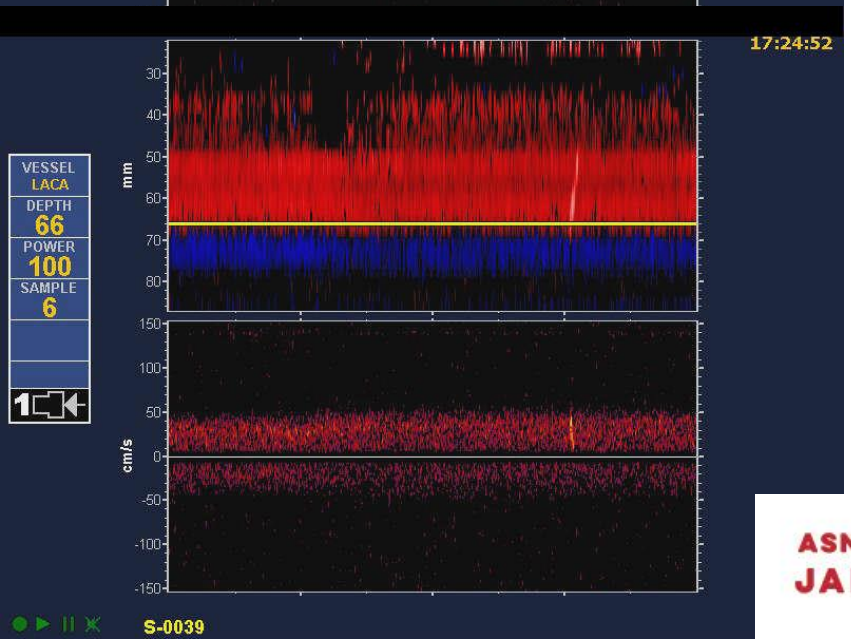

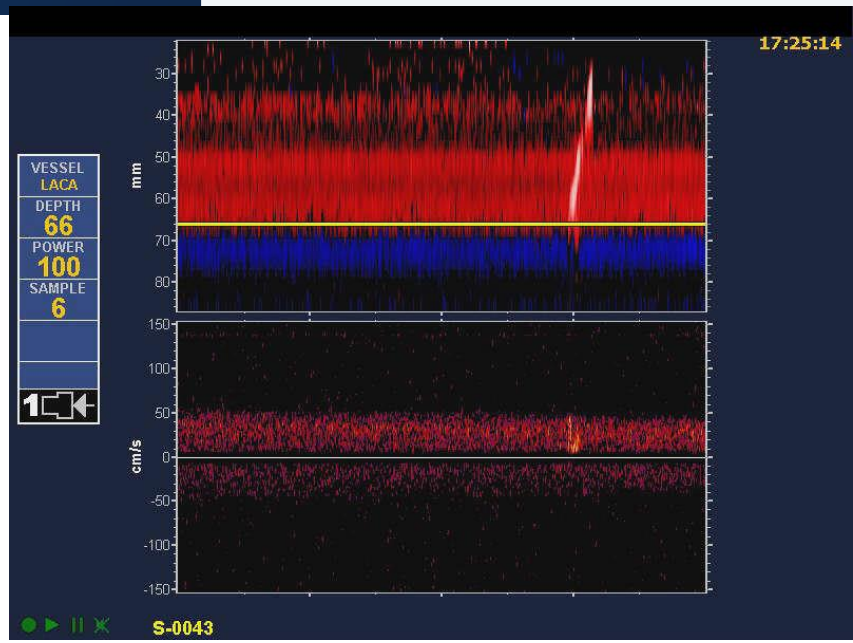

Stenosis

- Sudden increase in velocities
- Distal segments demonstrate blunted signals and turbulence
- Possible aliasing
- Audible bruit
- Double waveform phenomenon

Stenosis

HOUSTON Methodist DEBAKEY HEART & VASCULAR CENTER

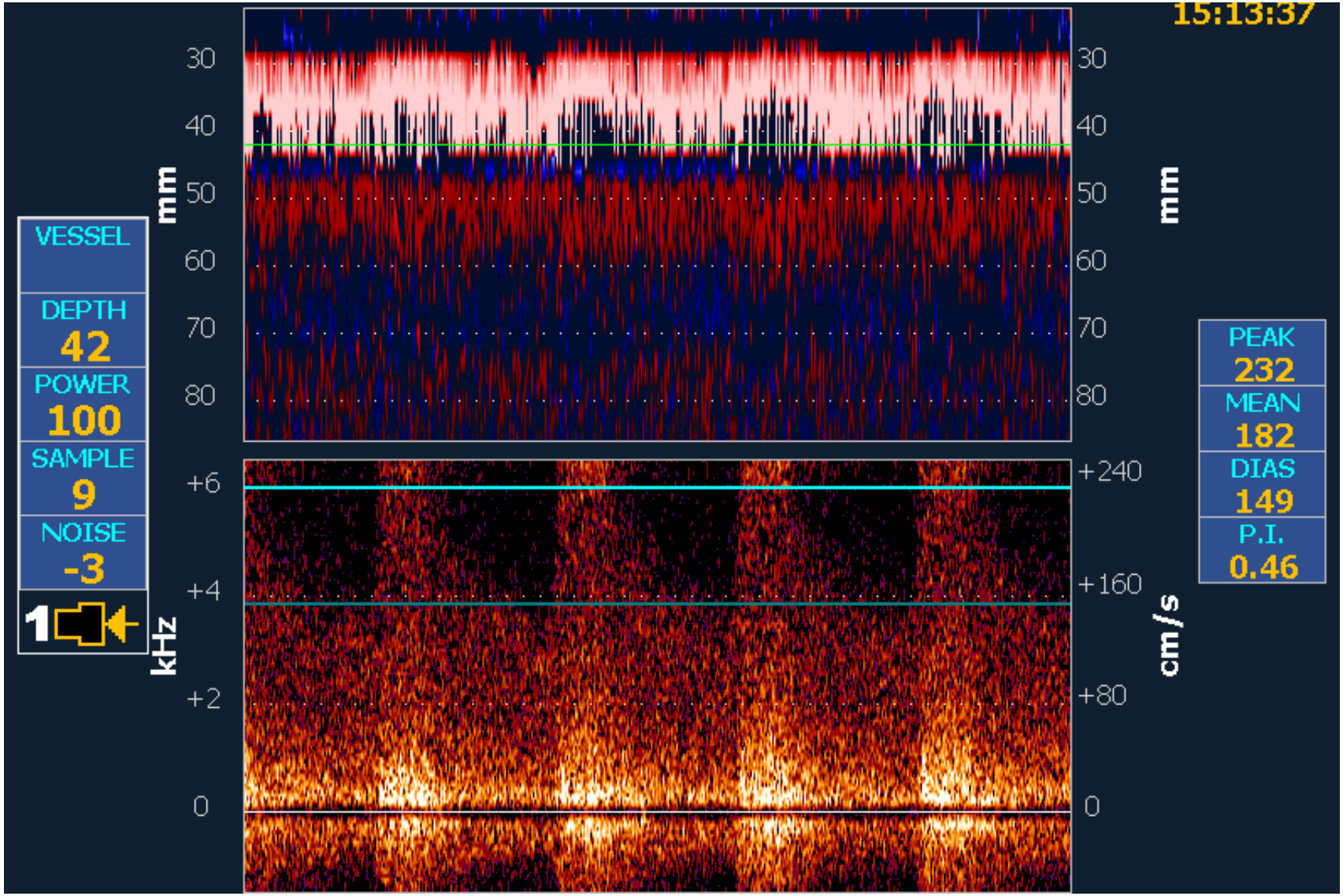

Circulatory Arrest

- Bidirectional flow
- Extremely high resistant indicative of possible increased CSF
- Arterial thump
- TCD very sensitive in confirming.
- Requires a MAP of 80 mmHg

Circulatory Arrest

HOUSTON Methodist DEBAKEY HEART & VASCULAR CENTER

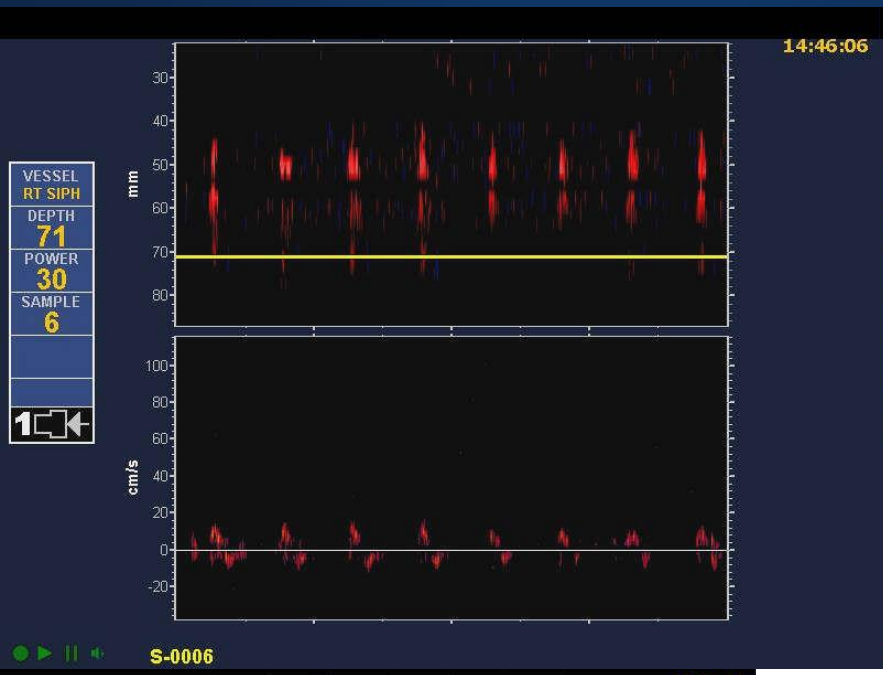

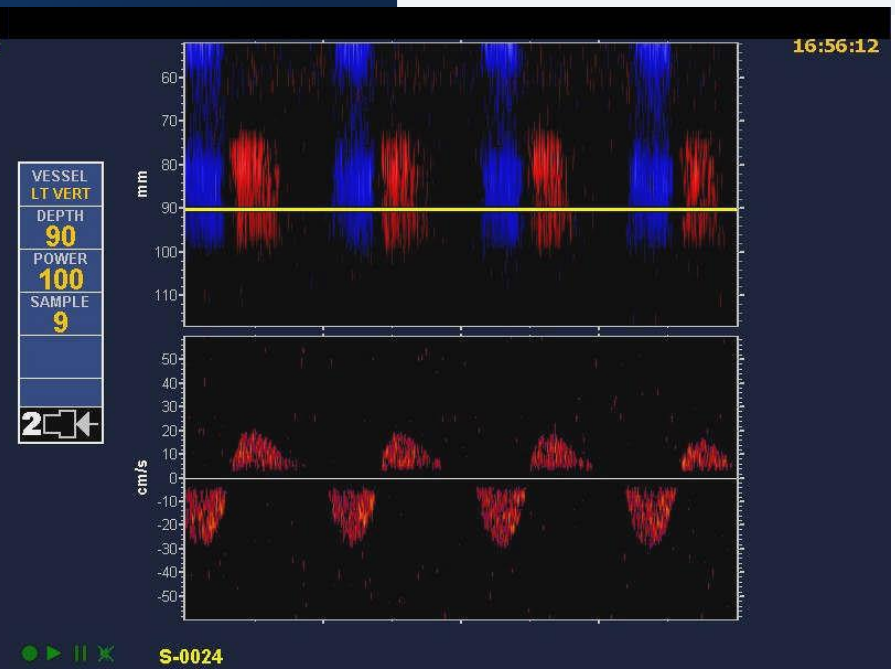

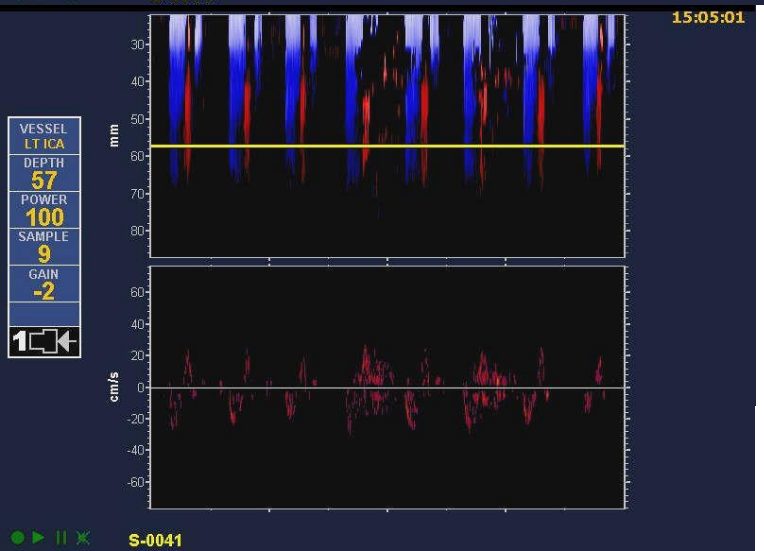

Transcranial Colorflow Doppler

- Possible to perform TCDs using a duplex machine and using proper frequency settings.
- Can angle correct the ultrasound beam
- Allows you to appreciate the COW as a whole, rather than in linear segments.

TCCD

HOUSTON Methodist DEBAKEY HEART & VASCULAR CENTER

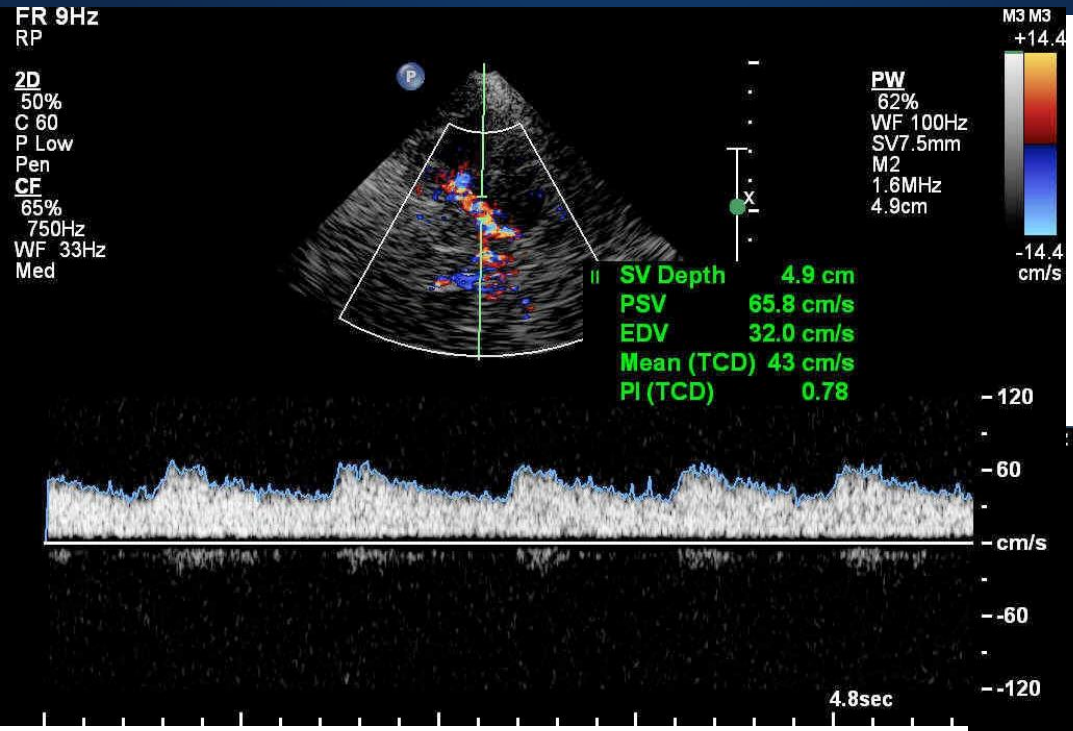

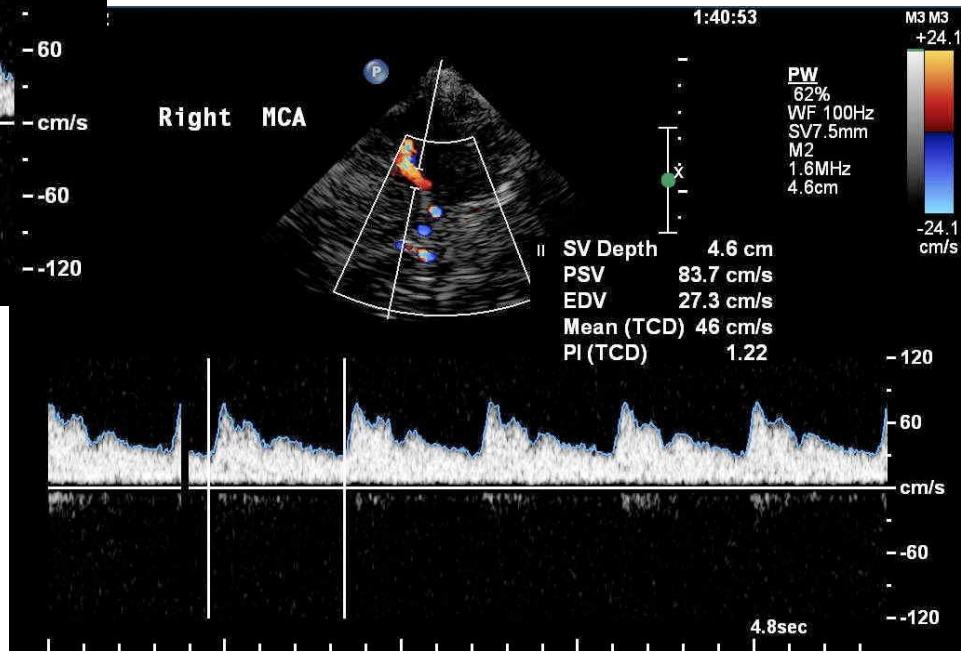

Transcranial Colorflow Doppler

HOUSTON Methodist DEBAKEY HEART & VASCULAR CENTER

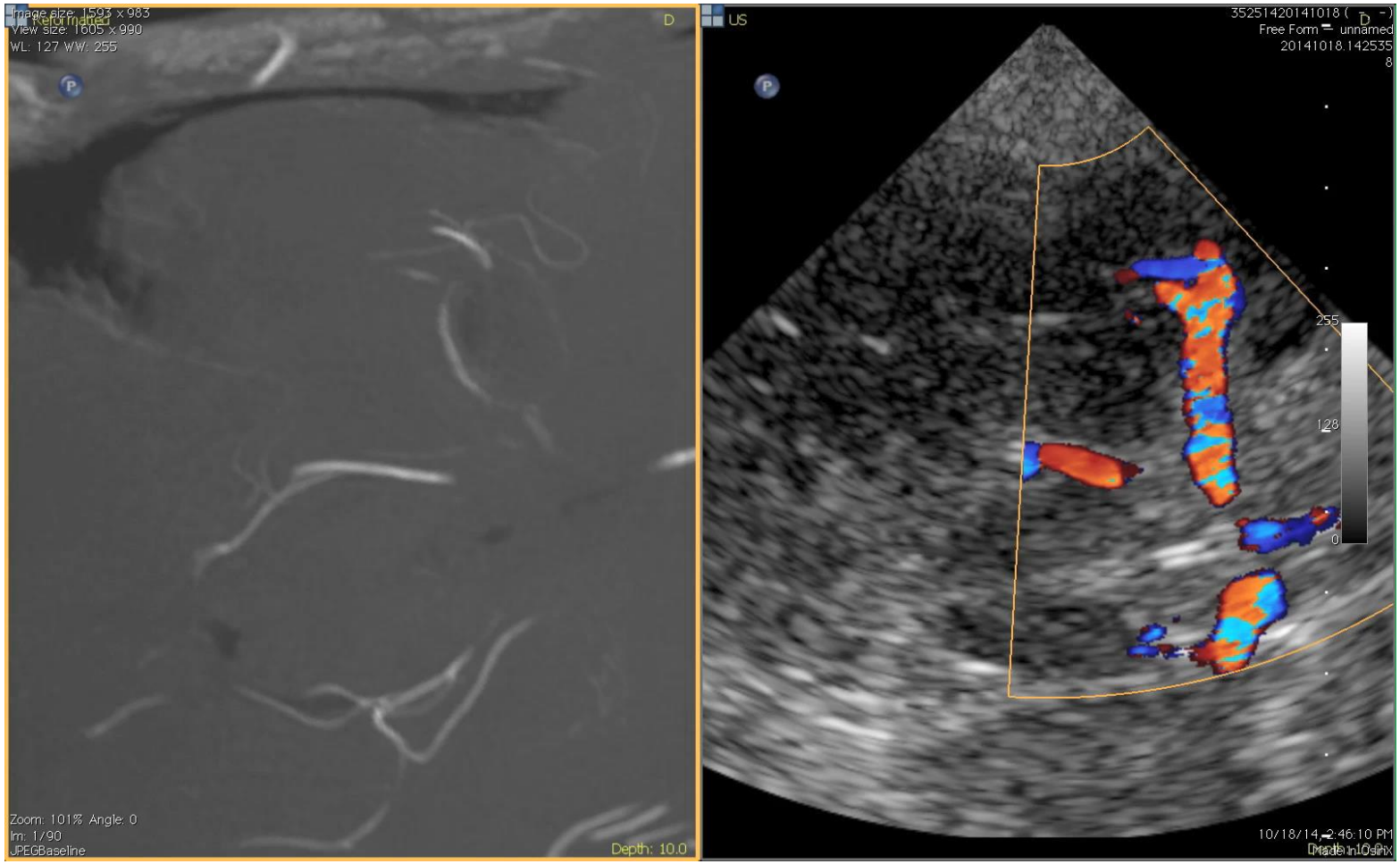

Conclusion

Final Thoughts, Tips

HOUSTON Methodist DEBAKEY HEART & VASCULAR CENTER

- Imagine a microscope: coarse tuning → fine tuning

- Scanning TIPS:
  - Scan in a controlled manner
  - Cover surface area efficiently
  - Be able to backtrack and recover strong signals
  - Avoid making compound movements (angling and changing window location simultaneously)
  - Look at your hand/window often on successful insonation
  - Demographics vs. optimal temporal windows

Conclusion

Final Thoughts, Tips

- Vessel Identity:
  - Depth, Direction, Mean Velocities

- Interpretation depends on quality of the study performed
  - Pay attention to changes to Doppler waveforms:
    - Pulsatility index that is outside normal range.
    - Blunting of signals/delayed upstroke or acceleration time.
    - Aliasing and bruits.

References

HOUSTON Methodist DEBAKEY HEART & VASCULAR CENTER

- REEDER, G., CURRIE, P., HAGLER, D., TAJIK, A., & SEWARD, J. (2019). Use of Doppler Techniques (Continuous-Wave, Pulsed-Wave, and Color Flow Imaging) in the Noninvasive Hemodynamic Assessment of Congenital Heart Disease. Retrieved from https://www.mayoclinicproceedings.org/article/S0025-6196(12)62774-8/fulltext#cesec20

- Cannon, J. (2019). About Transcranial Doppler (TCD) | The Neurovascular Laboratory. Retrieved from https://www.hopkinsmedicine.org/neurology_neurosurgery/centers_clinics/neurovascular_laboratory/transcranial_doppler.html

- Purkayastha, S., & Sorond, F. (2013). Transcranial Doppler ultrasound: technique and application. *Seminars in neurology*, *32*(4), 411-20.

- https://neuralanalytics.com/

- Atysmedical. *Vidéo Doppler*. (2008). [Online Video Clip]. Retrieved from https://www.youtube.com/watch?v=nTjgYv15MJc. Web. Accessed Jan 17, 2019

- Bathala, L., Mehndiratta, M. M., & Sharma, V. K. (2013). Transcranial doppler: Technique and common findings (Part 1). *Annals of Indian Academy of Neurology*, *16*(2), 174-9.

- Thoennissen NH, e. (2019). High level of cerebral microembolization in patients supported with the DeBakey left ventricular assist device. - PubMed - NCBI. Retrieved from https://www.ncbi.nlm.nih.gov/pubmed/16214534

- Deflation Timing Influences Intra-Aortic Balloon Pump-Mediated Carotid Blood Flow Reversal: A Case Report. Schutt RC, Bhimiraj A, Estep JD, Guha A, Trachtenberg BH, Garami Z. Circ Heart Fail. 2016 Sep;9(9).

40th year (2016)

HOUSTON Methodist DEBAKEY HEART & VASCULAR CENTER

HOUSTON
Methodist[SM]
DEBAKEY HEART &
VASCULAR CENTER

ASN 42ND ANNUAL MEETING
JANUARY 24-26, 2019

PUERTO RICO


NEURAL ANALYTICS
ROPTH - 50
17
0.93
29
13
50
0
DEE DEE
DICET
DEBAKEY INSTITUTE FOR
CARDIOVASCULAR EDUCATION & TRAINING
HOUSTON
Methodist
DEBAKEY HEART &
VASCULAR CENTER